

Case Report

Maxillofacial Gunshot Injury in Experience of Iraqi War Against Terrorism

Ahmed Maki Merza*, Haydar M. Salih

Department of Maxillofacial, Alkarkh General Hospital Baghdad, Iraqz

***Corresponding author:** Ahmed Maki Merza, Department of Maxillofacial, Alkarkh General Hospital, House no. 24/ side street 9/ area 667/ Al-karkh, Baghdad, Iraq. Tel: +964-790-1731409/+964-770-4087609; E-Mail: makimaxfax@gmail.com/dr.maki.a@gmail.com.

Citation: Merza AM and Salih HM (2017) Maxillofacial Gunshot Injury in Experience of Iraqi War Against Terrorism. J Surg 2017. JSUR-132.

Received Date: 10 April 2017; **Accepted Date:** 18 April, 2017; **Published Date:** 25 April, 2017

Abstract

War injuries are the cornerstone of maxillofacial surgery, and it led to the initiation and development of this specialty, and each case represents a challenge to the surgeon who deals with it. In this article, we present a 39 year old male patient who was referred to our emergency department complaining of penetrating gunshot wound. Preoperative imaging showed a bullet with a very long path lodged in the posterior part of the maxilla. According to our experience there are different approaches for bullet extraction in this site, for each one there are specific indications, so in this case report we share the most suitable approach according to our experience.

Keywords: Gunshot Wounds; Missile Injuries; Bullet Removal

Introduction

In 2014, Iraq has witnessed a serious setback represented by the control of a terrorist organization on large parts of the country, this effect was most important in the diversity on the war injuries broadly and specially on the missile injuries. Gunshot wounds may be classified as penetrating, perforating, or avulsive. In penetrating injuries, the projectile remains lodged in the injured tissue. Low-velocity gunshot wounds are generally penetrating. In perforating injuries, which are characteristic of high-velocity projectiles, there is an entrance wound and an exit wound. Avulsive gunshot wounds are those involving loss of tissue, and are usually caused by high-velocity or ultrahigh-velocity projectiles [1,2]. Generally, low-velocity injuries are from projectiles travelling at less than 1200 feet/s. High-velocity missiles are those travelling at greater than 1200 feet/s [3]. The pattern of trauma in gunshot wounds is extremely variable [4]. The severity of these injuries varies according to the weapon gauge and its distance to the target [5]. Based on the range the gunshot injuries are classified into three types. Type 1 (long range, over 7 yards) penetrates subcutaneous tissue and fascia, type 2 (3-7 yards) penetrates abdominal cavities, type 3 (blast injuries, less than 3 yards) [6]. According to the speed,

projectile shape, and injured anatomic region of the head and neck, these wounds will be more or less destructive, depending on the dissipated energy. In cases of high-energy dissipation, the impact will create a temporary tissue cavity reaching 11 times the projectile size, and this "shock wave" will damage distant vessels and nerves [7]. The management of facial gunshot wounds has led to much advancement in the knowledge and development of oral and maxillofacial surgery techniques, and remains the object of extensive discussion [8]. The immediate management of facial gunshot wound must be focused on securing the airway and control bleeding. The phase I surgical treatment consists of primary closure of soft tissue wounds of the face and primary stabilization of the jaw bones. The phase II surgical treatment consists of secondarily reconstruction of the face using bone grafting and soft tissue revision procedures [9]. Infection control is extremely important in the success of the treatment [10]. This report seeks to present our approach in this type of missile injuries.

Case report

A 39-year-old male (military) reported to the Oral and Maxillofacial surgery department unit with a gunshot injury and complaints of a dull aching pain on the right side of his face, nasal congestion and multiple episodes of nasal bleeding. The patient

was conscious, alert, co-operative and well oriented. Examination revealed a 1-cm-wide entry wound on the right side of the face approximately 2cm inferior to the right eye. There was no evidence of an exit wound. The patients' vital signs were all within normal limits. There were no signs of active bleeding or pus discharge from the entry wound. Intraorally, there was no swelling, signs of laceration or ecchymosis. A plain radiograph (Figure 1),

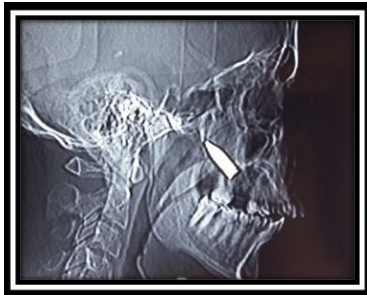

Figure 1: Plain radiograph showing the bullet lodged in the maxilla.

revealed a bullet lodged in the posterior wall of the right side maxillary bone, computerized tomographic scan showed that part of the bullet is settled in the right side maxillary sinus and pterygoid plates of the sphenoid bone fracture (Figure 2).

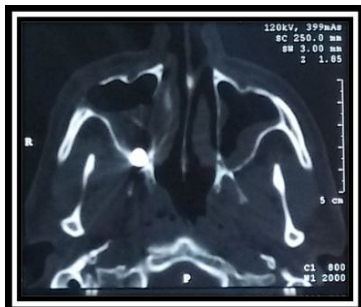

Figure 2: Computerized tomography (axial view) showing bullet position.

The path of the missile was extending from the infraorbital region by fracturing the anterior wall of the zygomaticomaxillary complex, so the missile lost its energy and settled in the maxilla with the nozzle facing the posterior wall of the maxillary sinus (Figure 3).

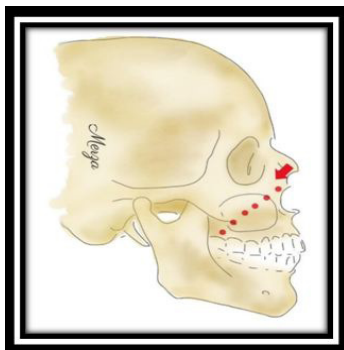


Figure 3: Bullet pat

The patient transferred to the operation theater, and under general anesthesia a local anesthetic containing a vasoconstrictor is given 10 minutes before the surgery, then right side buccal sulcus mucosal incision is done extending from the buttress area to the midline, muscle dissection and reflection then a subperiosteal dissection extending from the zygomatic buttress to the pyriform aperture and extending superiorly till the inferior orbital foramen taking into our consideration the buccal fat pat position during the dissection to avoid its herniation and the inferior orbital nerve localization to avoid any neural injury with dissection or retraction, after the exposing the whole anterior wall of the maxilla, a bony window in the wall of the maxillary sinus was made and the site explored, a bleeding haemostasis achieved successfully and then irrigation with bullet localization blindly through a Kelly clamp, then the bullet removed from the maxilla through the same exploration site (Figure 4,5),

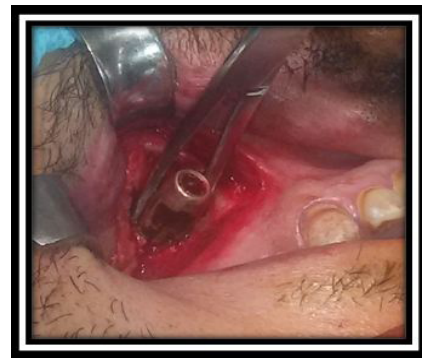

Figure 4: Bullet removal.

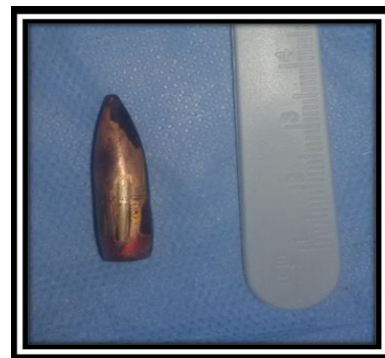

Figure 5: Bullet size.

antrostomy then done and the wound closed, Patient postoperative condition was very good.

Discussion

Management of patients with oral and maxillofacial injuries is a challenge, surgical access and scar positions in the head and neck should be considered when treating these cases [11]. The removal of foreign bodies in penetrating type of missile injuries is usually recommended because they can move to a deeper position,

and their presence may result in unexpected complications, especially when the foreign body is located in dangerous area [12].

This case shows a penetrating Gunshot injuries with a bullet (projectile) lodged in the posterior wall of the right side maxillary bone with pterygoid plates of sphenoid bone fracture, the path of the missile was extending from the infra-orbital region and settled in the maxilla. The site of entry and the estimated trajectory of the projectile allow a general impression of the structures disrupted and may predict, with a certain safety margin, possible life-threatening complications, although the unpredictable path of bullets due to the ricocheting effect of bone surface [13]. There are 3 approaches here for bullet removal either with Le Fort I maxillary osteotomy then down fracture the maxilla or through the maxillary sinus directly or by endoscope, we choose to start with the maxillary sinus approach directly cause it's the easiest and simplest approach to that location and to be able to arrest any bleeding that may occur during bullet removal due to pterygoid plates fracture, so we didn't use the Le Fort I approach. And we didn't choose the endoscopic one due to the bullet size which will make its removal through this approach very difficult. Our approach was easy and successful without major complication. Here the antrostomy should be done after bullet removal to avoid sinusitis complication post-operatively.

Conclusion

The three approaches here for bullet removal from this site can be used and that according to the specific indications for each one of them, but it is easier and simpler with lesser complications to start with the maxillary sinus approach first. We recommend early debridement with copious irrigation of the inlet and the accessible path of the bullet.

Reference

1. von See C, Stuehmer A, Gellrich NC, Blum KS, Bormann KH, et al. (2009) Wound ballistics of injuries caused by handguns with different types of projectiles. *Mil Med* 174: 757-761.
2. Mário Sergio Medeiros Pires, MD, Caroline ComisGiongo, DDS, Guilherme de Marco Antonello, DDS, Ricardo Torres do Couto, DDS, Ruy de Oliveira VerasFilho, DDS, et al. (2015) An Interesting Case of Gunshot Injury to the Temporomandibular Joint. *Craniomaxillofac Trauma Reconstr* 8: 79-82.
3. AshutoshVatsyayan, Apurba Kumar Adhyapok, Subhas Chandra Deb-nath, Kapil Malik (2016) Reconstruction and rehabilitation of short-range gunshot injury to lower part of face: A systematic approach of three cases. *Chin J Traumatol* 19: 239-243.
4. He D, Zhang Y, Ellis E III (2007) Panfacial fractures: analysis of 33 cases treated late. *J Oral MaxillofacSurg* 65: 2459-2465.
5. Yuri Slusarenko da Silva, Marcia Maria de Gouveia, Carlos Augusto Ferreira Alves, and Rodrigo ChenuMigliolo (2015) Late treatment of a mandibular gunshot wound. *Autops Case Rep* 5: 53-59.
6. K. V. Arunkumar, Sanjeev Kumar, Rajat Aggarwal, Prajesh Dubey (2012) Management challenges in a short-range low-velocity gunshot injury. *Ann MaxillofacSurg* 2: 200-203.
7. Powers DB and Delo RI (2013) Characteristics of ballistic and blast injuries. *Atlas Oral MaxillofacSurgClin North Am* 21:15-24.
8. Peterson L J, Ellis E E, Hupp J R, Tucker M R (2000) Contemporary oral and maxillofacial surgery 3rd ed. Saint Louis: Mosby 2000.
9. M. peled (2005) The treatment of gunshot injuries to the face. *International journal of oral and maxillofacial surgery* 34: 76.
10. B. Kambarji (2013) Management guidelines of facial gunshot injuries. *International journal of oral and maxillofacial surgery* 42: 1226.
11. A. Zaggut (2017) Management of oral and maxillofacial war injuries during Libyan Conflict 2011: lessons learned by an oral surgeon. *International Journal of Oral and Maxillofacial Surgery* 46: 92.
12. A M Merza (2016) Bullet removal from the infratemporal fossa. *Ann Maxillofac Surg. Case Rep* 6: 292-296.
13. P.K. Stefanopoulos, O.T. Soupiou, V.C. Pazarakiotis, K. Filippakis (2014) Wound ballistics of firearm-related injuries-Part 2: Mechanisms of skeletal injury and characteristics of maxillofacial ballistic trauma. *International Journal of Oral and Maxillofacial Surgery* 44: p67-78.