

Research Article

Selective Endoscopic Lumbar Discectomy (SED™) and Thermal Annuloplasty for Discogenic Back Pain, Disc Herniations and Sciatica in High Performance Athletes and Physically Active Patients

Anthony T. Yeung^{1,2*}, Christopher A. Yeung²

¹University of New Mexico, School of Medicine Albuquerque, New Mexico, USA

²Desert Institute for Spine Care Phoenix, Arizona, USA

*Corresponding author: Anthony T. Yeung, Voluntary Professor of Neurosurgery, University of New Mexico, School of Medicine Albuquerque, New Mexico, Tel: + 602-944-2900; E-mail: ayeung@sciatica.com

Citation: Anthony TY, Christopher AY, (2017) Selective Endoscopic Lumbar Discectomy (SED™) and Thermal Annuloplasty for Discogenic Back Pain, Disc Herniations and Sciatica in High Performance Athletes and Physically Active Patients. Sports Injr Med JSIMD 2017:110.

Received Date: 30 March, 2017; **Accepted Date:** 28 April, 2017; **Published Date:** 6 May, 2017

Abstract

Introduction: 25 years experience in transforaminal endoscopic surgery from a personal and spine group database is reviewed relating to treatment of discogenic pain and disc herniations.

Method: An ongoing IRB study approved in 1997 resulted in a continued study using a transforaminal endoscopic procedure with an endoscope designed for intradiscal transforaminal decompression of painful traumatic and degenerative conditions of the lumbar spine. The system developed was named the Yeung Endoscopic Spine System (YESS™) by Richard Wolf Surgical Instrument Company Vernon Hills, Illinois. The technique accompanying the system has evolved over 25 years as indications were stratified over multiple studies published in peer reviewed journals that resulted in the indications promoted and validated known as the YESS™ technique. Results of the treatment of discogenic pain and disc protrusions are provided in this summary. The vast majority of the data was generated by one surgeon (ATY) but since 2001, the co-author (CAY) and 2 other spine surgeons of the spine group practice contributed to the maintained database.

Results: A summary of the stratified results are listed in the text of the article. Indications and results provide validation of the conclusion that SED™ is the least invasive technique for surgical treatment of disc herniations, especially if treated early in the disease process.

Conclusion: With evolving techniques that continue to advance, such as diagnostic and therapeutic injections using the same trajectories to target the patho-anatomy of the pain generator, indications can be further stratified for patient selection to the extent that 90% prediction of transforaminal surgical decompression results using the “YESS” technique can be “warranted” to improve the painful condition once the learning curve is reached and stabilized for each individual surgeon. Each surgeon stratifies their patient selection by depending on their individual patient selection criteria.

Introduction

Percutaneous transforaminal discectomy and thermal annuloplasty has a very successful track record, especially in the early treatment of discogenic pain from disc protrusions and herniations. Non-operative therapeutic regimens are the accepted non-surgical options first as “conservative” treatment in the face of pain with-

out radiculopathy. Non-surgical treatment, however, often fail to achieve effective relief in common and chronic discogenic back pain that rely on natural healing processes to mitigate pain. Current accepted surgical options range from translaminar discectomy to lumbar fusion when non-surgical options fail. Discectomy is a surgical treatment procedure that is accepted and validated by the SPORT Study. When discogenic pain progresses to disc herniation

caused by failure of the annulus fibrosis to contain the nucleus, radiculopathy may occur. Minimally Invasive surgical treatment options developed for small and symptomatic disc herniations, notably disc decompression performed transforaminally through Kambin's triangle serves a basis for this focused paper based on 25 years and over 10,000 procedures by Endoscopic spine surgeon Anthony Yeung. Posterolateral Selective Endoscopic Discectomy™ (SED) and radiofrequency (RF) thermal annuloplasty is a trademarked percutaneous endoscopic technique developed by Yeung, also known generically as PELD and PED in the literature. The endoscope design by Yeung is configured to access both the intradiscal and foraminal space. (Figure 1)

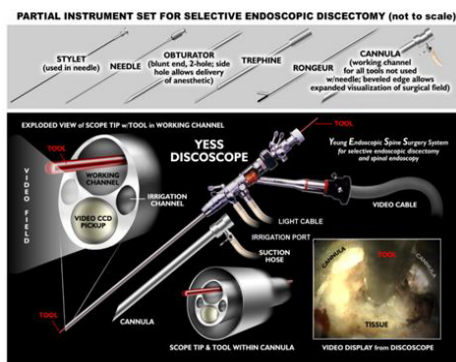


Figure 1: The Richard Wolf YESS™ endoscope facilitates endoscopic documentation of patho anatomy. The uniqueness of the YESS™ scope is the oval shaped endoscope of 4.5 mm diameter. The oval shape inside a round cannula allows the endoscope to enter narrow discs to inspect the disc cavity for the performance of visualized intradiscal therapy. A 2.8 mm working channel with integrated distal irrigation ports keeps the lens clear of blood that may otherwise obscure intradiscal and epidural visualization. The size and design of the endoscope was designed to accommodate the largest working channel that will accommodate the smallest micro-instruments at time. To accommodate various approaches to the spine, different size endoscopes with larger working channels and instruments offered operating ports of 2.2, 2.8, 3.1, and 4.2 mm are used for transforaminal discectomy, foraminoplasty, dorsal rhizotomy, and for translaminar approach to the lumbar spine as well as anterior approach to the cervical spine. Other endoscope designs and instruments have since been introduced by Richard Wolf. Most significant development in instrumentation is the new articulated carbide and diamond burrs, aided by laser debridement in tight spaces. This new technique provides direct visualization of the hidden zone in the axilla between the traversing and exiting nerve where most patho-anatomy of Failed Back Surgery resides.

This most promising surgical intervention for discogenic back pain and disc protrusion progressing to herniation is supported by transforaminal endoscopic discectomy techniques in the literature. SED™ is a visualized intradiscal procedure that incorporates endoscopic discectomy™, evocative chromodiscography™, and thermal annuloplasty using a patented high frequency low temperature bipolar flexible electrode by Elliquence through the transforaminal approach. The current trend in MIS Spine will be surgical procedures with a focus on endoscopically visualized

discectomy and thermal annuloplasty .

Method

Ongoing clinical data resulting from an IRB approved study approved by Saint Luke's Medical on the efficacy of endoscopic surgery after Yeung received 510k FDA approval for his new endoscope design with multi-channel irrigation designed for intradiscal therapy favored by Kambin. After approval by St Luke's Medical Center, Phoenix, Arizona in 1997, data collected from a personal and group database of over 10,000 procedures over 25 years serves to support transforaminal discectomy for a wide spectrum of disc protrusions and herniations causing back pain and sciatica. All surgeries were performed under local anesthesia. Patients initially had a "temperature controlled" flexible probe by Oratec that demonstrated very good clinical results. However, a thermal injury causing foot drop on the 50th patient with co-morbidities of peripheral neuropathy and epilepsy caused a switch to bipolar high frequency RF by Ellman International Their temperature controlled probe was withdrawn by the sponsoring company and a radiofrequency probe was switched to a bipolar probe by Elliquence that produced similar thermal annuloplasty clinical results for discogenic pain. This new bipolar thermal probe, designed with the help of Yeung, experienced no subsequent thermal injuries. Any nerve root irritation (exiting and traversing) in the treatment of discogenic pain and disc herniations, were transient, and likely from the DRG, and thus this transforaminal endoscopic discectomy technique demonstrated a very effective and safe surgical technique. Usual spine and general surgical related complications, such as thrombophlebitis, discitis, hematoma, and transient neuropathy totaled less than 3%. Dural tears, hematoma, and infection also a risk of other spine surgery was temporary and minimal.

The Original Study Design/Setting

The 1997 IRB approved study by St Luke's Medical Center proposed by Yeung for painful degenerative conditions of the lumbar spine determined that surgical decompression and thermal modulation using lasers and radiofrequency can provide back pain relief emanating from the lumbar disc for a variety of disc herniations and discogenic pain confirmed by evocative discography. Patient selection used positive evocative chromo-discography pre-operatively and/or intraoperatively, correlated with an abnormal discogram pattern. At surgery, chromo-discography with diluted indigo carmine dye stained the degenerative nucleus pulposus, targeting the stained degenerative tissue for removal. Tears in the annulus were discovered to have embedded and interposed disc material in the annulus, preventing it from healing. The annulus was then treated by laser and radiofrequency flex probes under endoscopic visualization. Interpositional nucleus material embedded in the annulus needed to be removed, and the location, thickness and extent of intact annular fibers provided prognosis for best results. A wide spectrum of patients with discogenic pain from contained

disc protrusion to extruded disc herniations who had positive discography with concordant discogenic pain were included in the sample size. The original study was sponsored by Oratec, a pain management company to evaluate their temperature controlled RF probe, but a thermal injury causing foot drop on the 50th patient with co-morbidities of peripheral neuropathy and epilepsy caused a switch to bipolar high frequency RF by Ellman International. This probe was later re-introduced by Ellman, renamed Elliquence International, followed by studies to evaluate its safety using different power settings. As the technique evolved, specialized endoscopic surgical instrumentation developed by competing endoscope systems were adopted and utilized, including the routine use of visualized laser ablation as a surgical tool.

Findings

The painful discs had inflammatory or granulation tissue adjacent to the annular tears. The degenerative nucleus pulposus is removed mechanically, with rongeurs, shavers, radiofrequency or laser, ablating the granulation and inflammatory tissue adjacent to the annular tears. The annular defects from disc herniations are endoscopically observed to be physically altered by thermal annuloplasty. Sometimes the tears are closed and sealed, but large tears associated with disc herniated extruded nucleus could not be closed. Thus the physiology of inflammation was correlated with mechanical discectomy and thermal annuloplasty of the annular defect.

Large herniations are known to have a higher incidence of recurrence because the annulus defect is larger and has difficulty healing. Instability may also result following discectomy. Therefore, earlier decompression when the patient is symptomatic and before there is nerve compromised by mechanical radiculopathy and changes in the annulus from progression and the aging process will give better results when decompressed early. Even with the need for additional surgery, the risk of destabilizing the spinal segment is reduced, and the advantages in avoiding denervation of the muscles in high performance athletes make consideration of this less invasive and muscle preserving approach worth consideration. No patient became worse as a result of transforaminal decompression.

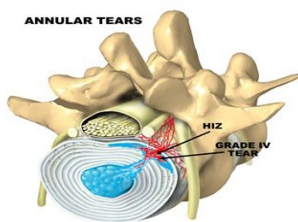


Figure 2: Illustration of a grade IV annular tear. Annular tears can be graded according to Adam’s Classification. It can be visualized intradiscally and treated with tools utilizing bipolar flexitip Radiofrequency, laser, tissue sealants, and biologics that enhance tissue healing.

The diagnosis and treatment of painful annular tears are by evocative discography and transforaminal epiduralgrams. Transforaminal therapeutic injections are performed with a similar or same trajectory as with surgical transforaminal decompression. It is not performed with the traditional “down the tunnel” technique utilized by interventional pain management physicians.

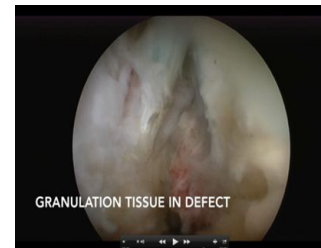

Figure 3: Endoscopic views of an annular tear with a 75 degree endoscope. Thermal Annuloplasty is performed intradiscally, either under endoscopic visualization or with the Disc Fx system if an endoscopic system is not available. Disc FX was developed as a fluoroscopically guided procedure, based on the endoscopic findings documented by SED™ if an endoscope is not available.

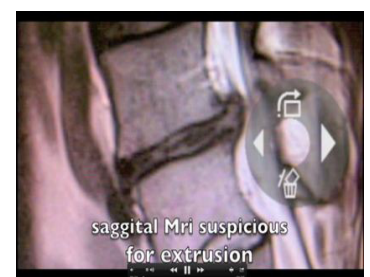
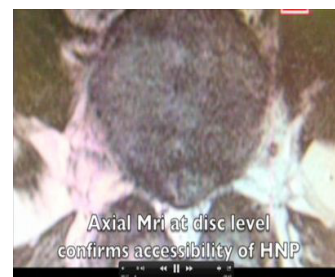
Figure 4a,b: Axial and saggital Mri of a Central HNP

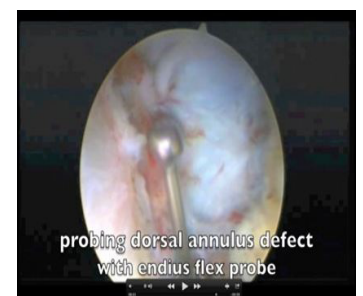
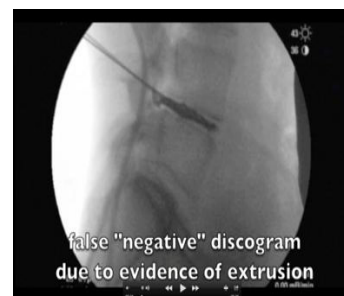
Figure 4c: intra-operative evocative discography

Figure 4d: Ball probe ventral annulus 70 degree scope

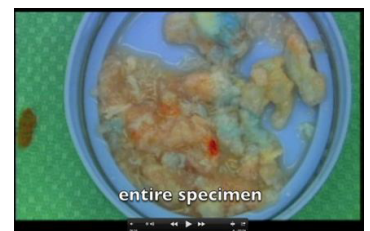
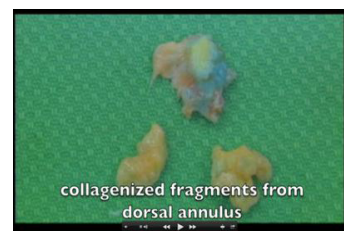
Figure 4e: Fragments extracted from ventral annulus

Figure 4f: Selective intradiscal discectomy entire specimen

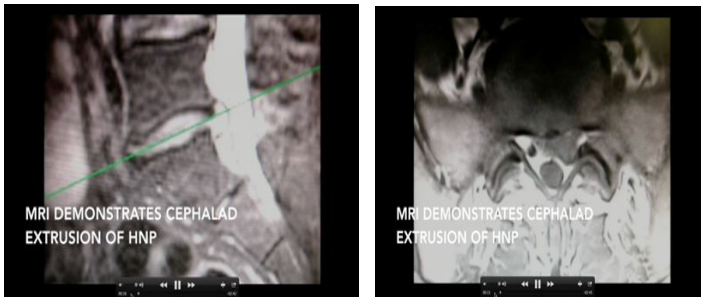


Figure 5: a, b Mri of extruded non-contained HNP

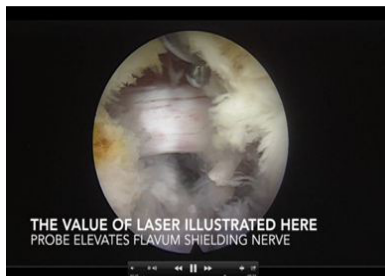

Figure 5c: Endoscopic confirmation of decompressed nerve medial capsule ablated with 550 ho: yag laser to visualize nerve

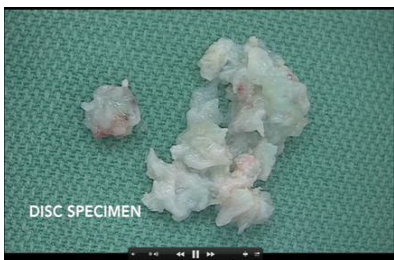

Figure 5d: Extracted disc fragment

Results Presented at International Meetings and in the Literature

Yeung and Tsou, in 2002, reported TFE on 307 consecutive patients with disc herniations who were candidates for transcanal microdiscectomy [1]. The study included intracanal and extracanal herniations. Recurrent herniations and patients with previous surgery at the same level were not excluded. Results were reported after a 1-year follow up. Ninety-one percent of the patients were satisfied with their results and would opt to undergo the procedure again if they had the same diagnosis and symptoms. The overall complication rate was reported to be 4%. Since 2002, the YESS technique has evolved and improved with the experience gained from this initial study.

Also in 2002, Tsou and Yeung separated out a subgroup of 219 patients with non-contained herniations and reported the results at 1 year [2]. Patient satisfaction was 91%. TFE could provide equivalent results to reported results of open microdiscectomy, even with noncontained, extruded herniations. The clinical outcome of a retrospective study of 113 consecutive patients with

minimal 2 year follow-up was reported in Spine, October 2004. The study was to evaluate the value of evocative chemo-discography as a technique to further stratify surgical indications. The results were modest, with 75% satisfactory clinical results, but 90% of the patients were still satisfied as they had other staged options for surgical treatment or they decided that they could live with their residual pain [3].

Yeung, at an International ISASS meeting, reported in 2013 50 Cases of Micro Lumbar Discectomy compared with SED performed by his group practice at DISC that included his son, Dr. Chris Yeung and associate Dr. Justin Field: MLD cases were L4-5=15, L5-S1=35. The average VAS Decreased from 6.5 to 1.7. Average ODI Decreased from 44% to 30%. Complications included seroma and 1 durotomy. Patients receiving MLD was usually for extruded, migrated, or sequestered HNP believed better suited for MLD, even in the experienced hands of transforaminal surgeons in the same spine group [3]. These cases were deemed to be more difficult for SED because the success for complete disc excision was less due to anatomic factors limiting access or sequestration and migration of a disc fragment.

SED™ included extruded, migrated, sequestered HNP at all levels felt possible by the operating surgeon with experience in SED. The SED group numbered 250 of the 309 consecutive levels operated. Average VAS was decreased from 6.6 to 2.5 and ODI decreased from 46% to 32%. 37 patients (15%) developed temporary dysesthesia in the 2-week post-operative period. Even with dysesthesia, however, improvement in VAS and ODI and patient satisfaction was comparable to MLD.

Today, Yeung does not just depend on the imaging study to diagnose clinical sciatica and claudication, but correlates the image with response to transforaminal endoscopic diagnostic and therapeutic injections. Patients with abnormal imaging also responding well to the injections get excellent consistent results with transforaminal decompression.

Discussion

Disc degeneration usually begins with annular tears or changes in endplate nutritional pathways by mechanical or pathophysiologic means. This is seen on MRI represented by modic changes. However, the disc ultimately fails due to failure of the annulus as opposed to the endplate, which can also cause pain, but to a less extent than the annulus. A study that focused on ablation of the vertebrogenic nerve demonstrated that the endplate can be a pain generator as well. Progressive injury and aging of the disc occur normally during the everyday stresses on the spine as well as in later life, as discovered after a traumatic event or simply from the aging process. Metabolic changes then progress following the traumatic event. In addition to the chemical effects of a degenerating disc on the free nerve endings as a source of discogenic pain,

other factors may lead to chronic back pain disorders. Free nerve endings in the annular fibers may be stimulated by stretching as the disc degenerates, bulges, and circumferential delamination of annular fibers occurs. Nonetheless, the vast majority of degenerated discs are temporary, then become essentially painless, likely related to variations in the location, concentration, and distribution of free nerve endings in the outer annuli. Certainly, back pain has many potential sources other than discal. Structures such as the facet joints, sacroiliac joints, and dorsal musculature can also be pain generators.

When discogenic pain becomes severely disabling, satisfactory contemporary treatment is primarily through obliteration/removal of the degenerated nucleus and stabilization either by selective endoscopic discectomy™ and thermal annuloplasty, interbody fusion or total disc replacement with an artificial disc.

Operative Treatment of Discogenic Back Pain

There has been a significant body of traditional literature to support the surgical treatment of discogenic low back pain. However, Yeung's study and other published literature on intradiscal therapy provides information and level 5 evidence that we should consider earlier consideration for MIS surgical treatment of symptomatic disc herniations. The study was conducted using provocative discography and computerized tomography to identify patients with refractory discogenic low back pain that might benefit from intradiscal decompression. Following a review of 307 consecutive patients with all types of HNP demonstrated good results with the transforaminal approach, a follow-up paper for contained HNP using the same technique provided as good or better results with less complications or adverse effects [1]. While interbody fusion replaces the degenerated nucleus pulposus with bone graft material and thus might be beneficial to these patients, this is an over aggressive solution to a less invasive and effective treatment.

Degeneration of discs is a slow, complex process involving several mechanical and physiologic components. Discogenic pain arises from either component but is primarily due to altered chemistry as the disc ages or when injured. When this pain is severely disabling and unyielding, the standard current traditionally preferred contemporary treatments are primarily surgical—namely, fusion or total disc. Less invasive surgical disc surgery, however, in the form of chemonucleolysis for intradiscal therapy with chymopapain, has level 1 evidence with 2 large double blind studies and 38 cohort studies, yet it was abandoned by industry by reasons only known to the pharmaceutical company that manufactured, but eventually abandoned the product. There are now published long term follow-up studies on chymopapain by Doug Wardlaw M.D.

Other transforaminal disc decompression options since chymopapain have emerged, but have been slow to be adopted by surgeons or have fallen out of favor. These fluoroscopic guided procedures were called Intra-Discal Electrical Thermal Therapy

(IDET), Coblation, Biacuplasty and Disc Fx. Yeung's use of a bipolar high frequency RF by Elliquence as a fluoroscopically guided mechanical disc decompression with RF to thermally modulate the disc and annulus has attracted interventionalist's interest, but endoscopic techniques in the literature still favors percutaneous intradiscal procedures that incorporate endoscopic visualization of patho-anatomy and patho-physiology. Yeung trademarked his procedure as "Selective Endoscopic Discectomy™" with thermal annuloplasty for discogenic back pain over other fluoroscopically guided procedures.

From a review of Yeung's database containing over 10,000 procedure since 1991, high performance athletes were able to salvage their athletic careers and have continued to personally follow-up with Yeung over the years by sending notes, reports and testimonials that have made their way to featured testimonials in Yeung's practice website at www.sciatica.com.

Conclusion

The treatment rationale for selective endoscopic discectomy™ and thermal annuloplasty includes endoscopic discectomy to decompress the disc and to remove the source of chemical sciatica from the deteriorating nucleus, but also removes the nuclear tissue embedded in the annular tear. Inflammatory tissue is thermally ablated.

With evolving techniques that continue to develop, such as diagnostic and therapeutic injections, indications can be further stratified for patient selection to the extent that 90% prediction of transforaminal surgical decompression results can be essentially be "warranted" to improve the painful condition without burning bridges for subsequent more standard and traditional surgery.

This is especially important for high performance athletes who needs to salvage a season in their sport or to return to their desired activity level. The overall conclusion is that while transforaminal endoscopic decompression is the least invasive for the treatment of discogenic pain and disc herniations, the final result is more dependent on the surgeon factor than on the technique itself, as there is a learning curve for adopters of this technique. Representative examples of various annular tears as seen by the endoscopic surgery are presented in the following figures and legend.

References

1. Yeung AT, Tsou PM (2002) Posterolateral endoscopic excision for lumbar disc herniation: surgical technique, outcome, and complications in 307 consecutive cases *Spine (Phila Pa 1976)* 27: 722-731.
2. Tsou PM, Yeung AT (2002) "Transforaminal Endoscopic Decompression for Radiculopathy Secondary to Intracanal Noncontained Lumbar Disc Herniations: Outcome and Technique" *The Spine Journal* 2: 41-48.
3. Tsou PM, Yeung CA, Yeung AT (2004) "Selective Endoscopic Discectomy™ and Thermal Annuloplasty for Chronic Lumbar Discogenic Pain: a minimal access visualized intradiscal procedure" *The Spine Journal* 2: 563-574.