

## Case Report

# High Grade Primary Intratesticular Leiomyosarcoma: A Very Rare Presentation

Abhishek Mukherjee<sup>1</sup>, Jaydeep Nath<sup>1</sup>, Debdeep Dey<sup>1</sup>, Srimanti Sinha<sup>1</sup>, Tridip Chatterjee<sup>2\*</sup>

<sup>1</sup>Suraksha Diagnostic Centre, Salt Lake, Kolkata, West Bengal, India

<sup>2</sup>Suraksha Genomics (R&D Division of Suraksha Diagnostic), Salt Lake, Kolkata, West Bengal, India

\***Corresponding author:** Tridip Chatterjee, Suraksha Genomics (R & D Division of Suraksha Diagnostic), Salt Lake, Kolkata, West Bengal, India, Tel: +91-98313252580; Email: ctridip@gmail.com, tridip.academic@gmail.com

**Citation:** Mukherjee A, Nath J, Dey D, Sinha S, Chatterjee T (2017) High Grade Primary Intratesticular Leiomyosarcoma: A Very Rare Presentation. J Oncol Res Ther 2017: J109.

**Received Date:** 09 January, 2017; **Accepted Date:** 08 February, 2017; **Published Date:** 15 February, 2017

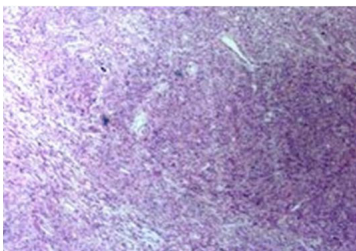
### Abstract

Primary intratesticular leiomyosarcoma of the testis is an extremely rare disease. High grade (Grade 3) types are rarer. We herein present a case of a left testicular mass in a 58 year old male patient who had undergone radical orchiectomy. Preliminary FNAC had revealed a spindle cell neoplasm. Radiological presentation, histomorphological findings along with immunohistochemical positivity for SMA and Desmin are consistent with High Grade Primary Intratesticular Leiomyosarcoma. This case, to the best of our knowledge is only the third case, reported in literature till date.

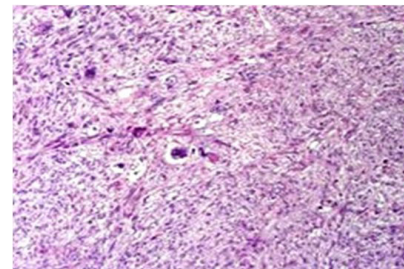
**Keywords:** High Grade; Intratesticular Leiomyosarcoma

### Introduction

Leiomyosarcomas are malignant soft tissue tumors arising from smooth muscle cells of mesenchymal origin [1,2]. Primary leiomyosarcoma of testis is extremely rare [1,3]. Various sarcomas reported in the literature include fibrosarcoma, leiomyosarcoma, Kaposi sarcoma, angiosarcoma, osteosarcoma, chondrosarcoma and Ewing's sarcoma. Sarcomatous changes are generally observed in somatic type malignancies in germ cell tumor, in spermatocytic seminoma or in sertoli cell-tumor [4]. Leiomyosarcoma of the testis is known to occur following radiotherapy, use of anabolic corticosteroids and in association with testicular germ cell tumors. Occurrence of testicular leiomyosarcoma without these events (primary leiomyosarcoma) is extremely rare [4,5]. Figure 1 and 2.



**Figure 1:** Hematoxylin and eosin: (100x): hypercellular areas were noted with numerous spindle shaped tumor cells arranged in storiform pattern with short fascicles.



**Figure 2:** Hematoxylin and eosin: (400x): Spindle shaped tumor cells, pleomorphic tumor giant cells and intervening fibrovascular septae with lymphocytic infiltrate. Mitotic rate was increased (>10/10 hpf).

### Case Report

A 58 year old male patient presented with a long standing large left testicular mass, which had suddenly increased in size in the just 3-4 months. There was no evidence of significant past history. Physical examination revealed a large, firm, non tender left testicular mass with no associated superficial lymph nodes. There was no evidence of any secondary changes on the overlying scrotal skin. Per rectal examination did not reveal any enlarged prostate.

An ultrasonographic examination of left testis showed a very large heteroechoic solid mass contained within tunica vaginalis with significant vascularity. There was no evidence of calcification. Left epididymis was normal. Spermatic cord was dilated. Right testicle was normal in size and showed echogenicity. FNAC

carried out from the swelling showed plenty of ovoid to spindle cells, arranged singly and in loose clusters, with moderate degree of anisocytosis. The findings were suggestive of spindle cell neoplasm.

The patient underwent left radical orchiectomy. Macroscopically, we received a well encapsulated grayish white, firm, circumscribed solid tumor mass replacing the predominant testicular parenchyma and measuring 18 x13x9 cm figure 3. There was no evidence of hemorrhage or necrosis. Histologically hypercellular areas were noted with numerous spindle shaped tumor cells arranged in storiform pattern with short fascicles, several pleomorphic tumor giant cells and intervening fibrovascular septae with lymphocytic infiltrate. Mitotic rate was increased (>10/10 hpf). Above histomorphological features were strongly suggestive of a high grade sarcomatous lesion.

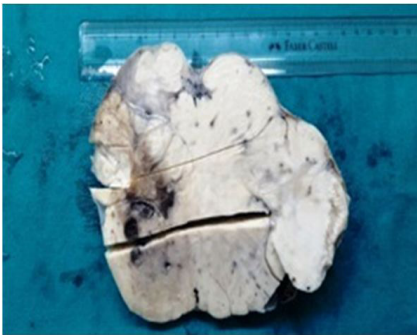

Figure 3: Gross presentation of testicular tumor mass.

Immunohistochemical staining was performed from representative tumor area. Tumor cells were strongly positive for SMA and Desmin figure 4 and were negative for CD 68, S100, CD 117 and cytokeratin. The above immunohistochemical findings along with histomorphological findings were conclusive of leiomyosarcoma.

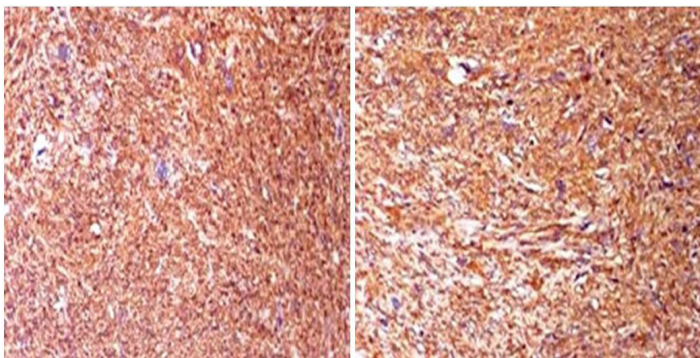


Figure 4: Tumor cells were strongly positive for SMA and Desmin respectively. SMA Desmin.

## Discussion

Leiomyosarcoma is a rare disease entity not often encountered in the genito-urinary system. When presented, 80% arises

from the soft tissue of the spermatic cord and 20% originates from the epididymis or dartos of the scrotum [3]. Leiomyosarcomas are malignant soft tissue tumors, arising from the undifferentiated smooth muscle cells of the mesenchymal origin [1,3-5].

Intratesticular leiomyosarcoma is believed to arise from the smooth muscle elements of the testicular parenchyma such as blood vessels or the contractile cells of the seminiferous tubules [1,4,5]. Intratesticular leiomyosarcoma is an extremely rare tumor [2]. Although approximately 100 paratesticular leiomyosarcomas have been reported in the literature, fewer than 10 cases of primary leiomyosarcoma of the testis have been mentioned [2,3]. Patients with intratesticular leiomyosarcoma are usually older than 40 years [5]. The age of the patients ranged between 30 and 76, with a mean age of 50.2 [2]. The majority of these patients present with painless testicular enlargement and inguinoscrotal discomfort. As compared with leiomyosarcoma at the other sites, the prognosis of intratesticular leiomyosarcoma remains good. Radical orchiectomy / high inguinal orchiectomy, followed by surveillance appears to be the treatment of choice [5].

Testicular tumors are classified depending upon the tissue of origin into germ cell tumors and non-germ cell tumors. Malignant mesenchymal tumors of the testis are extremely rare. The prognosis of intratesticular leiomyosarcoma appears good as of 12 published cases, only two cases showed metastasis. Only two cases of high grade intratesticular leiomyosarcoma have been reported in the literature till date [4]. In our case we also encountered a high grade leiomyosarcoma exhibiting bizarre tumor giant cells, significant nuclear pleomorphism with high mitotic count.

So, we believe that this extremely rare case of high grade primary intratesticular leiomyosarcoma will enlighten all the scientific and medical community.

## References

1. Borges RP, Vila F, Cavadas V, Queirós J, Marcelo F, Encinas A (2007) Primary Testicular Leiomyosarcoma - Case Report. *Acta Urológica* 4: 45-47.
2. Yoshimine S, Kono H, Nakagawa K, Kikuchi E, Miyajima A, et al. (2009) Primary intratesticular leiomyosarcoma. *CUAJ* 3: 74-76.
3. Labanaris AP, Zugar V, Smiszek R, Nützel R, Kuhn R (2010) Primary Leiomyosarcoma of the Testis. A Case Report. *Anticancer Research* 30: 1725-1726.
4. Damle RP, Suryawanshi KH, Dravid NV, Newadkar DV (2013) Primary intratesticular pleomorphic leiomyosarcoma: A rare case report. *Indian J Pathol Microbiol* 56: 425-427.
5. Kumar M, Patne SCU, Kumar S, Shukla VK (2009) Primary high-grade testicular leiomyosarcoma: *Indian Journal of Pathology and Microbiology* 52: 91-93.
6. Unlu Y, Huq GE, Ozyalvacili G, ÖZYALVAÇLI G, ZENGİN M, KOCA SB, et al. (2015) Paratesticular sarcomas: A report of seven cases. *Oncology Letters* 9: 308-312.