

Case Report

Obturator Foramen By-Pass Graft For Groin Infection: Case Report and Literature Review

Caicedo D¹, Requena¹, Villardefrancos R¹

¹Department of Angiology and Vascular Surgery, Complejo Hospitalario de Pontevedra, Pontevedra, Spain.

***Corresponding author:** D. Caicedo Valdés, Department of Angiology and Vascular Surgery, Complejo Hospitalario de Pontevedra, Avda de Montecelo, s/n 36071, Pontevedra, Spain Tel: +34 986800134; E-mail: diego.caicedo.valdes@sergas.es

Citation: Caicedo D, Requena J, Villardefrancos R. (2016) Obturator Foramen By-Pass Graft For Groin Infection: Case Report and Literature Review. J Surg 2016: J105.

Received Date: 11 November, 2016; **Accepted Date:** 28 November, 2016; **Published Date:** 5 December, 2016

Abstract

Infections at groin level are a relatively frequent complication associated to the use of prosthetic grafts in vascular practice. Sometimes it may be a threatening pathology depending on the virulence of the involved germs and the patients' general health state. In these cases, the gold standard management implies the graft resection and aggressive removal of the affected tissues, in addition to broad spectrum antibiotic therapy. Since restoration of the flow is mandatory in order to avoid the leg ischemia, a new extra-anatomical route is recommended to prevent the infected field.

Objective: We report a clinical case of a partially infected aorto-bifemoral by-pass graft successfully treated by the restitution of the infected part with an obturator by-pass graft, a technique barely performed in surgical practice.

Conclusion: In case of groin infection in patients undergoing a prosthetic by-pass graft, the obturator foramen is a good alternative to keep the new graft away from infected tissues. Good anatomy knowledge and some surgical skills are required to make it properly.

Keywords: Groin Infection; Aorto-bifemoral by-pass graft; Extra-anatomical route; Obturator foramen.

Introduction

Extra-anatomical by-pass grafts were designed as an alternative for revascularization in those patients where the anatomical conditions are not advised or possible. The infection of one territory is one of the best-known indications for these sorts of by-pass grafts. Although we are currently in the endovascular era with lots of procedures performed by using endoluminal technique, aorto-bifemoral by-pass graft (ABFBG) is still having a preponderant place in Vascular Units, because the aortic bifurcation and iliac vessels are common sites of a severe atherosclerotic occlusive disease making difficult the stenting approach. Despite of the fact that this procedure has been described for bilateral iliac obliteration (Leriche's syndrome) [1], this pathology is the typical example for ABFBG [2].

One of the most important challenges for vascular surgeons is the groin infection in patients undergoing a by-pass graft. This is a tricky situation, simply because one does not know what the evolution will be, as it will depend on the virulence of the germs found and the patient's general health state. Elderly patients, for example, are usually in a state of immune-suppression. The gold

standard management for the aforementioned vascular complication is an extensive removal of the graft and the affected tissues. In cases with the infection confined in the groin, the flow restoration may be solved by an "in situ" reconstruction with an autologous femoral or saphenous vein, cryopreserved allografts, or synthetic grafts impregnated with antibiotics [3,4], with high risk of reinfection and new complications (pseudoaneurysms, rupture and bleeding, and limb loss). Other feasible option is the extra-anatomical reconstruction, avoiding the infected area [3-5]. The obturator foramen as a by-pass route was first described in 1963 by Shaw and Baue [6].

We report a clinical case of a partial infection in an ABFBG successfully treated by performing an obturator foramen by-pass graft (OBG) to the distal profunda femoris artery (PFA), with the transposition of the superficial femoral artery (SFA).

Case Report

Female patient, 58 years old, with medical history of arterial hypertension, dyslipidemia, bronchial asthma and hyperhomocysteinemia. She underwent a prosthetic aorto-bifemoral by-pass graft (ABFBG) in 2010 as a result of an unsuccessful bilateral iliac endovascular approach. Four years later, she was admitted several times for fever, groin infection and femoral pseudoaneurysm in

both groins, leading to the restitution of both femoral anastomosis by a new ones with a Dacron-silver graft and surgical extensive debridement. Due to the germ found in one of these admissions, *Escherichia coli*, it was suspected that the bacteremia could come from the urine system, and laparoscopic ureterolysis of both ureters was performed. Over the follow-up, the patient presented a new admission for infection of the right groin, with the angio-computed tomography (CT) showing a collection around the right leg of the ABFBG at retroperitoneal level extending to the groin, compatible with infection (Figure 1).

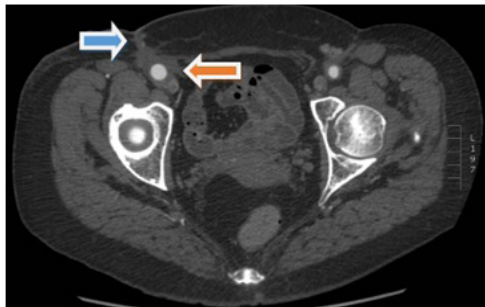


Figure 1: Angio-CT (axial view) showing the prosthetic right graft surrounded by an infected collection (orange arrow) along with a cutaneous fistula (blue arrow).

During the stay of the patient, several samples were sent for being cultivated (blood and pus) but none of them yielded germs this time.

In order to support the diagnosis and see the extension of the graft infection, a ^{99m}Tc -HMPAO leukocytes gammagraphy with single photon emission computerized tomography (SPECT) was attached, proving that the infection was restricted to the groin and the distal two-thirds of the right graft leg (Figure 2).

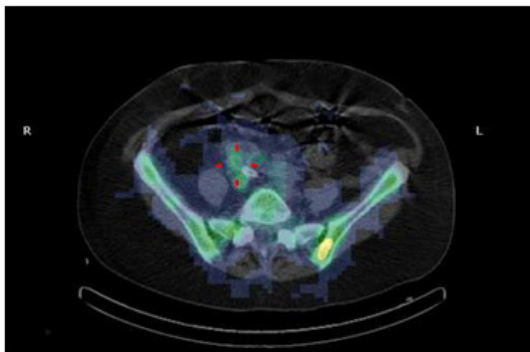


Figure 2: ^{99m}Tc -HMPAO leukocytes gammagraphy with single photon emission computerized tomography (SPECT) showing the affected right graft limb of the aorto-bifemoral by-pass graft.

After having been discussed the pros and cons of the intervention with the patient and her family, we decided to perform a resection of the affected graft and a substitution by a new trans-obturator by-pass (Figure 3 and 4).

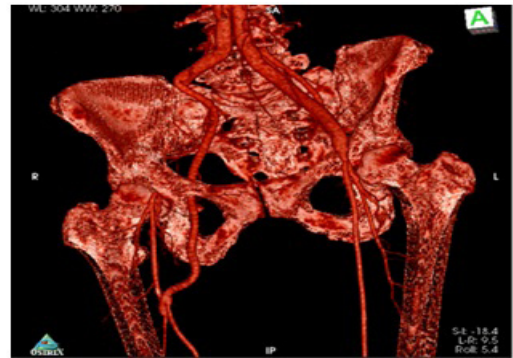

Figure 3: 3D-Angio-CT reconstruction (antero-lateral view) showing the partial resection of the infected right branch of an aorto-bifemoral by-pass graft, and substitution by a new obturator foramen by-pass graft. Take note of the distal anastomosis at distal profunda femoral artery (far from infection) and the transposition of the superficial femoral artery on the distal graft anastomosis.

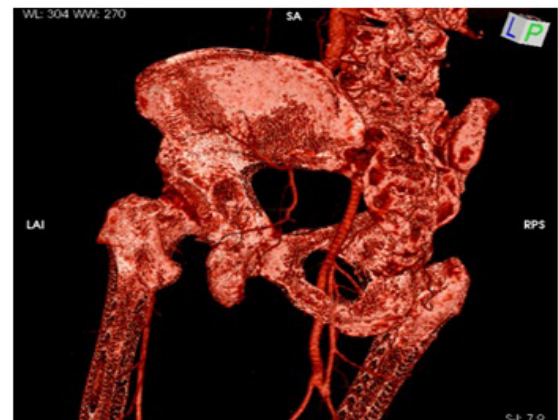

Figure 4: 3D-Angio-CT reconstruction (postero-lateral view) perfectly showing the graft crossing the obturator foramen.

The sterile part of the operation was achieved first. The infected groin was sealed off with an occlusive drape. Through an incision made in the middle third of the anterior aspect of the thigh, the distal PFA and middle portion of the SFA was controlled, far enough away from the infected zone. After this, a retroperitoneal access by means a transverse abdominal incision was made with a safety distance away from the groin. The peritoneum and its contents were retracted medially, along with the ureter and the pelvic organs. The previous graft was dissected until a firm incorporation of the same in the surrounding tissues was reached, indicating that the proximal part of the graft could be preserved. The right branch of the graft was then transected, closed and pushed down towards the inguinal ligament. The obturator foramen was identified easily by digital palpation on the anterior-medial aspect of the foramen. A tunnel was made trying to connect both incisions, passing the tunneling instrument upwards. We led the tunneler through the foramen bimanually, palpating where the tip of the tunneler was

entering, making a blunt and sharp dissection. The instrument was passed under the obturator vessels and nerve, and routed behind the pectineus and adductor muscles. Secondly, a 6 mm externally ringed polytetra-fluoro-ethylene (PTFEe) graft was inserted and both vascular anastomosis were done. Once the sterile part had concluded, we shifted to the infected part. The groin was reopened and the infected graft was removed, along with a large debridement of the inguinal surrounding tissues. The femoral vessels were cut off and ligated. Finally, a covering flap with sartorius muscle was accomplished.

The whole intervention was achieved under general anesthesia. Over the first postoperative days, the patient complained of weakness in her right leg. Once we ruled out a vascular problem, and taking into account that the electromyography only showed small changes in the sciatic nerve, an intravenous therapy with dexamethasone was administrated to the patient with an excellent response in 24 hour, and almost full recovery in 48 hour.

The patient was discharged twelve days after the surgery, walking normally and with the right leg well perfused, without fever and with the C-reactive protein (CRP) and procalcitonin in normal ranges. Even though all of the cultures were negative, a long time antibiotic therapy was given to the patient with linezolid (3 months) and trimethoprim-sulfamethoxazole (6 months). This kind of therapy was recommended by the Infectious Disease Unit, as a germ with biofilm was suspected. Our institution does not possess a special culture medium for these sort of germs.

Discussion

Since Shaw and Baue first described the obturator by-pass graft (OBG) in 1963 [6], this procedure has been only published as a clinical case or small series. One of the most important data comes from Nevelsteen et al., with 55 cases over a period of 16 years [7].

The aims with this technique is to create an arterial conduit from the retroperitoneal abdominal cavity to a thigh's artery, different depending on the run-off, while avoiding infected or destroyed tissues in the groin.

Aorto-bifemoral by-pass graft (ABFBG) infection remains being the main indication for OBG in 80% of cases [8]. Some other indications are: infected femoral aneurysms, extensive local trauma [9], and tumor surgery [10], among others.

The literature reports that this procedure is safe and durable, with a primary patency rate of 76% at 24 months in clinical series [3,11,12]. In 1987, Nevelsteen et al. reported a 3 year patency rate of 71% for above-the-knee by-pass grafts, but a 45% of patency for below-the-knee anastomosis [7]. Mortality rate vary from 0% to 17%, depending on the series [13], being the determining factors: the atherosclerotic condition, germ virulence, patient's age or

general state, or the experience of surgical group.

There are no arguments against the complex and serious nature of groin infection, with a reported mortality rate of 17%, and an amputation rate as high as 41% [14]. In this sense, we consider that OBG is an appropriate option because it is deep and distant from the infected area. In our case, although the new graft was sewed to the PFA, the transposition of the SFA on the anastomosis improved the outflow and, likely, the patency. In fact, after a follow-up of 6 years, the patient has no claudication, maintaining the pedal pulse in the foot.

In our opinion, this technique is uncommon at this location because of the potential risk of complication that it carries out. For this reason, in general it is preferred by the authors the "in situ" restoration of the flow with an autologous grafts (femoral or saphenous vein), as a vein has better patency and good resistance against the infected tissues, and this technique may offer a smaller likelihood of surgical complications. However, we have to take into account that this is a good option if the germs have no high virulence and that a new pseudoaneurysm or rupture could be present in the future [15,16]. Bacterial species as *Pseudomonas aeruginosa* or methicillin-resistant *Staphylococcus aureus* (MRSA), as well as extended-spectrum beta-lactamase-producing bacteria (mainly *E.coli* and *Klebsiella*) or multi-resistant microorganisms are so virulent that it is recommended to avoid leaving a graft in this infected field. The "in situ" restoration may maintain the risk for subsequent re-infections and potential complications [17]. In this reported case, it was suspected a biofilm germ, which is characterized by a high resistance to antibiotics and re-infection. If we add the great fibrosis in the groin, we considered that an autologous vein would not have been suitable, and that the extra-anatomical OBG could represent a better option. We do not defend this technique as a first step, as the groin infection often can be solved easier with an "in situ" technique. When the latter is not possible or recommended as a result of a virulent bacterium, the OBG may be a good alternative if performed appropriately.

About the point of what kind of graft must be selected for OBG, we prefer a ringed PTFE graft, as this conduit offers greater resistance against compression and kinking through the route than the vein. Under special circumstances the OBG can be performed as a cross-over ilio-profunda procedure using the contralateral iliac artery as inflow site [18]. The obturator approach has also been used as a primary procedure for ABFBG in a case in which the groin was infected from non-aortic surgery [19].

There are several other options for revascularization after the removal of an infected graft in the groin, including an axillo-femoral by-pass by means a lateral route [20,21], a subscrotal by-pass [22], a semi-closed endarterectomy (ring-stripping) or endovascular approaches if possible. Nevertheless, it seems that OBG

provides better results than all these alternatives [4]. In addition, “in-situ” revascularization with a rifampicin or silver-impregnated graft may offer satisfactory results [23]. When full ABFBG removal is required, a special solution with a retroperitoneal in-line aortic bypass with PTFE through clean tissue planes has been advocated [17].

Perioperative complications approximately occur in 7% of cases [6,7]. The specific potential complications of OBG include the obturator nerve injury, hemorrhage secondary to damage of obturator foramen vessels and perforation of the urinary bladder, vagina or sigmoid colon. Most of them are due to a faulty tunneling of the graft over the surgery [24,25]. All these drawbacks can be minimized by careful tunneling and dissection and respecting some surgical principles. Our patient suffered a weakness of the right leg over the first 24 hours, with an excellent response to the administration of intravenous glucocorticoids. Because of the fast recovering and the small and no significant changes seen on sciatic nerve in the electromyography test, we believe that the injury was small, and that it could be done in the thigh while tunneling. Moreover, we can't forget that the groin was reopened several times with the possibility of the femoral nerve harm.

Referring to surgical aspects, we prefer tunneling upwards, from the thigh to the obturator foramen, in a plane anterior to the adductor magnus muscle and posterior to the pectineus, adductor longus and brevis muscles. Some surgeons choose to do this maneuver from the retroperitoneal space downwards [26], but it is more difficult to have control of the graft way out in the thigh.

Another aspect is the abdominal surgical access. In spite of the fact that a transperitoneal median approach is often preferred, a retroperitoneal via is a good alternative if one is certain that the infection is limited around the inguinal area. The gammagraphy might provide enough information to support this fact.

It always exists a deleterious complication when we are dealing with vascular grafts: the graft thrombosis. This is a great trouble that may lead to severe ischemic symptoms, threatening the viability of the limb, as during the surgery both femoral arteries are usually ligated and collateral vessels sacrificed. In that setting, thrombectomy or thrombolysis of the OBG should be attempted without delay.

Since the OBG is normally performed in an infection context, long-term postoperative antibiotic treatment is advised. There is no consensus in the literature about the duration in these cases, but a long period is strongly recommended. The Infectious Disease Unit suggested a double therapy with linezolid, 3 months, and trimethoprim-sulfamethoxazole, 6 months, for our patient, since a germ with biofilm was suspected and a new infection would have been catastrophic. Yearly gammagraphy is being performed in order to detect a reinfection.

The obturator approach has been used for vascular reconstructions for many year, but this case is novel because it is used primarily to salvage an original ABFBG which would be otherwise treated with complete removal of the graft with a bigger morbidity and mortality.

Conclusion

Though uncommon these days and often overlooked, obturator by-pass graft is a good alternative to restore the flow in cases of graft infection in the groin when “in situ” restoration is not possible or recommended, and it should be a part of the vascular surgeon's armamentarium. This graft is safe, effective and durable, but requires a good knowledge of the anatomy and some surgical skills. It should be considered as a first option in selected cases because of its high patency rate. We have presented a clinical case with a literature review.

References

1. Setacci C, Galzerano G, Setacci F, De Donato G, et al. (2012) Endovascular approach to Leriche syndrome. *Journal of Cardiovascular Surgery* 53: 301-306.
2. Leriche R and Morel A (1948) The syndrome of thrombotic obliteration of the aortic bifurcation. *Ann Surg* 127: 193-206.
3. Patel A, Taylor SM, Langan EM, Snyder BA, Cull DL, et al. (2002) Obturator bypass: A classic approach for the treatment of contemporary groin infection. *Am Surg* 68: 653-658.
4. Thompson JK, Strunk RS, Giglia JS (2006) Bilateral obturator bypass for combined aortic and femorofemoral graft infection. *J Vasc Surg* 44: 888.
5. Kim DI and Joh JH (2005) A Case Report of Bilateral Obturator Foramen Bypass. *EJVES Extra* 10: 31-32.
6. Shaw RS and Baue AE (1963) Management of sepsis complicating arterial reconstructive surgery. *Surgery* 53: 75-86.
7. Nevelsteen A, Mees U, Deleersnijder J, Suy R (1987) Obturator bypass: a sixteen year experience with 55 cases. *Ann Vasc Surg* 1: 558-563.
8. Kroese A and Rosen L (1996) what is the optimal treatment for the infected vascular graft? In: Greenhalgh R, Fowkes F, editors. *Trials and tribulations in vascular surgery*. London: WB Saunders 17-34.
9. Stain SC, Weaver FA, Yellin AE (1991) Extra-anatomic bypass of failed traumatic arterial repairs. *J Trauma* 31: 575-578.
10. Cerdán FJ and Núñez L (1983) Revascularización extra-anatómica de los miembros inferiores. III. By-pass a través del agujero obturador. *Angiología* 35.
11. Matoussevitch V, Aleksic M, Gawenda M, Brunkwall J (2007) Primary extra-anatomical revascularization for groin infections in drug addicts. *Vasa - J Vasc Dis* 36: 210-214.
12. Ferreira U, Reis LO, Ikari LY, da Silva W, Matheus WE, et al (2008) Extra-anatomical transobturator bypass graft for femoral artery involvement by metastatic carcinoma of the penis: report of five patients. *World J Urol* 26: 487-491.
13. Busch A, Lorenz U, Tiurbe GC, Bühler C, Kellersmann R (2013) Femoral vein obturator bypass revascularization in groin infectious bleeding:

two case reports and review of the literature. *J Med Case Rep* 7: 75.

14. Porter JM, Yeager RA, Porter JM (1992) Arterial and Prosthetic Graft Infection. *Ann VascSurg* 6: 485-491.
15. Quiñones-Baldrich WJ and Gelabert HA (1990) Autogenous tissue reconstruction in the management of aortoiliofemoral graft infection. *Annals of Vascular Surgery* 4: 223-228.
16. Ehrenfeld WK, Wilbur BG, Olcott CN, Stoney RJ (1979) Autogenous tissue reconstruction in the management of infected prosthetic grafts. *Surgery* 85: 82-92.
17. Darling RC, Resnikoff M, Kreienberg PB, Chang BB, Paty PS, et al (1997) Alternative approach for management of infected aortic grafts. *J Vasc Surg* 25: 106-112.
18. Atnip RG (1991) Crossover iliopofunda reconstruction: an expanded role for obturator foramen bypass. *Surgery* 110: 106-108.
19. Hinojosa CA, Anaya-Ayala JE, Laparra-Escareno H, Lizola R, Torres-Machorro A (2016) Aortobifemoral Reconstruction with Right Extra-Anatomical Obturator Foramen Bypass due to a Septic Groin. *Vasc Spec Int* 32: 57-61.
20. Trout HH and Smith CA (1982) Lateral iliopopliteal arterial bypass as an alternative to obturator bypass. *Am Surg* 48: 63-64.
21. Leather RP and Karmody AM (1977) A lateral route for extra-anatomical bypass of the femoral artery. *Surgery* 81: 307-309.
22. Baird R (1994) Subscrotal bypass for the infected groin. In: Greenhalgh RM, editor. *Vascular and Endovascular Surgical Techniques* 257-259.