

## Case Report

# Clopidogrel-Associated Neutropenia: A Rare but Important Adverse Effect

AS Thayaparan\*, K Gupta, A Omari

Department of Vascular Medicine, St Vincents Hospital, Sydney, Australia

\*Corresponding author: A.S Thayaparan, Department of Vascular Medicine, St Vincents Hospital, 390 Victoria street, Darlinghurst, Sydney NSW 2010, Australia, Tel: +6183821111, Email: archana.selvakumar@gmail.com

Citation: Thayaparan AS, Gupta K, Omari A (2016) Clopidogrel-Associated Neutropenia: A Rare but Important Adverse Effect. Ann Case Rep 2016: ACRT-122.

Received Date: 03 November, 2016; Accepted Date: 23 November, 2016; Published Date: 30 November, 2016

### Abstract

Clopidogrel is a medication widely prescribed in the community for ischaemic heart disease, cerebrovascular and peripheral arterial disease. Neutropenia is a rare and under recognised adverse effect of Clopidogrel use. Among patients requiring ongoing dual anti-platelet therapy, this case demonstrates that Prasugrel, although structurally similar, can be a reasonable alternative in the setting of Clopidogrel-associated neutropenia.

### Clinical record

A 79 year old woman presented to the emergency department with right lower limb deep vein thrombosis extending into the popliteal vein. Routine blood tests revealed leukopenia – white cell count  $0.5 \times 10^9$  with neutrophils  $<0.1 \times 10^9$  with other cell lines preserved (Table 1). She was admitted for anticoagulation with Enoxaparin.

Table 1: Admission bloods

	Admission	Reference range
Hb	123	115-165g/L
Platelets	179	$150-400 \times 10^9/L$
WBC	0.5	$4.0-11.0 \times 10^9/L$
Neutrophils	$<0.1$	$2.0-7.5 \times 10^9/L$
Lymphocytes	0.4	$1.5-4.0 \times 10^9/L$
Monocytes	0.1	$0.2-1.0 \times 10^9/L$
Eosinophils	0	$0.0-0.4 \times 10^9/L$
Basophils	0	$0.0-0.1 \times 10^9/L$

She had a history of ischemic heart disease with non-ST elevation myocardial infarction three months prior. At that time, angiography diagnosed triple vessel disease but as she was considered unsuitable for coronary artery bypass grafting, staged PCI to the vessels was performed. She commenced dual anti-platelet therapy with Aspirin 100 mg daily and Clopidogrel 75 mg daily, as well as Pantoprazole at that time. Her co-morbidities included

a right nephrectomy for renal cell carcinoma; chronic kidney disease; interstitial pulmonary fibrosis; and hypertension. Her additional medications at the time of her current presentation were Perindopril and a tapering course of Prednisone at 12.5mg twice daily. She had been on prophylactic Co-trimoxazole up to two weeks earlier. Three weeks prior to this presentation neutrophil counts were slightly above the normal range (Figure 1).

Shortly after admission, she developed respiratory sepsis requiring admission to the intensive care unit. She received intravenous Piperacillin with Tazobactam for a period of ten days with doses adjusted for renal impairment. She developed a groin haematoma at the insertion site of a femoral arterial catheter and Enoxaparin therapy was changed to intravenous unfractionated heparin.

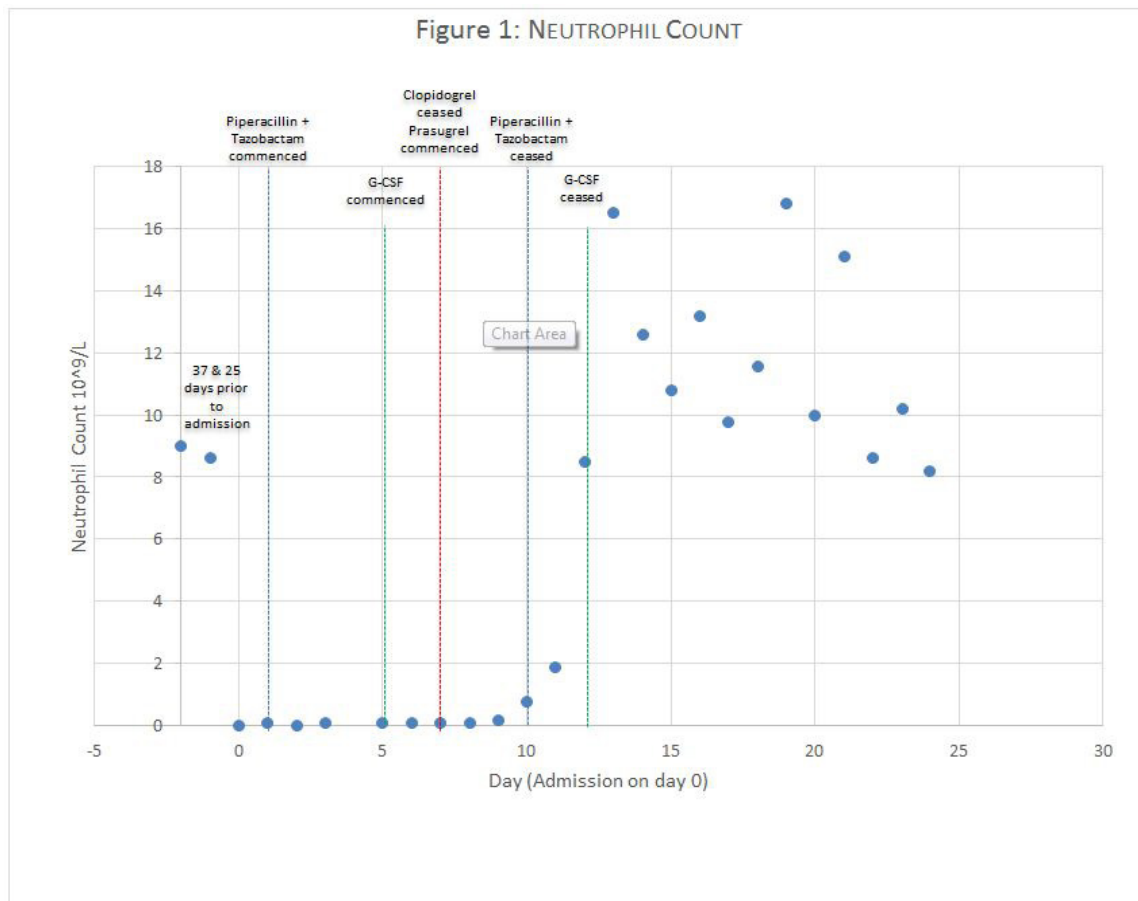
Her white cell and neutrophil counts remained suppressed (figure 1) and blood film examination showed no abnormal circulating cells or blasts with occasional large and giant platelets. She was administered daily granulocyte stimulating factor with no improvement. Bone marrow biopsy showed a hypoplastic marrow with virtually absent granulopoiesis and relatively preserved megakaryopoiesis and erythropoiesis.

Due to her recent coronary artery stenting, it was felt that dual anti-platelet therapy was indicated, so Clopidogrel was ceased and Prasugrel 10mg daily introduced. Within two days, her neutrophil count improved to  $0.2 \times 10^9$  and continued to trend upwards. G-CSF was ceased when neutrophil count was greater than  $1.0 \times 10^9$ .

Her admission was complicated by development of a large spontaneous buttock haematoma necessitating cessation of anti-coagulation and inferior vena cava filter insertion; as well as a urinary tract infection.

Her neutrophil count recovered completely, with an initial

rise above the normal range, attributed to the ongoing effect of G-CSF and subsequently urinary tract infection. She continues on dual anti-platelet therapy and her Prasugrel dose was adjusted to 5mg due to age. Anti-coagulation was yet to be reintroduced when she was discharged from hospital to a rehabilitation facility.



## Discussion

This patient's neutropenia, based on time course and clinical response to withdrawal of the drug, was most likely due to Clopidogrel. Despite the widespread use of Clopidogrel, neutropenia is a little recognised though significant adverse effect. This is the second case to demonstrate that substitution with Prasugrel is a reasonable approach to managing these patients when ongoing dual anti-platelet therapy is strongly indicated [1].

Ticlopidine, Clopidogrel, and Prasugrel are anti-platelet agents belonging to the thienopyridine family. These agents irreversibly block the binding of adenosine diphosphate to the platelet receptor P2Y<sub>12</sub> and thereby decrease platelet aggregation. Ticlopidine was the first to be marketed in Australia but has been supplanted by newer agents due to haematological adverse effects,

including neutropaenia [2]. The mechanism by which Ticlopidine causes neutropenia has been established, but is unknown for other thienopyridines [3]. In the Clopidogrel vs Aspirin in Patients at Risk of Ischaemic events (CAPRIE) trial, severe neutropenia (< 0.45 x 10<sup>9</sup>/L) was observed in four patients (0.04%) with a median onset of 22 days [4]. Prasugrel, which is more rapidly hydrolysed to an active metabolite has an even lower risk (<0.01%) [5].

In this case, the patient had commenced Clopidogrel three months prior to developing neutropenia, and frequent blood tests demonstrated stable neutrophil counts up until three weeks prior to presentation.

The choice to substitute Clopidogrel with Prasugrel does however carry an increased risk of bleeding especially in the elderly [6]. Dose reduction may therefore be appropriate as in this case.

While there is widespread awareness of the bleeding risks associated with Clopidogrel, neutropenia remains an important and under recognised haematological adverse effect. This case highlights that patients prescribed Clopidogrel need to be monitored for neutropenia even months after initiation as the reaction may be delayed and counselled to monitor for early evidence of sepsis. Where neutropenia occurs and ongoing dual anti-platelet therapy is indicated, Prasugrel may be a reasonable alternative although close long-term monitoring and clinical vigilance are required.

#### Lessons From Practice

- Clopidogrel is widely prescribed in the community for ischaemic heart disease, cerebrovascular and peripheral arterial disease.
- Thienopyridines are known to have haematological adverse effects, which include neutropenia as well as bleeding.
- Despite being structurally similar, Prasugrel is a reasonable alternative for patients with Clopidogrel-associated Neutropenia.

## References

1. Khangura S and Gordon WL (2011) Prasugrel as an alternative for Clopidogrel-associated Neutropenia. Canadian Journal of Cardiology 27: 869e9-869e11.
2. Ono K, Kurohara K, Yoshihara M, Shimamoto Y, Yamaguchi M (1991) Agranulocytosis caused by ticlopidine and its mechanism. American journal of hematology 37: 239-242.
3. Sharis PJ, Cannon CP, Loscalzo J (1998) The antiplatelet effects of ticlopidine and clopidogrel. Annals of Internal Medicine. 129: 394-405.
4. Wu CW, Wu YJ, Wu CC (2015) Clopidogrel-Associated Neutropenia: Case Report and Review of the Literature. American journal of therapeutics.
5. Wiviott SD, Braunwald E, McCabe CH, Montalescot G, Ruzyllo W, et al. (2007) "Prasugrel versus clopidogrel in patients with acute coronary syndromes" N Engl J Med 357: 2001-2015.
6. Effient. Prasugrel Hydrochloride. MIMSONline - [https://www.mimsonline.com.au.acs.hcn.com.au/Search/FullPI.aspx?ModuleName=ProductInfo&searchKeyword=prasugrel&PreviousPage=/Search/QuickSearch.aspx&SearchType=&ID=83490001\\_2](https://www.mimsonline.com.au.acs.hcn.com.au/Search/FullPI.aspx?ModuleName=ProductInfo&searchKeyword=prasugrel&PreviousPage=/Search/QuickSearch.aspx&SearchType=&ID=83490001_2)