

Research Article

Foreign Bodies in Pediatric Patients: An Otolaryngologic Urgency?

Janaína Oliveira Bentivi Pulcherio^{1*}, Valeria Maciel Costa¹, Ana Beatriz Sousa Costa¹, Melyssa Fernanda Bentivi Andrade¹, Bruno Bavaresco Gambassi², Joao Melo E Sousa Bentivi²

¹Federal University Of Maranhão, Department of Medicina I, São Luís-MA, Brazil

²CEUMA University, Physical Education Department, São Luís-MA, Brazil

***Corresponding author:** Janaína Oliveira Bentivi Pulcherio, Federal University of Maranhão, Department of Medicina I, Praça Gonçalves Dias, nº 2, Centro, São Luís-MA, Zip Code: 65020-240, Brazil. Tel: +5598991901212, E-mail: janabentivi.ori@gmail.com

Citation: Pulcherio JOB, Costa VM, Costa ABS, Andrade MFB, Gambassi BB, et al. (2017) Foreign Bodies in Pediatric Patients: An Otolaryngologic Urgency? Arch Pedia 2017: APDT-116

Received Date: 22 May, 2017; **Accepted Date:** 23 June, 2017; **Published Date:** 01 July, 2017

Abstract

Introduction: The children are important customers of otolaryngologic attendances because of foreign bodies. Infant's curiosity, plays, hygiene and incidental entry are common causes. Some foreign bodies are not life-threatening but there can be severe complications related to their long permanence or their displacement to airways.

Objective: To analyze foreign bodies' cases of children attended in an emergency hospital in Brazil.

Materials and Methods: Retrospective study from medical records of 105 children aged from 0 to 12 years old.

Results: The higher part of cases was of nasal foreign bodies. The most common foreign bodies found were beans, grains and plastic objects. The average of the period between their placement and removal was 32,4 days.

Comments: The average of time of evolution in this study was longer than in other references what would increase the risks of complications. We detach the responsibility of parents and keepers in this problem and we also emphasize the necessity of a better access to health assistance. The small number of otolaryngologists in the region contributes to the complications related to the foreign bodies long stay and submit the children to the risk of non-specialized management.

Conclusion: We suggest new studies about this motif. The population should early recognize the symptoms related to the foreign bodies to begin the search for specialized assistance. The health authorities of the region, in turn, shall establish efficient measures for the otolaryngologic emergency care.

Keywords: Foreign Bodies; Otolaryngologic Emergency; Pediatric Patients

Introduction

Foreign Bodies (FB) of airways are commonly seen in the emergency department for all patient's age. The children cause important part of these emergency cases because the first years of life are long phase of interaction with the world, exploration and discovery [1,2]. Also, the insertion of a FB may be consequence of playing, hygiene or itching. Accidental entry is possible too [3]. Some

FB can be lifethreatening by displacement to airways or can lead to severe complications related to its long permanence. We detach the need for public health measures about this question and also the responsibility of parents and caregivers to prevent these events [1]. Information about these cases of FB can help the academic community to understand this question and provide effective measures.

Objective

To analyze cases of foreign bodies of otorhinolaryngological sites in children attended at an emergency hospital in the city of São Luís, Brazil.

Methods

Data collection from medical records of 105 children aged 0 to 12 years attended by otolaryngologists in the largest public emergency hospital in the city of São Luís, Maranhão, Brazil, from March 1st to April 30th 2016. We considered these information: age, sex, type of foreign body, site of insertion and time between the insertion and the removal of the foreign body.

Results

The children's mean age was 4.2 years. There was no difference between male (50.5%) and female (49.5%) sex. As shown in Figure 1, 57.2% of the cases were nasal cavities' FB, being 41% in the right cavity and 16.2% in the left one, and 41.9% were ears' FB, being 28.6% in the right ear and 13.3% in the left one. Only one case (1%) was of right tonsil's foreign body.

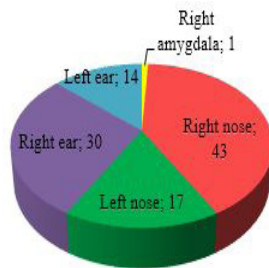

Figure 1: Patients distribution according to foreign bodies' site.

The types of foreign bodies are listed on (Table 1). We grouped the toy parts and plastic beads in "Plastics". We defined screws, bolt nuts and earrings as "Metallic". In the category "others" are pencil tips, cotton, paper, stone, plants and mass modeling, mainly. We excluded beans from the "Seeds" category, grouping them into their own category.

Material	Frequency	%
Bean	18	17,14%

Plastics	18	17,14%
Seeds	16	15,24%
Metallic	8	7,62%
School rubber fragment	4	3,81%
Sponge	3	2,86%
Wrist watch battery	1	0,95%
Tooth	1	0,95%
Fishbone	1	0,95%
Insect	1	0,95%
Naphthalene	1	0,95%
Unidentified	8	7,62%
Others	25	23,81%
Total	105	100,0%

Table 1: Type of foreign bodies.

The time intervals between the insertion of the foreign body and its removal are shown in (Figure 2). In two cases, this information didn't exist. The mean value was of 32.4 days.

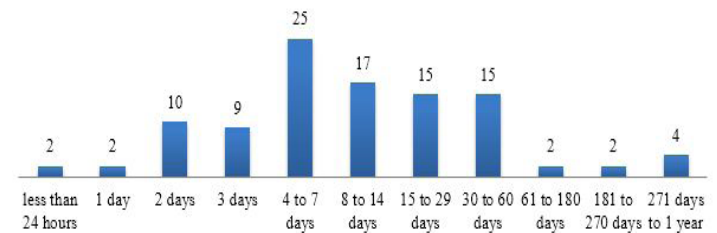


Figure 2: Time intervals between the insertion of the foreign body and its removal.

The (Table 2) shows the relationship between the various types of foreign bodies and the time interval between its insertion and removal.

	Indeterminate	<24 hours	1 day	2 days	3 days	4 to 7 days	8 to 14 days	15 to 29 days	30 to 60 days	61 to 180 days	181 to 270 days	271 days to 1 year	TOTAL
Bean	1		1	2		3	4	4	3				18
Plastics	1	1		3	2	5	2	2		1	1		18
Seeds				2	2	2	3	3	4				16
Metallic				1	2	2	2	1					8
School rubber fragment		1			1	1			1				4
Sponge									1	1		1	3
Wrist watch battery								1					1
Tooth						1							1

Fishbone				1									1
Insect						1							1
Naphthalene						1							1
Others			1		1	7	4	4	4		1	3	25
Unidentified				1	1	2	2		2				8
TOTAL	2	2	2	10	9	25	17	15	15	2	2	4	105

Discussion

The FB can be naturally eliminated from the nose and the throat because of physiological mechanisms of elimination, like sneezing, cough and vomit. As outcome, the FB in ear are the more frequent, according to some authors [4]. However, the FB from nasal cavities were the most prevalent of our study (57,2% of the cases). In nasal cavities, literature raise the prevalence of FB in right nostril [2,5]. Despite of others researchers disagree [5], they believe that it is consequence of the majority of population to be right-handed people [1,6]. This relationship is stronger to FB in ears, most accessible in the dominating side [5].

In our research, the most found type of FB was bean, followed by plastic artifacts and other seeds, confirming Figueiredo's research [4]. Most of these plastic objects came from breakable or disposable parts of children's toys [2]. We emphasize the responsibility of the toy industry and the governmental supervision that is responsible for this control. Besides these questions, it's also essential that parents and guardians supervise the kids during the use of these toys.

In a children, one battery was identified in right nostril (20 of permanency). This kind of FB needs particular attention, because the mechanisms of tissue injury concern yet electrical and chemistry burn, what can cause liquefied necrosis and lipids saponification [1,6]. Thus, the battery should be removed as soon as possible. Seeds can be developed in the humidity, for this reason, they should be quickly removed [7]. But, in our study, the permanency time ranged from two to fifty days. Besides this, the insertion of the FB is often not seen. Sometimes, the children can stay asymptomatic, what results in a long permanency of the FB and more medical complications [1].

The long permanency of FB is associated to less successful remotion and to higher complications rate [4,7], In this research, the interval between the insertion and removal of the FB was larger than in others studies [2,4,8]. Chinski et al showed that in only 4.2% of their 1559 cases attended at an emergency hospital in Buenos Aires the FB have stayed longer than 24 hours. In our series, there was the cases of four children with a FB for almost than one year [1].

We could not evaluate the complications of the BF because of the lack of this information in the patients' records. The nasal FB complications are: bronchial aspiration, epistaxis, nasal vestibulitis, rhinosinusitis and septal perforation [1,5,7]. Into the external auditory canal, the main complications are: external acoustic meatus laceration, external otitis, bruises, deafness, tympanic membrane perforation, ossicular chain destruction, chondritis leading to facial nerve palsy and mastoid impairment [3,4,7,6].

Although Brazilian laws ensures the right of everyone to health, access to these services remains one of the most serious problems in our society. The lack of a hierarchical and efficient structure, scarce resources and insufficient investments in health are important factors that justify the current situation [9]. In the case of FB and other medical emergencies, these failures can cost lives. However, such discussion is best suited in the governmental sphere than in the academic one. Maybe the greatest difficulty for patients in this study is obtaining specialist care. In this region under study, there is only one hospital in the capital that has emergency otorhinolaryngologic care, which is reflected in the long period of stay of the FB, causing great distress to the patients and their families. It should also be considered the attempt of removal of the FB by non-specialized professionals, as discussed by Figueiredo, et al. [4] and Fornazieri, et al. [3], which increases the rates of foreign body complications.

Conclusion

The pediatric patients with foreign bodies of ear, nose and throat in this city of Brazil are susceptible to the risks related to the long permanence of these objects because of the poor health system available.

We detach the responsibility of parentes and caregivers that should always keep attention to the access of schildren to small objects and also to suspect of the presence of foreign bodies at the firsts symptoms.

We suggest further studies that can evaluate the complications related to these foreign bodies. In turn, we keep increasing our data to contribute to the civil and academic societies.

References

1. Chinski A, Foltran F, Gregori D, Passali D, Bellussi L (2011) Nasal foreign body of the Buenos Aires pediatric otolaryngology clinic. *J Jpn Soc Pediatr* 53: 90-93.
2. Figueiredo RR, Azevedo AA, Kós AOA, Tomita S (2006) Corpos estranhos em fossas nasais: descrição de tipos e complicações em 420 casos. *Rev Bras Otorrinolaryngol* 72: 18-23.
3. Fornazieri MA, Cutolo D, Moreira JH, Navarro PL, Takemoto LE, et al. (2010) Corpo estranho em meato acústico externo: avaliação de 462 casos. *Arq Int Otorrinolaringol* 14: 45-49.
4. Figueiredo RR, Azevedo AA, Kós AOA, Tomita S (2008) Complicações de corpos estranhos em otorrinolaringologia: um estudo retrospectivo. *Rev Bras Otorrinolaringol* 74: 7-15.
5. Peridis S, Athanasopoulos I, Salamoura M, Parpounas K, Koudounakis E, et al. (2009) Foreign bodies of the ear and nose in children and its correlation with right or left handed children. *Int J Pediatr Otorhinolaryngol* 73: 205-208.
6. Gusmão RG, Bueno MC, Murad MP (1995) Bateria alcalina como Corpo estranho de ouvido: relato de 3 casos. *Bras J Otorhinolaryngol* 61: 79-81.
7. Tiago RSL, Salgado DC, Corrêa JP, Pio MRBP, Lambert EE (2006) Corpo estranho de orelha, nariz e orofaringe: experiência de um hospital terciário. *Rev Bras Otorrinolaringol* 72: 177-181.
8. Schulze SL, Kerschner J, Beste D (2002) Pediatric external auditory canal foreign bodies: a review of 698 cases. *Otolaryngol Head Neck Surg* 127: 73-78.
9. Sarmento Junior KMA, Tomita S, Kos AOA (2005) O problema da fila de espera para cirurgias otorrinolaringológicas em serviços públicos. *Rev Bras Otorrinolaringol* 71: 256-262.