

## Disseminated Therapy-Refractory Erythema Elevatum Diutinum with Paraproteinemia Treated with Intravenous Immunglobulins: A Case Report and Review of Literature

K Sawallich\*, Z Leitz, P von den Driesch

Center for Dermatology, Klinikum Stuttgart, Stuttgart, Germany

\*Corresponding author: K Sawallich, Center for Dermatology, Klinikum Stuttgart, Priessnitzweg 24, 70374 Stuttgart, Germany. Tel: +4977127851811; Email: k.sawallich@klinikum-stuttgart.de

**Citation:** Sawallich K, Leitz Z, von den Driesch P (2017) Disseminated Therapy-Refractory Erythema Elevatum Diutinum with Paraproteinemia Treated with Intravenous Immunglobulins: A Case Report and Review of Literature. Clin Exp Dermatol Ther 2017: G131.

**Received Date:** 3 July, 2017; **Accepted Date:** 20 July, 2017; **Published Date:** 27 July, 2017

### Abstract

**Background:** Erythema Elevatum Diutinum (EED) is a chronic form of leukocytoclastic vasculitis. A variety of underlying systemic diseases can be associated.

**Methods:** We report a rare case of widespread EED in association with paraproteinemia. A review of the available literature was performed. Therapy options are discussed.

**Results:** Biopsy revealed leukocytoclastic vasculitis. The patient with therapy-resistant EED was treated with dapsone, topical and systemic corticosteroids as well as intravenous immunoglobulins. Using this combined therapy, the patient experienced improvement of skin lesions and complete resolution of the pruritus. The systemic treatment was well tolerated.

**Conclusion:** Our patient demonstrates how far beyond the usual predilections sites an EED may occur. The underlying paraproteinemia maybe an underlying explanation for the severity seen in this case. The results of the combined treatment were nevertheless promising.

### Introduction

Erythema Elevatum Diutinum (EED) is a rare chronic vasculitis that effects young and middle-aged adults between the ages of 30 and 60 years and consists of papules, plaques or nodules. Common locations are the extensor surfaces of extremities [1,2].

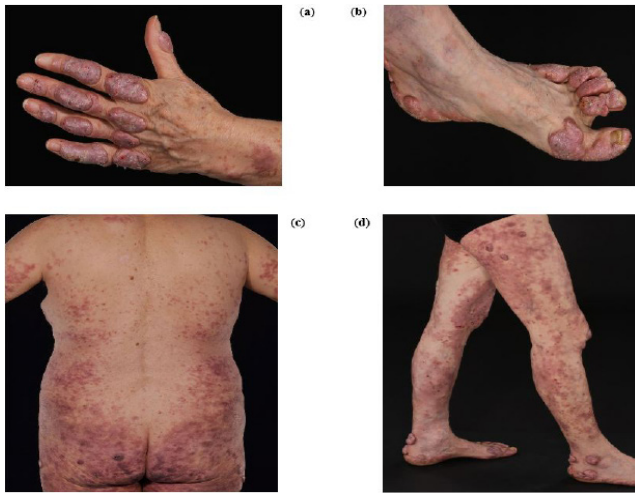The standard therapy consists of dapsone as the mainstay of treatment [3-6]. Furthermore, topical or systemic corticosteroids are reported to be effective [4,7]. Other options are nicotinamid or antibiotics such as clarithromycin, erythromycin or penicillin in combination with dapsone [8-9]. We report on the successful treatment of EED with intravenous immunoglobulins in combination with dapsone and systemic corticosteroids which previously had

failed to control the disease as individual therapies. We provide a short review of the current literature on the known role of underlying systemic diseases and dapsone as the treatment of choice for EED. Additionally, we highlight the role of intravenous immunoglobulins used in combination with dapsone.

### Case

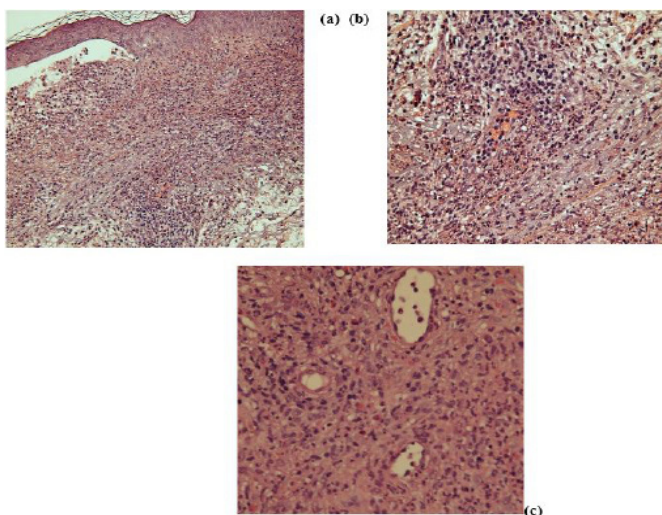
A 74-year old female patient was referred to our department with erythematous plaques and nodules which occurred on the extensor surfaces of feet, knees, elbows and fingers as well as erythematous macules on the trunk and extremities for at least 2 years (Figure 1 a/b/c/d). The patient reported that the skin lesions initially appeared on her feet. Past medical history included breast

cancer (high grade ductal carcinoma-in-situ), intraductal papillary-mucin neoplasia of the pancreas and recurrent pneumonia.



**Figure 1:** Clinical presentation of the patient before systemic therapy with topical and systemic steroid and intravenous immunoglobulin. Lesions are present on hand and feet. (a) Plaques on the extensor surfaces of the hands and fingers. (b) Large plaques and fibrosing nodules, distributed symmetrically on the extensor surfaces of feet. (c) Erythematous macules on the trunk. (d) Erythematous macules and nodules on the extremities.

A skin biopsy revealed a sub epidermal pustular bulla, chronic leukocytoclastic vasculitis, vascular wall necrosis and erythrocyte extravasates (Figure 2 a/b/c). Lymphocytes and eosinophils were present. Serological tests showed pathological serum immunofixation electrophoresis with IgA- and IgM-heavy-chains as well as free kappa and lambda light chains.



**Figure 2:** (a) A skin biopsy revealed a sub epidermal pustular bulla and chronic leukocytoclastic vasculitis. (b) Chronic leukocytoclastic vasculitis, vascular wall necrosis and erythrocyte extravasates. Lymphocytes and eosinophils were present. (c) Scattered eosinophils in the mixed perivascular cellular infiltrate.

In 2009 the patient commenced a therapy with dapsone (100 mg/day) and systemic prednisolone from the initial dose of 60 mg/day in addition to topical corticosteroids. She continued a therapy with dapsone (50 mg/day) and dose reduction of prednisolone 4 mg every week. Under this therapy regime, she achieved only a partial remission of the skin lesions and pruritus remained unresolved.

In 2015 the patient presented with a severe relapse of the EED despite continuous treatment. We initiated therapy with oral Nicotinamid, 200 mg 1/day, for 3 months as well as intra-lesional corticosteroid injections (triamcinolone acetonide, 10 mg) and cryotherapy every two weeks.

No positive effects were seen after three months, hence treatment with intravenous immunoglobulins (1 mg/kg bodyweight/day i.v.) over 6 days every 8 weeks was introduced. The patient received three treatment cycles which were well tolerated. No obvious side-effects could be noted. All lesions softened and flattened and the pruritus resolved. Response to this treatment was highly encouraging.

Peripheral blood cell counts showed abnormal results at the beginning of treatment (Hb 11,9 g/dl) (normal 12,0-16,0 g/dl). After combined treatment with dapsone and intravenous immunoglobulins Hb and Hkt showed normal results (Hb 13,9 g/dl (normal 12,0-16,0 g/dl) and Hkt 43,7 % (normal 35-45 %)). Platelet count was 422 T/ $\mu$ l (normal 150-350 T/ $\mu$ l) before combined therapy and 370 T/ $\mu$ l (normal 150-350 T/ $\mu$ l) after combined therapy. The White Blood Cell (WBC) was 3,69 T/ $\mu$ l (normal 4,00-10,00 T/ $\mu$ l) at the beginning and increased to 8,93 T/ $\mu$ l (normal 4,00-10,00 T/ $\mu$ l) after the combined therapy.

Prior to treatment with dapsone there was abnormal value in the serum chemistry including CRP. CRP reduced from 1,2 to 0,4 mg/dl (normal <0,5 mg/dl) after combined therapy with intravenous immunoglobulins. Creatinine and liver enzymes were within normal ranges before and after therapy (creatinine 0,8 mg/dl (normal 0,5-0,9 mg/dl), AST (GOT) 22 U/l (normal < 31 U/l), ALT (GPT) 21 U/l (<34 U/l), GGT 17 U/l (normal < 38 U/l).

Values of serum IgA, IgM showed improvement after therapy. Before therapy serum electrophoresis was pathological. Serum immunofixation revealed (IgA- and IgM-heavy-chains as well as free kappa and lambda light chains). After combined therapy serum electrophoresis did not show any pathological values.

## Discussion and Review of Literature

EED is a chronic skin disorder characterized by plaques and nodules, distributed symmetrically on the extensor surfaces [1-2,4,10]. Similar to our case report EED is most frequently found on acral and periarticular skin (Figure 1 a/b). EED belongs to a group of diseases which are called reactive neutrophilic dermatoses [11].

Associated conditions are autoimmune disorders such as chronic bowel disease [12], rheumatoid arthritis [13], SLE, Sjögren and Sarcoidosis. Reactive neutrophilic dermatoses may also occur in association with autoinflammatory syndromes. Examples of disorders that have been linked to reactive neutrophilic dermatoses in the literature include infections [6] (e.g. streptococcal [14], yersiniosal, mycoplasmic, cysticercosis, ureaplasmic), hematological diseases (e.g. leukemia, lymphoma [15], paraproteinemia [16,17]), pregnancy, solid malignant tumours and rarely drugs.

To our knowledge, this case seems to be the first case of EED, which shows such widespread lesions especially on the extremities. Our case demonstrates, how far beyond the usual predilection sites an EED may occur. The literature review revealed some cases of erythema elevatum diutinum associated with paraproteinemia [16,17]. We believe that this chronic association with IgA paraproteinemia has led to the severe extent of the disease in our case.

EED exhibits histopathologic leukocytoclastic vasculitis [10] as also seen in our case. Therapeutically, dapsone is considered to be first choice for EED in the literature [3-6] and was partially successful in our case but could not control the severe relapse after several years of treatment. Neither did nicotinamid or antibiotics in combination with dapsone [8-9]. We decided to use intravenous immunoglobulins additionally, which produced the best therapy effect in our patient. Our literature search revealed another case report which highlighted the dramatic effect of IVIG in cutaneous leukocytoclastic vasculitis [18].

Intravenous Immunoglobulin (IVIG) is standard first-line therapy for Kawasaki Disease (KD) which is a medium-size-artery vasculitis [19]. Recently, a European S1 consensus guideline encouraged the use of intravenous immunoglobulin for second line use of cutaneous vasculitis [20]. In conclusion, we believe that dapsone remains the treatment of choice for EED however, in therapy-resistant cases new therapy options should be considered. The use of intravenous immunoglobulins presents as an option for severe therapy resistant forms of the disease. Randomized studies regarding this, however, would be of great interest and are necessary to underline the possible therapeutical effect.

## References

1. High WA, Hoang MP, Stevens K, Cockerell CJ (2003) Late-stage nodular erythema elevatum diutinum. *J Am Acad Dermatol* 49: 764-767.
2. Yiannias JA, el-Azhary RA, Gibson LE (1992) Erythema elevatum diutinum: a clinical and histopathologic study of 13 patients. *J Am Acad Dermatol* 26: 38-44.
3. Grabbe J, Haas N, Möller A, Henz BM (2000) Erythema elevatum diutinum-evidence for disease-dependent leucocyte alterations and response to dapsone. *Br J Dermatol* 143: 415-420.
4. Momen SE, Jorizzo J, Al-Niimi F (2014) Erythema elevatum diutinum: a review of presentation and treatment. *J Eur Acad Dermatol Venereol* 28: 1594-1602.
5. Dronda F, González-López A, Lecona M, Barros C (1996) Erythema elevatum diutinum in human immunodeficiency virus-infected patients-report of a case and review of the literature. *Clin Exp Dermatol* 21: 222-225.
6. Rover PA, Bittencourt C, Discacciati MP, Zaniboni MC, Arruda LH, et al. (2005) Erythema elevatum diutinum as a first clinical manifestation for diagnosing HIV infection: case history. *Sao Paulo Med J* 123: 201-203.
7. Gibson LE, el-Azhary RA (2000) Erythema elevatum diutinum. *Clin Dermatol* 18: 295-299.
8. Muratori S, Carrera C, Gorani A, Alessi E (1999) Erythema elevatum diutinum and HIV infection: a report of five cases. *Br J Dermatol* 141: 335-338.
9. Pérez-Bernal A, Moreno-Giménez JC, Sotillo-Gago I, Camacho-Martínez F (1983) Erythema elevatum et diutinum treated with nicotinamide and tetracyclines. *Med Cutan Ibero Lat Am* 11: 51-53.
10. Ziemer M, Koehler MJ, Weyer W (2011) Erythema elevatum diutinum-a chronic leucocytoclastic vasculitis microscopically indistinguishable from granuloma faciale? *J Cutan Pathol* 38: 876-883.
11. Wallach D (2005) Neutrophilic dermatoses. *Rev Med Interne* 26: 41-53.
12. Walker KD, Badame AJ (1990) Erythema elevatum diutinum in a patient with Crohn's disease. *J Am Acad Dermatol* 22: 948-952.
13. Nakajima H, Ikeda M, Yamamoto Y, Kodama H (1999) Erythema elevatum diutinum complicated by rheumatoid arthritis. *J Dermatol* 26: 452-456.
14. Cream JJ, Levene GM, Calnan CD (1971) Erythema elevatum diutinum: an unusual reaction to streptococcal antigen and response to dapsone. *Br J Dermatol* 84: 393-399.
15. Futei Y, Konohana I (2000) A case of erythema elevatum diutinum associated with B-cell lymphoma: a rare distribution involving palms, soles and nails. *Br J Dermatol* 142: 116-119.
16. Chow RK, Benny WB, Coupe RL, Dodd WA, Ongley RC (1996) Erythema elevatum diutinum associated with IgA paraproteinemia successfully controlled with intermittent plasma exchange. *Arch Dermatol* 132: 1360-1364.
17. Thomas CL, Folkes L, Akhras V (2015) A case of mistaken identity: unilateral erythema elevatum diutinum associated with IgA paraproteinemia. *Clin Exp Dermatol* 40: 761-764.
18. Ong CS, Benson EM (2000) Successful treatment of chronic leukocytoclastic vasculitis and persistent ulceration with intravenous immunoglobulin. *Br J Dermatol* 143: 447-449.
19. Shulman ST (2017) Intravenous Immunoglobulin for the Treatment of Kawasaki Disease. *Pediatr Ann* 46: 25-28.
20. Enk A, Hadaschik E, Eming R, Fierbeck G, French L, et al. (2017) Europäische Leitlinien (S1) für die Anwendung von hochdosierten intravenösen Immunglobulinen in der Dermatologie. *J Dtsch Dermatol Ges* 15: 227-238.