

Case Report

Rangasamy K, et al. J Orthop Res Ther 2017; J124.

Multi Segment Upper Thoracic Fracture With Kyphoscoliotic Deformity Without Neurological Deficit-A Case Report

Krishnakumar Rangasamy*, Phanikiran S, Karunakaran S

Department of Spine Surgeon, Gleneagles Global Health City, Chennai, India

Corresponding author: Krishnakumar Rangasamy, Post Doctoral Fellowship In Spine Surgery, Consultant Spine Surgeon, Gleneagles Global Health City, Chennai, india. E-Mail: krishnaorth@gmail.com

Citation: Rangasamy K, Phanikiran S, Karunakaran S (2017) Multi Segment Upper Thoracic Fracture With Kyphoscoliotic Deformity Without Neurological Deficit-A Case Report. J Orthop Res Ther 2017; J124.

Received Date: 29 November, 2016; **Accepted Date:** : 03 February, 2017; **Published Date:** 10 February, 2017

Abstract

In Spinal trauma thoracolumbar fractures are common. Spinal cord is more vulnerable in upper thoracic spine. Hence minor degree of increased kyphosis or translation will lead to spinal cord injury and neurological damage. In literatures few cases were reported with one or two segments involvement without neurological deficit. Here we are reporting a 19 years old male with multi segment unstable upper thoracic vertebral fracture involving from T4 to T8 with kyphoscoliotic deformity without neurological deficit and underwent posterior stabilization procedure.

Introduction

In Spinal trauma thoracolumbar fractures are common and most of the complete neurological deficit occurs in thoracic fractures compare with cervical and lumbar fractures [1]. Thoracic vertebral column is divided into two region as upper thoracic [T1-T10] and thoraco lumbar[T10-L2]. Upper thoracic vertebral region is peculiar regarding anatomy and stability. Upper thoracic region is stronger construct than other region due to ribcage and costovertebral joints. These structures give 30% rigidity to upper thoracic region than other region [2,3].

Spinal cord is more vulnerable in upper thoracic spine due to smaller diameter of spinal canal and poor blood circulation to the cord in this region [4,5]. Hence minor degree of increased kyphosis or translation will lead to spinal cord injury and neurological damage.

Thoracic vertebral fractures without neurological deficit is rare. In literatures few cases were reported [6-22]. In all these cases pedicle and lamina fractures were reported and one or two segments involvement was present. Here we report a case with multi segment upper thoracic fracture without neurological deficit.

Case Report

19year old male had road traffic accident while he riding a bike ,bike was hit by a car. Patient was shifted to our institute on spine board. On examination patient complaining of pain upper back and right shoulder, GCS was 15 , haemodynamically stable

and no neurological deficit. Radiological investigations revealed that patient had un displaced fracture clavicle on right side, comminuted scapula fracture on right side, haemo pneumo thorax in right side chest with no rib fracture and multiple vertebral fractures. Patient had right side transverse process fracture at C6 level , spinous process fracture at C7 level , right side pedicle ,spinous process and body fracture at T4 level, bilateral pedicles fracture at T5 level , bilateral pedicle fracture and body fracture at T6 level, T7 and T8 vertebral body fractures with kyphoscoliotic deformity in upper thoracic spine and L1 transverse fracture on both side. MR shows no spinal cord damage (Figure 1).

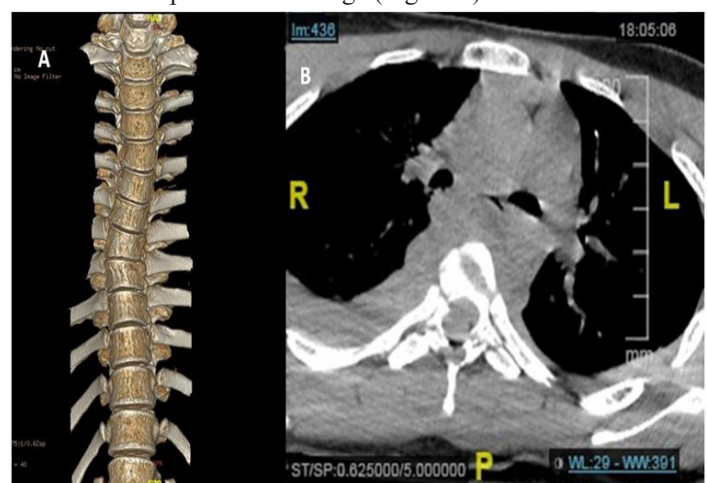


Figure 1: CT images: A. Kyphoscoliotic deformity. B. Bilateral pedicle fracture and body fracture seen at T6 level.

Patient was completely evaluated for surgical procedure. Intercostal drain was put in right side chest. Patient was carefully positioned in prone position after anaesthesia with adequate support and padding. Through mid line incision T1 to T10 were exposed. Pedicle screw fixation was done T2,3 and T7,8,9 levels. There was loose fragments at T4 level due to lamina fracture which were removed and cord found to be normal and no obvious CSF leak.

Pedicle screws connected with contoured rods both sides. Wound closed in layers with drain. On third postoperative day there was a CSF leak in the drain so CSF drain was inserted at lumbar level and bed rest with head down position was advised. Inter costal drain was removed on fifth postoperative day. Wound drain was removed on sixth postoperative day and lumbar drain was removed on seventh postoperative day. Patient mobilized with TLO brace. Patient returned to his regular works in six weeks time and advised no strenuous activities for six months.

Discussion

Thoracic vertebral column is stiffer than other region need high energy trauma to produce fractures in normal adult. Most of these injuries are due to road traffic accidents and usually associated with other injuries. Upper thoracic spine fractures are prone for neurological damage due to smaller osseous ring and sparse blood supply to the spinal cord in the thoracic region.

Hyperextension injuries will cause the pedicle fractures which will separate the posterior arch from the remaining vertebral column and further compression will cause the failure of anterior and posterior columns. These complex hyperextension axial compression mechanisms are described in the various literature [14,15,23,24,25].

Auto decompression of spinal canal is the mechanism for preventing the neurological damage in these cases. Fractures of the pedicles and lamina are widening the spinal canal and anterior and middle column moving independently without moving the spinal cord (Figure 2).

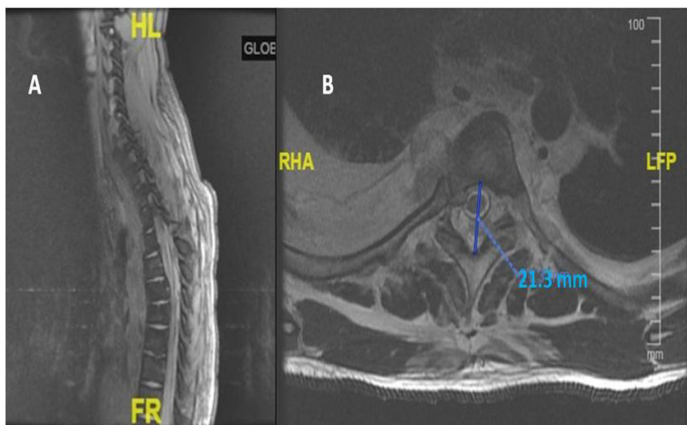


Figure 2: Auto decompression due to fractures at T4 T5 and T6 level: A. MR Sagittal Section. B. MR Axial cut at T6 level.

Considering the unstable nature of the spinal column and to prevent the complications of conservative method like prolonged bed rest, failure of fusion, significant residual or progressive spinal deformity, chronic pain we decided to do internal fixation for this patient (Figure 3).

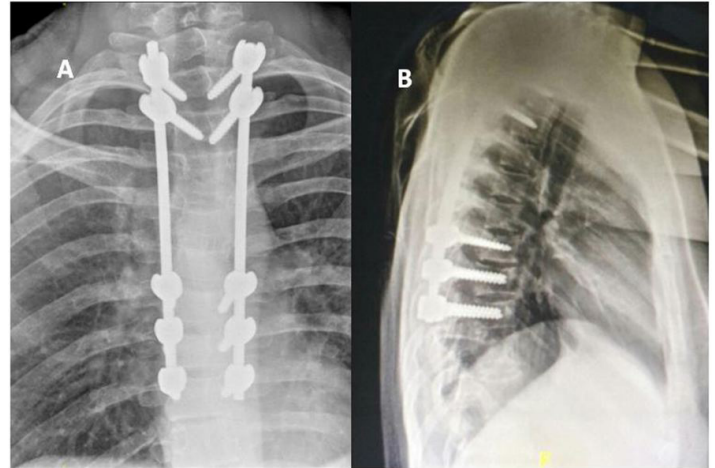


Figure 3: Postoperative radiographs: A. Antero posterior view. B. Lateral view.

Conclusion

Multi segment upper thoracic vertebral fractures without neurological deficit is very rare. Auto decompression due to pedicle fractures is the important mechanism for preventing neurological deficit. Internal fixation of the spine facilitating early return to regular activities.

References

1. Wang H, Zhang Y, Xiang Q, Wang X, Li C, et al (2012) Epidemiology of traumatic spinal fractures: Experience from medical university-affiliated hospitals in Chongqing, China, 2001-2010. *J Neurosurg Spine* 17: 459-68.
2. Morita D, Yukawa Y, Nakashima H, Ito K, Yoshida G, et al (2014) Range of motion of thoracic spine in sagittal plane. *Eur Spine J* 23: 673-678.
3. Mannen, Erin, Anderson, John, Arnold, Paul (2015) Integrity of damage control posterior spinal fusion constructs for polytrauma patients: A biomechanical investigation. *Spine* 40: E760-E766.
4. Luiz Roberto Vialle and Emiliano Vialle (2005) Thoracic spine fractures Injury. *Injury Int. J. Care Injured* 36: S65-S72.
5. Anthes TB, Muangman N, Bulger E, Eric JS (2012) Upper Thoracic Spine Fracture Dislocation in a Motorcyclist. *Current Problems in Diagnostic Radiology* 41: 128-129
6. Enishi T, Katoh S, Sogo T (2014) Surgical Treatment for Significant Fracturedislocation of the Thoracic or Lumbar Spine without Neurological Deficit: A Case Series. *J orthop case report* 4: 43-45.
7. Gertzbein SD and Offierski C (1979) Complete fracture-dislocation of the thoracic spine without spinal cord injury. A case report. *J Bone Joint Surg Am* 61: 449-451.

-
8. Vichard P, de la Salle R, Tropet Y, Runge M (1983) Complete fracture-dislocation of thoracic vertebrae 8 and 9 without neurological complications. Description of the injury. Therapeutic deductions. *Rev Chir Orthop* 69: 645-648.
 9. Weber S and Sutherland G (1986) An unusual rotational fracture-dislocation of the thoracic spine without neurologic sequelae internally fixed with a combined anterior and posterior approach. *J Trauma* 26: 474-479.
 10. Harryman DT (1986) Complete fracture-dislocation of the thoracic spine associated with spontaneous neurologic decompression. A case report. *Clin Orthop Relat Res* 1986: 64-69.
 11. Sasson A and Mozes G (1987) Complete fracture-dislocation of the thoracic spine without neurologic deficit. A case report. *Spine (Phila Pa 1976)* 12: 67-70.
 12. Uriarte E, Elguezabal B, Tovio R (1987) Fracture-dislocation of the thoracic spine without neurologic lesion. *Clin Orthop Relat Res* 1987: 261-265.
 13. Simpson AH, Williamson DM, Golding SJ, Houghton GR (1990) Thoracic spine translocation without cord injury. *J Bone Joint Surg Br* 72: 80-83.
 14. Krallis P, Psicharis P, Dendrinis G (1992) Fracture-dislocation of the dorsal spine with severe displacement without neurologic impairment: Case presentation and literature review. *Acta Orthop Belg* 58: 84-87.
 15. Miyasaka Y, Satomi K, Sugihara S, Tahara Y, Hayashi T, et al. (1993) Posterior fracture-dislocation of the thoracic spine without neurological deficit. A case report and short literature review. *Spine* 18: 2351-2354.
 16. de Lucas JC, Alvarez L, Abril JC, Calvo E (1994) Fracture-dislocation of the thoracic spine without neurological lesion. *Injury* 25: 105-107.
 17. Korovessis P, Sidiropoulos P, Dimas A (1994) Complete fracture-dislocation of the thoracic spine without neurologic deficit: case report. *J Trauma* 36: 122-124.
 18. Liljenqvist U, Halm H, Castro WH, Mommsen U (1995) Thoracic fracture-dislocations without spinal cord injury: a case report and literature review. *Eur Spine J* 4: 252-256.
 19. Potter MJ, Little C, Wilson-MacDonald J (2003) Thoracic fracture dislocations without vertebral clinical signs. *Injury* 34: 942-943.
 20. Shapiro S, Abel T, Rodgers RB (2002) Traumatic thoracic spinal fracture dislocation with minimal or no cord injury. Report of four cases and review of the literature. *J Neurosurg* 96: 333-337.
 21. De Lure F, Fravisini M, Boriani S (2005) Case report of complete dislocation of T1-T2 without neurological deficit and review of the literature. *Injury extra* 36: 503-507.
 22. Jiang B, Zhu R, Cao Q, Pan H (2014) Severe thoracic spinal fracture dislocation without neurological symptoms and costal fractures: a case report and review of the literature. *J Med Case Rep* 8: 343.
 23. Hanley E and Eskay M (1989) Thoracic spine fractures. *Orthopedics* 12: 689-696.
 24. Jacobs R (1977) Bilateral fracture of the pedicles through the fourth and fifth lumbar vertebrae with anterior displacement of the vertebral bodies. A case report. *J. Bone Joint Surg* 59: 409-410.
 25. London PS (1993) Fracture-dislocations of the spine that may spare the cord: an explanation. *Injury* 24: 347-349.