

Review Article

Different Treatment Modalities in Diabetic Macular Edema Refractory to Intravitreal Bevacizumab: A Review Article

Shahin Faghihi, Fariba Ghassemi, Fatemeh Abdi, Mandana Esfahani, Hooshang Faghihi*

Eye Research Center, Farabi Eye Hospital, Tehran University of Medical Sciences, Tehran, Iran

*Corresponding author: Hooshang Faghihi, Eye Research Center, Farabi Eye Hospital, Tehran University of Medical Sciences, Tehran, Iran. Tel: +(+98 21) 8897 0821; E-Mail: faghihih@hotmail.com

Citation: Faghihi S, Ghassemi F, Abdi F, Esfahani M, Faghihi H (2017) Different Treatment Modalities in Diabetic Macular Edema Refractory to Intravitreal Bevacizumab: A Review Article. *Ophthalmol Res Rep* 2017: J122.

Received Date: 25 May, 2017; **Accepted Date:** 31 May, 2017; **Published Date:** 7 June, 2017

Abstract

Background: Diabetic Macular Edema (DME) is a leading cause of vision loss in diabetic population worldwide. Despite laser therapy had been standard treatment in DME for years, nowadays Anti-VEGF agents have become first line therapy. Although the use of Bevacizumab is still off-label, its low cost and availability, consistent with its similar therapeutic effects to other Anti-VEGF agents, make it first line therapy in DME in most countries. Recently, refractory cases to multiple IVB injections have emerged. In this study, we aimed to review the literature for other treatment modalities in such patients.

Conclusions: Different treatment strategies have been suggested to be beneficial in refractory cases; such as intravitreal triamcinolone, switch to other Anti-VEGF agents, higher dose of Anti-VEGF agents, and combination of triamcinolone and Anti-VEGFs. Each treatment modality can be beneficial in selected patients. Despite favorable reports on the efficacy of these treatment strategies, we still require the results of large, controlled trials to elucidate the ideal therapeutic approach in each patient.

Keywords: Anti Vascular Endothelial Growth Factor (Anti-VEGF); Chronic DME; Intravitreal Bevacizumab (IVB); Long-standing DME; Persistent DME; Recalcitrant DME; Refractory Diabetic Macular Edema

Introduction

The leading cause of visual disturbance in diabetic retinopathy patients is Diabetic Macular Edema (DME) [1,2]. Although laser photocoagulation is the standard treatment for DME [3-5], its side effects for the treatment of severe retinopathy in the form of Pan Retinal Photocoagulation (PRP) are well known [6-9]. Anti-Vascular Endothelial Growth Factor (anti-VEGF) therapy has recently gained credit as the first-line treatment for DME because numerous trials have revealed its beneficial outcomes [10-14]. Despite these remarkable effects, not all DME patients are responsive to anti-VEGF therapy. Bevacizumab (Avastin, Genentech, San Francisco, California) is a humanized recombinant antibody that binds all isoforms of VEGF [15]. The drug had received Food and Drug Administration's approval for the treatment of metastatic colorectal cancer [16]. Although Bevacizumab is being used off label, its low cost and availability, consistent with its similar therapeutic effects to other Anti-VEGF agents, make it first line therapy for DME in most countries.

Newer treatment modalities are under investigation for DME refractory to anti-VEGFs. Our ambition in this study is to review different therapeutic options in DME patients, refractory to IVB treatment.

Materials and Methods

All studies who evaluated treatment options in refractory DME to multiple IVB injections were included. We searched both Pub Med and Cochrane database without time limit. The keywords we used were: Refractory DME, IVB injections, DME refractory to IVB. We first searched the database in September 2016, and repeated it again in November 2016. We excluded all studies with treatment modalities other than bevacizumab injection or combination of IVB with other treatment strategies. Twenty-seven articles were reviewed and only three of them met the inclusion criteria.

Results

Nourinia et al studied 15 eyes of 15 patients with the following inclusion criteria: presence of type 2 diabetes mellitus and DME with no CMT reduction or VA improvement after one or

more IVB injections, BCVA \leq 20/40 and severe DME defined as CMT more than 320 μ m associated with large cystoids changes and/or neuro sensory detachment [17]. Kim, et al. defined DME as refractory to IVB if either of the following conditions were met:

- CST did not decrease by more than 30 μ m after \geq 3 consecutive IVB injections.
- CST increased after 1 to 2 IVB injections [18].

Fasudil has improved understanding of the pathophysiology of diabetic retinopathy and has facilitated the development of new drugs for treatment of DME in cases refractory to current therapies. In addition to the previously known high VEGF levels, increased activity of the Rho/Rock pathway has recently been demonstrated in diabetic patients. This pathway promotes leukocyte adhesion to the retinal vascular endothelium by increasing Intercellular Adhesion Molecule 1 (ICAM-1) expression and stimulating Myosin Regulatory Light Chain (MLC) phosphorylation [19]. Furthermore, increased activity of the Rho/Rock pathway inactivates endothelial Nitric Oxide Synthases (eNOS), thereby reducing physiological levels of Nitric Oxide (NO), a potent vasodilator and anti-apoptotic factor. Therefore, retinal endothelial cell damage occurs as a result of leukocyte adhesion and decreased eNOS activity [18]. Experimental studies have demonstrated that Fasudil (Asahi Kasei Pharma Corporation, Tokyo, Japan) as a potent ROCK inhibitor can suppress leukocyte adhesion and prevent neutrophil-induced retinal endothelial cell damage [20]. Exclusion criteria were active proliferative diabetic retinopathy, mono clarity or VA of fellow eye $<$ 20/40, other macular disorders, intravitreal bevacizumab injection within the past 3 months, and ocular surgery

over the past 6 months. All patients received IVB (1.25 mg/0.05 ml) and intravitreal Fasudil injection (0.025 mg/0.05ml) using two separate syringes and at two separate sites followed by anterior chamber paracentesis. Best-Corrected Visual Acuity (BCVA) was measured and Optical Coherence Tomography (OCT) images were obtained before and one month after the injections. Mean age of the patients was 64.6 ± 7.3 (range, 49-79) years and the mean number of previous IVB injections was 2.8. Mean BCVA was 0.84 ± 0.35 logMAR before intervention improving to 0.49 ± 0.29 log MAR four weeks after treatment ($P = 0.003$). Mean pre-injection CMT was $448 \pm 123\mu$ m decreasing to $347 \pm 76\mu$ m four weeks after treatment ($P = 0.001$) (Table 1 and Figure 1). No adverse effects such as intraocular inflammation, vascular accident, and IOP rise were observed following intravitreal injection of Fasudil and bevacizumab.

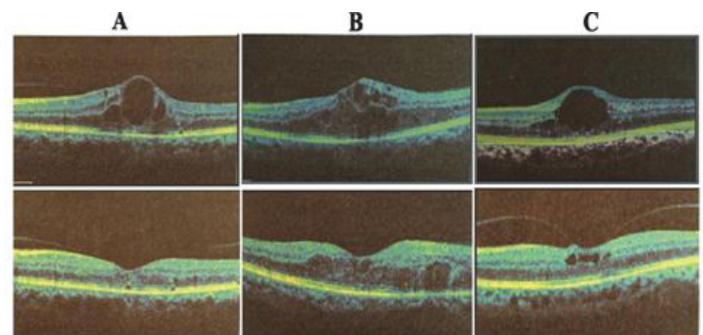


Figure 1. Optical coherence tomography images of three patients (A, B and C) show significant reduction of central macular thickness (CMT) one month after intravitreal injection of bevacizumab and Fasudil. CMT before treatment (top images) was 559, 516 and 455 μ m decreasing to 281, 344 and 330 μ m one month after treatment (lower images) in patients A, B and C, respectively.

Table 1. Number of previous intravitreal bevacizumab injections; best-corrected visual acuity and central macular thickness at baseline and 4 weeks after combined intravitreal injection of bevacizumab and Fasudil

No	Age (years)	Sex	Eye	Hx MPC	Hx IVB	BCVA Snellen (logMAR)			CMT (μ m)		
						Baseline	4 wk after treatment	Change (%)	Baseline	4 wk after treatment	Change (%)
1	63	M	OD	1	2	1/10 (1)	3/10 (0.52)	48	400	371	7
2	79	M	OS	1	3*	1/10 (1)	3/10 (0.52)	48	367	344	6
3	59	M	OS	1	2	4/10 (0.4)	8/10 (0.1)	75	372	291	22
4	64	F	OS	1	3	CF 3 (1.3)	CF 3 (1.3)	0	493	302	39
5	65	M	OS	1	7	CF 2 (1.5)	3/10 (0.52)	65	439	323	26
6	64	M	OD	1	2	1/10 (1)	6/10 (0.22)	78	516	344	33
7	61	M	OS	1	3	1/10 (1)	2/10 (0.7)	30	392	344	12
8	76	M	OS	1	3	3/10 (0.52)	7/10 (0.15)	71	358	330	8
9	49	M	OS	1	4	2/10 (0.7)	4/10 (0.4)	43	570	441	23
10	67	M	OS	1	4	4/10 (0.4)	4/10 (0.4)	0	324	327	-1
11	67	M	OS	1	1	3/10 (0.52)	3/10 (0.52)	0	559	281	50
12	70	M	OD	1	1	3/10 (0.52)	3/10 (0.52)	0	784	581	26
13	63	F	OS	1	2	CF 4 (1.2)	2/10 (0.7)	42	455	330	27
14	56	F	OS	1	1	3/10 (0.52)	5/10 (0.3)	42	341	326	4
15	66	F	OD	1	5	1/10 (1)	3/10 (0.52)	48	344	275	20
Mean \pm SD						0.84 \pm 0.35	0.49 \pm 0.29	39 \pm 28	448 \pm 123	347 \pm 76	20 \pm 14
P-value for the change (Wilcoxon signed rank test)						0.003			0.001		

M, male; F, female; OD, right eye; OS, left eye; Hx, history of previous treatment; MPC, macular photocoagulation; IVB, intravitreal bevacizumab; BCVA, best-corrected visual acuity; CMT, central macular thickness; SD, standard deviation
*Also treated once by IVT

The short-term results of this case series showed that in DME refractory to IVB, combined intravitreal bevacizumab and Fasudil injection resulted in structural (CMT reduction) and functional (BCVA) improvement. These results are comparable or superior to other studies reporting intravitreal injection of bevacizumab, triamcinolone and sustained release dexamethasone in patients with refractory DME [1,3,4,10,11,15-18]. They used 0.025 mg Fasudil intravitreally to achieve an intraocular concentration of 10 μ M/L [21]. Previous animal studies have not shown any obvious electrophysiological or morphological toxicity up to a maximum concentration of 100 μ M/L [22]. ERG findings in their previous study [21] and comprehensive ocular examinations in the current study did not show any toxic effect associated with intravitreal Fasudil injection. The results of this study and their previous report on a smaller number of cases [21] demonstrate a possible beneficial effect from intravitreal injection of Fasudil in combination with IVB in patients with DME unresponsive to mono therapy with IVB. This combination may reduce retinal vessel hyper-permeability via simultaneous inhibition of VEGF activity and endothelial cell damage more effectively than intravitreal injection of an anti-VEGF alone.

Yu \ddot{u} ksel Totan, et al. performed a prospective, non-randomized study to evaluate a group of 30 patients unresponsive to regular intravitreal bevacizumab injections for diabetic macular edema. Inclusion criteria were age over 18 years, a Best-Corrected Visual Acuity (BCVA) between 1.0 and 0.3 (log MAR) and chronic resistant DME. They defined chronic DME as DME present for a period of 6 months or more with Central Foveal Thickness (CFT) greater than 275 microns as measured by Optical Coherence Tomography (OCT). They also defined chronic-resistant DME as chronic DME unresponsive (reduction of CFT less than 50 microns, or increase in CFT) to a minimum of three 2.5-mg intravitreal bevacizumab injections given 6 weeks apart before inclusion into the study. The exclusion criteria were a history of glaucoma, severe cataract, venous occlusions, epiretinal membrane visible by Optical Coherence Tomography (OCT), age-related macular degeneration, uveitis, history of cataract surgery (within the previous 6 months), YAG laser capsulotomy (within 2 months prior to the trial), previous vitrectomy, pan retinal or grid laser photocoagulation (within 3 months prior to investigation), and DME previously treated with intravitreal or peri ocular corticosteroids injection. Intravitreal dexamethasone implant (0.7-mg implant of dexamethasone, Ozurdex; Allergan, Inc, Irvine, CA) was administered intravitreally through the pars plane using the original implanting device.

After the administration, IOP and light perception were assessed. Complete ophthalmic examination, including IOP measurements was performed at first week, 1, 3, and 6 months. BCVA, CFT, and MCV measurements were performed at 1, 3, and 6 months. The main outcomes were the changes between the initial and follow up visits in the mean BCVA, CFT, MCV (Mean cube

volume), and IOP measures [19]. A total of 30 eyes of 30 patients (12 males, 18 females; mean age 61.3 \pm 7.3 years, range 47-76 years) with chronic resistant DME were included in the analysis. The mean duration of DME was 29.7 \pm 9.5 months (range 12-44 months), and the mean HbA1c value at baseline was 7.4% (mean 7.4 \pm 1.9). Of the 30 eyes, 12 had previous grid laser, 5 had scatter laser treatment. The average interval between the last intravitreal bevacizumab injection and dexamethasone implant application was 2 months (6 weeks to 3 months). The mean number of the intravitreal bevacizumab injections was 6.0 \pm 0.6. Preoperative and follow-up FFA showed no cases of macular or Para macular retinal ischemia.

Statistically significant change from baseline was observed in BCVA (at 1, 3 and 6 months), CFT (at 1, 3, and 6 months), MCV (at 1, 3, and 6 months), and IOP (at 1 week, 1 and 3 months). BCVA significantly ($p = 0.04$) decreased at 6 months (0.59 \pm 0.39 log MAR) compared to the mean BCVA at 3 months (0.44 \pm 0.28 log MAR) (Figure 1). At the 6 months visit, the mean CFT (411 \pm 126 mm, range 174-776 mm) ($p < 0.001$) was still significantly lower compared to the baseline value (517 \pm 136 mm, range 324-872 mm) ($p = 0.01$), but significantly increased compared to the mean CFT at 3 months (314 \pm 88 mm, range 186-758 mm). At the last visit, the mean MCV was significantly lower than baseline value (13.6 \pm 1.9 mm³) ($p < 0.001$). However, it was significantly increased to 12.1 \pm 1.9 mm³ ($p = 0.01$) compared to the mean MCV at 3 months (11.3 \pm 1.5 mm³). A recurrence of macular edema at 6 months was observed in a total of 25 eyes with CFT ranged from 321 mm to 800 mm and mean HbA1c value of 6.8%. Three of 25 eyes showed a CFT increase to a higher level than baseline (rebound effect) at the 6-month follow-up examination and were retreated with additional 2.5mg intravitreal bevacizumab. These 3 patients had HbA1c values of 6.3%, 6.9% and 8.3%. Thirteen of the remainder 22 eyes were retreated with 1.25mg of intravitreal ranibizumab, and 9 eyes with additional 2.5mg intravitreal bevacizumab.

The BCVA was not significantly correlated with CFT and MCV at 6-month follow up ($r = -0.10$, $p = 0.58$; $r = 0.29$, $p = 0.11$, respectively). IOP values were significantly higher at 1 week ($p = 0.01$), 1 month ($p = 0.01$) and 3 months ($p = 0.04$) compared to the baseline IOP. After 1 month, it was gradually decreased to the baseline value at 6 months. During the follow-up period, they found IOP higher than 21mmHg in 4 of 30 eyes (13.3%) (The maximum value was 32mmHg at 1 month). These eyes were treated and well-controlled with topicality-glaucoma mono therapy. No inflammation, infection, thromboembolic events, ocular toxicity, and cataract progression (based on the "Lens Opacities Classification System" III) were observed in any of the patients.

Min Woo Kim, et al. conducted a retrospective, nonrandomized, interventional study on patients who were diagnosed with DME between January 2011 and December 2012 at AS an Medical

Center. Patients with DME involving the fovea, a CST > 300 μ m, and who did not respond to IVB injection were included. They defined DME as refractory to IVB if either of the following conditions were met:

- CST did not decrease by more than 30 μ m after ≥ 3 consecutive IVB injections.
- CST increased after 1 to 2 IVB injections.

Exclusion criteria were:

- Age under 18 years.
- History of retinal vein occlusion, retinal arterial occlusion, uveitis, epi retinal membrane, or any chorioretinal disease other than diabetic retinopathy.
- Previous focal or grid laser treatment.
- Pan retinal photocoagulation treatment less than 3 months before the first IVB injection.
- Previous IVTA or stTA (sub tenon triamcinolone acetate) treatment.
- Suspected glaucoma (with a high cup to disc ratio, > 0.6) or diagnosis of glaucoma by a glaucoma specialist.
- Any kind of ocular surgery, including cataract surgery, within the last 6 months.

Posterior subtenon injections of triamcinolone (20 mg/0.5mL) were administered by a Single Retina Specialist (SGJ), all using the same protocol.

Patients were examined every 2 months after injection. Each patient's Best-Corrected Visual Acuity (BCVA), IOP, and CST were evaluated on the day of stTA injection and again at 2, 4, and 6 months. At each visit, lens status was evaluated to determine if the posterior sub capsular cataract was more advanced than PII (according to the Lens Opacities Classification System III). BCVA was assessed using a Snellen visual acuity chart, and IOP was measured using Goldmann perimetry. They prescribed Trusopt for prophylactic IOP control. Other related factors, such as duration of diabetes, glomerular filtration rate, and Hemoglobin A1c (HbA1c), were also assessed. CST was measured using spectral-domain optical coherence tomography (Spectralis; Heidelberg Engineering, Heidelberg, Germany). Macular edema patterns on OCT were classified according to the criteria previously reported by [23,24], including Sponge-Like Diffuse Retinal Thickening (SDRT), Cystoid Macular Edema (CME), serous retinal detachment, and a combination of all three edema types (FULL).

In total, 34 patients (40 eyes) met the inclusion criteria. Of these, 33 patients (36 eyes) received 2 months of follow-up examinations. Thirty-three patients received 4 months of follow-up examinations. One patient did not receive a spectral-domain opti-

cal coherence tomography examination. At 6 months, 31 patients (37 eyes) received all examinations. The baseline characteristics of the 34 patients are summarized here: the average patient age was 61.7 ± 9.19 years, and 21 of these patients were male. The mean baseline CST was $476 \pm 153\mu$ m (range, 300 to 988 μ m). Mean CST decreased to 368 μ m ($p < 0.001$, Wilcoxon signed-rank test) within 2 months of receiving stTA injection, then increased slightly to 374 μ m. It subsequently resumed its decreasing trend from baseline at 4 months ($p < 0.001$, Wilcoxon signed rank test). CST increased to 427 μ m by 6 months but was still lower than baseline ($p = 0.046$, Wilcoxon signed-rank test). Twenty-five eyes were diagnosed with SDRT, 12 eyes were diagnosed with CME, and three eyes were diagnosed with FULL. No cases were diagnosed as serous retinal detachment type. They did not identify any CST differences between the classified forms of macular edema at any of the time points. The effects of stTA, which were measured in terms of CST change at each follow-up OCT examination, did not indicate any differences between groups.

The mean initial BCVA was 0.55 on the log MAR scale. The BCVA improved to 0.50 at 2 months after stTA injection, remained at 0.50 after 4 months, and finally decreased to 0.48 by the 6 months' follow-up examination; only the value at 2 months represented a statistically significant change ($p = 0.023$, $p = 0.083$, and $p = 0.133$, respectively; Wilcoxon signed-rank test). The average IOP changed significantly from 15.50 mmHg at baseline to 16.92 mmHg at 2 months ($p = 0.040$, paired t-test). However, IOP did not change significantly at 4 months (16.30 mmHg, $p = 0.103$) or at 6 months (15.65 mmHg, $p = 0.732$, paired t-test). Three eyes from 37 eyes were administered another IOP-lowering drug. No eyes had an IOP > 21 mmHg during the entire follow-up period. Among all 40 eyes, 27 were phakic and 13 were pseudo phakic. They did not identify any cases of advanced cataract during the follow-up period (i.e., no eyes were > PII according to the Lens Opacities Classification System III classification). No other stTA-related complications were noted during the study period [18].

Conclusion

Nourinia et al pilot study, in summary, combined intravitreal injection of bevacizumab and Fasudil seems to entail a beneficial effect in terms of structural and functional outcomes in eyes with severe DME resistant to current therapeutic modalities. Studies with larger sample size and longer follow-up are required to establish the use of Fasudil for DME [17]. Study of Yuksel Totan et al, suggested that dexamethasone intravitreal implant may present a good alternative in the management of DME unresponsive to regular intravitreal anti-VEGF injections. They also have observed that its efficacy has remarkably been decreased between month 3 and 6 following administration [19]. Min Woo Kim et al, showed that stTA was associated with a lower rate of adverse events than previous study, like cataract progression or elevated IOP during the follow up period. In conclusion, stTA is an effective, safe, and

affordable treatment for reducing CST in DME refractory to IVB injection [18]. In summary, the study results suggest that continuation of anti-VEGF therapy after 24 weeks in eyes that have persistent DME may lead to long-term visual and anatomical improvement even in the setting of chronic persistent DME [20]. We excluded all studies on refractory DME with treatment modalities other than Bevacizumab or combination of Bevacizumab with other treatments:

In the study by Edward H. Wood, et al. DME patients with persistent retinal fluid despite regular (every 4 to 6 weeks) Intravitreal Injection (IVI) with ranibizumab 0.3 mg, and/or bevacizumab 1.25 mg were switched to IVI aflibercept 2 mg. A majority of patients with DME with persistent fluid on SD-OCT despite regular ranibizumab 0.3 mg and/or bevacizumab 1.25 mg IVI showed a positive anatomic response to IVI aflibercept 2 mg [21]. Weiye Li, et al, studied intravitreal injections of erythropoietin in eyes with severe, chronic diabetic macular edema, 5 eyes of 5 patients underwent injections of rHuEPO alpha (EPO) intravitreally every 6 weeks for three doses and followed for an additional 6 weeks. Visual acuity of all patients was subjectively improved by 3 or more lines in 3 eyes and 1 line in 2 eyes. Visual acuity improved to a larger extent than anatomic improvement by OCT [22].

Khalil Ghasemi Falavarjani, et al, evaluate the efficacy of intravitreal injection of 400µg Methotrexate (MTX) in patients with persistent Diabetic Macular Edema (DME) nonresponsive to at least three consecutive bevacizumab injections or two consecutive bevacizumab injections plus macular photocoagulation. In this study, intravitreal injection of MTX resulted in anatomical improvement in a significant proportion of eyes with persistent DME. Significant visual improvement was found in 16.6 % of eyes [25]. Maria C. Hernaez-Ortega, et al. investigated the effectiveness of a new prolonged lanreotide formulation in patients with bad controlled diabetes and persistent cystoid macular edema. Two patients treated with a subcutaneous injection of lanreotide Autogel (Somatuline1 Autogel, Ipsen Pharma SA, Spain) of 90 mg every 4 weeks were monitored before (at baseline) and after treatment (at 3, 6 and 12 months). This study revealed that monthly subcutaneous injections of lanreotide Autogel offered an effective treatment alternative in patients with persistent diabetic CME and poor glycemic control [26].

Jae Hyung Lee, et al, evaluated the efficacy of switching from at least 3 monthly bevacizumab to a single ranibizumab injection in patients with persistent fluid. Anatomic responders to ranibizumab were followed up monthly and administered ranibizumab injections on an as-needed basis for 3 months. The rate of patients who showed partial response to previous bevacizumab between anatomical responders and non responders to ranibizumab was compared. The results showed that the rate was significantly higher in the responder group than non responder group (76.9% vs. 43.5%, $P = 0.008$) [27].

References

1. Klein R, Klein BE, Moss SE, Davis MD, DeMets DL (1984) The Wisconsin epidemiologic study of diabetic retinopathy IV Diabetic macular edema. *Ophthalmology* 91: 1464-1474.
2. Klein BE (2007) Overview of epidemiologic studies of diabetic retinopathy. *Ophthalmic Epidemiol* 14: 179-183.
3. Photocoagulation for diabetic macular edema: early Treatment Diabetic Retinopathy Study report number 1(1985) Early Treatment Diabetic Retinopathy Study research group. *Arch Ophthalmol* 103: 1796-1806.
4. Thomas BJ, Shienbaum G, Boyer DS, Flynn HW Jr (2013) Evolving strategies in the management of diabetic macular edema clinical trials and current management. *Canadian Journal of Ophthalmol* 48: 22-30.
5. Schachat AP (2008) A new look at an old treatment for diabetic macular edema. *Ophthalmology* 115: 1445-1446.
6. Vander JF, Duker JS, Benson WE, Brown GC, McNamara JA, et al. (1991) Long-term stability and visual outcome after favorable initial response of proliferative diabetic retinopathy to panretinal photocoagulation. *Ophthalmology* 98: 1575-1579.
7. Gentile RC, Stegman Z, Liebmann JM, Dayan AR, Tello C, et al. (1996) Risk factors for ciliochoroidal effusion after panretinal photocoagulation. *Ophthalmology* 103: 827-832.
8. McDonald HR, Schatz H (1985) Macular edema following panretinal photocoagulation. *Retina* 5: 5-10.
9. Jardeleza MS, Miller JW (2009) Review of anti-VEGF therapy in proliferative diabetic retinopathy. *Sem Ophthalmol* 24: 87-92.
10. Mitchell P, Bandello F, Schmidt-Erfurth U, Lang GE, Massin P, et al. (2011) The RESTORE study ranibizumab monotherapy or combined with laser versus laser monotherapy for diabetic macular edema. *Ophthalmology* 118: 615-625.
11. Brown DM, Nguyen QD, Marcus DM, Boyer DS, Patel S, et al. (2013) Long-term outcomes of ranibizumab therapy for diabetic macular edema the 36-month results from two phases III trials RISE and RIDE. *Ophthalmology* 120: 2013-2022.
12. Diabetic Retinopathy Clinical Research Network (2007) A phase II randomized clinical trial of intravitreal bevacizumab for diabetic macular edema. *Ophthalmology* 114: 1860-1867.
13. Lam DS, Lai TY, Lee VY, Chan CK, Liu DT, et al. (2009) Efficacy of 1.25 mg versus 2.5 mg intravitreal bevacizumab for diabetic macular edema: six-month results of a randomized controlled trial. *Retina* 29: 292-299.
14. Fang X, Sakaguchi H, Gomi F, Oshima Y, Sawa M, et al. (2008) Efficacy and safety of one intravitreal injection of bevacizumab in diabetic macular edema. *Acta Ophthalmol* 86: 800-805.
15. Ferrara N (2004) Vascular endothelial growth factor basic science and clinical progress. *Endocr Rev* 25: 581- 611.
16. Hurwitz H, Fehrenbacher L, Novotny W, Cartwright T, Hainsworth J, et al. (2004) Bevacizumab plus irinotecan, fluorouracil, and leucovorin for metastatic colorectal cancer. *N Engl J Med* 350: 2335-2342.
17. Nourinia R, Ahmadi H, Shahheidari MH, Zandi S, Nakao S, et al. (2013) Intravitreal Fasudil combined with bevacizumab for treatment of refractory diabetic macular edema a pilot study. *Journal of Ophthalmic and Vision Research* 8: 337-340.

Citation: Faghihi S, Ghassemi F, Abdi F, Esfahani M, Faghihi H (2017) Different Treatment Modalities in Diabetic Macular Edema Refractory to Intravitreal Bevacizumab: A Review Article. *Ophthalmol Res Rep* 2017; J122.

18. Kim MW, Moon H, Yang SJ, Joe SG (2016) Effect of Posterior Sub-tenon Triamcinolone Acetonide Injection on Diabetic Macular Edema Refractory to Intravitreal Bevacizumab Injection. *Korean J Ophthalmol* 30: 25-31.
19. Totan Y, Guler E, Guragac FB (2016) Dexamethasone Intravitreal Implant for Chronic Diabetic Macular Edema Resistant to Intravitreal Bevacizumab Treatment. *Current Eye Research* 41: 107-113.
20. Apte RS (2016) What Is Chronic or Persistent Diabetic Macular Edema and How Should It Be Treated? *JAMA Ophthalmology* 134: 285-286.
21. Edward HW, Karth PA, Moshfeghi DM, Leng T (2015) Short-Term Outcomes of Aflibercept Therapy for Diabetic Macular Edema in Patients with Incomplete Response to Ranibizumab and/or Bevacizumab. *Ophthalmic Surg Lasers Imaging Retina* 46: 950-954.
22. LiW, Sinclair SH, Xu GT (2010) Effects of Intravitreal Erythropoietin Therapy for Patients with Chronic and Progressive Diabetic Macular Edema. *Ophthalmic Surgery Lasers and Imaging* 41: 18-25.
23. Otani T, Kishi S, Maruyama Y (1999) Patterns of diabetic macular edema with optical coherence tomography. *Am J Ophthalmol* 127: 688-693.
24. Shimura M, Yasuda K, Yasuda M, Nakazawa T (2013) Visual outcome after intravitreal bevacizumab depends on the optical coherence tomographic patterns of patients with diffuse diabetic macular edema. *Retina* 33: 740-747.
25. Falavarjani KG, Golabi S, Modarres M (2016) Intravitreal injection of methotrexate in persistent diabetic macular edema a 6-month follow-up study. *Graefes Arch Clin Exp Ophthalmol* 254: 2159-2164.
26. Hernaez-Ortega MC, Soto-Pedre E, Pinies JA (2008) Lanreotide Autogel for persistent diabetic macular edema. *Diabetes research and clinical practice* 80: e8 - e10.
27. Lee JH, Lee WK, Kim SE (2016) Short-Term Outcomes of Switching to Ranibizumab Therapy for Diabetic Macular Edema in Patients with Persistent Fluid After Bevacizumab Therapy. *Journal Ocular pharmacology and therapeutics* 32: 659-664.