



Research Article

Abdominal Trauma: Occurrence and Outcome, An experience from 500 Patients

Ahmed S Alsheikhly^{1*}, Alaa K Fiad¹, Keebat Khan¹, Mohammed Mazin¹, Mazin A Alsheikhly²

¹Hamad Medical Cooperation (HMC), Doha-Qatar

²King Hamad University Hospital, Manama-Bahrain

*Corresponding author: Ahmed S Alsheikhly, Hamad Medical Cooperation (HMC) Doha-Qatar. Email: ahmadmomz@yahoo.com

Citation: Alsheikhly AS, Fiad AK, Khan K, Mazin M, Alsheikhly MA (2017) Abdominal Trauma: Occurrence and Outcome, An experience from 500 Patients.

Received Date: 28 July, 2017; **Accepted Date:** 15 August, 2017; **Published Date:** 22 August, 2017

Abstract

Different forms of trauma have been a leading cause of death as seen in the Accident and Emergency specially in the age group of 1-50 years. Most of the usual causes outlined in the published literature include road traffic accidents, stab wounds, falls from height and gunshot wounds.

The abdomen is traumatized in about 10-15% of cases; this would be attributed to its large surface area compared with other parts of the body. This prospective study was carried out over a period of one year starting January 2015 till December 2015, involving 500 cases with isolated abdominal injuries in some of the Gulf states and Iraq major hospitals. We highlight the incidence, gender distribution, available modalities of investigation and methods of improving management and prognosis of abdominal trauma in these variable hospitals. There were 500 purely abdominal trauma patients involved in the review over this one-year period. Penetrating injuries were seen in 66 patients (13.2%) and nonpenetrating in 434 patients (86.8%). Gunshot injuries and fall from heights were (2.02%) and (3.05%) of the injuries respectively. The overall ratio of non-penetrating to penetrating injuries was approximately 6:1.

Wound sepsis was the most common complication of patients that underwent surgical exploration; mortality rate was (10%). The major cause of death was irreversible hypovolemic shock due to severe blood loss either prior to arrival in hospital or uncontrollable hemorrhage in the operating room and extreme coagulopathy in the immediate post-operative period.

We advocate rapid transportation and prompt resuscitative measures, availability of modern technological investigations as well as surgical and intensive therapy skills in improving the outcome for victims of abdominal trauma regardless of the etiology. Spreading more awareness of the major factors in the causation of vehicular accidents and health education for drivers and road users, conspicuous display of speed limits as well as identification of the known accident black spots where road traffic accidents have historically been concentrated will be of significance in the prevention of future accidents and complications.

Keywords: Abdominal Trauma; Occurrence; Outcome

Introduction

Trauma remains one of the leading cause of death in the age 1-50 year [1]. It is of importance to address the issues related to the presentation and management of these cases in our catchment area in which majority of the population is young adults usually involved in penetrating and blunt trauma due to Road Traffic Accident.

The abdomen is traumatized in about 10-15% of cases; this would be attributed to its large surface area compared with other parts of the body [2], therefore bearing major injuries contributing to the severity of visceral damage found in presenting patients; This tends to escalate with increased frequency of high speed travel and possibly the rise in social violence [3] as we have noticed in other cases such as stabbing and other forms of penetrating traumas. According to the World Health Organization (WHO) Global Burden of Disease Project 2002, it was estimated that the Road

Citation: Alsheikhly AS, Fiad AK, Khan K, Mazin M, Alsheikhly MA (2017) Abdominal Trauma: Occurrence and Outcome, An experience from 500 Patients. Emerg Med Inves: EMIG-154.

Traffic Accident (RTA) mortality rate (per 100,000 populations) in the Middle East ranged from 19.1 to 28.3 (WHO, 2004) [4]. This stresses upon the enormity that RTAs play in subsequent economic drain to the national economy.

Other causes of abdominal trauma include fall from heights, gunshot wounds, stabbing etc. Blunt abdominal trauma poses a great difficulty in diagnosis and accounts for its higher mortality, so it is of utmost importance for medical personnel to be well versed with the assessment, resuscitation and surgical management of these victims [5].

Abdominal injuries should never be under estimated. Starting with appropriate initial assessment which includes (FAST) performed by a skilled operator and followed by repeated re-evaluation with adequate investigations; This specially aids in detecting intra-abdominal damage to viscera like spleen, liver, mesentery and bowel which are of immediate threat due to the nature of its vascularity [6]. Intra-abdominal injuries carry high morbidity and mortality rate because usually they are not detected as soon as possible usually due to their severity being under-estimated in the non-penetrating varieties with few or no external signs [7] or the approach to detecting it in which many factors contribute to delay the its detection such as operator dependent skills in Focused Assessment with Sonography (FAST) for example.

Prompt pre-hospital transportation, initial assessment thorough resuscitative measures and correct diagnosis are of paramount importance for subsequent good outcome. The policy of prioritization (proper triage) requires a regimented approach [8], identifying the victims who require immediate and precise care according to the principles of Advanced Trauma Life Support (ATLS). In view of the importance attached to this type of trauma resulting in high morbidity and mortality if not detected early and managed aggressively alongside with its subsequent severe socio-economic impact on the society, healthcare institutions and the government. This is why we found a need to carry out this retrospective study.

Materials and Methods

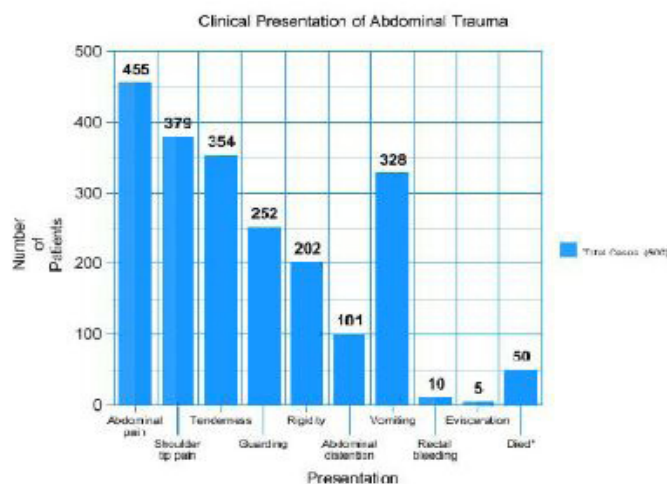
Data collection was by patients' medical record, number, sex, age, clinical presentation, type of trauma inflicted on the abdomen, information also gathered include ancillary investigations such as Diagnostic Peritoneal Lavage (DPL), abdominal ultrasound and abdominal Computerized Tomography (CT) scan carried out on the patients.

Data was initially documented on a special data collection form then transferred into a software form to be analyzed. The files were reviewed in regards of the history of presentation. The usual diagnostic pathway of taking history, physical examination and special investigations were not followed in some cases because of the urgency of presentation. Causes of the trauma such as road traffic accidents with or without seat belts, stabs, fall from heights,

and blunt trauma with heavy objects falling on the abdomen with pure abdominal injuries were also included from the files. The findings on the abdomen and lower chest wall, anterior or posterior, regarding evidence of bruises, lacerations, impressions of seat belts or vehicle wheels, penetrating wounds, entry and exit wounds were also all recorded. The presence of abdominal rigidity, percussion or cough tenderness as indicators of visceral injury was also recorded from the files.

Bowel sounds auscultation did not show much initially, but digital rectal examination was found useful specially to ascertain the integrity of the rectal wall or the presence of blood denoting large bowel injury or organ damage within the pelvis.

Clinical presentations in this study are as outlined in Graph 1 of which haemo-peritoneum resulting in agonizing abdominal pain was the most common mode of presentation. Careful evaluation of the clinical signs of peritoneal irritation is frequently rewarding, however analysis of these figures has shown a call for caution since the most constant signs and symptoms may be absent.



Graph 1: *Died (50) (40 males 10 females): Closed abdominal trauma (45) & Penetrating abdominal trauma (5).

Investigations

The investigations that were done include baseline Complete Blood Count (CBC), biochemistry, blood grouping and cross matching and subsequently the values were compared with the base-line values.

Other ancillary mode of investigations were plain radiographs of cervical spine, chest, and pelvis X-ray. Urgent abdominal ultrasound in the emergency room and Diagnostic Peritoneal Lavage (DPL) were indicated in some cases but not all. Plain X-ray in many cases did not provide much help in the diagnosis of abdominal trauma. However, ten (10) of our patients had evidence of pneumoperitoneum on radiograph with air under the diaphragm as seen on erect plain films. Abdominal imaging such as ultra-

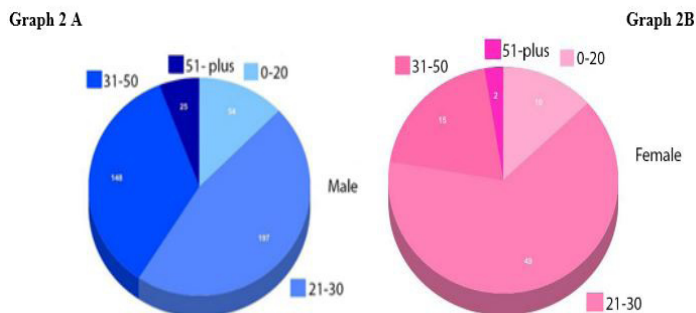
Citation: Alsheikhly AS, Fiad AK, Khan K, Mazin M, Alsheikhly MA (2017) Abdominal Trauma: Occurrence and Outcome, An experience from 500 Patients. Emerg Med Inves: EMIG-154.

sonography and computed tomography are not usually available for routine diagnosis in some emergency departments, but these are readily available in the hospitals involved in the study. The abdominal ultrasound in the series had a reliability of about 90% especially in detecting splenic trauma cases.

Ultrasound in the form of Focused Assessment with Sonography for trauma (FAST) was also performed immediately after the primary survey of the patient. Extended FAST (eFAST) was carried out in some of the highly unstable patients and this allows for the examination of both lungs. Helping in detection of a pneumothorax and possible tension pneumothorax; a deadly complication if not treated immediately at the bedside. Computed tomography was used routinely for all stable cases that did not need immediate laparotomy and in the diagnosis of suspected pancreatic and other retroperitoneal injuries. Diagnostic Peritoneal Lavage (DPL) was carried out in 30 cases that had equivocal signs, or cases with co-existing closed head injury. Five cases had diagnostic laparoscopy needed in which the ultrasound operator could not completely rule out the presence of haemo-peritoneum.

Results

The total number of abdominal trauma cases reviewed from the period January 2015 till December 2015 were 500 cases out of which 424 (84.8%) were non-penetrating and 76 (15.2%) were penetrating with a ratio of almost 6:1. (Graph 2)



Graph 2 A, B: Shows the age and sex distribution of the cases.

It is immediately obvious that abdominal injuries and possibly multiple injuries for that matter are predominantly an affliction of the young males and females reaching the peak in 21 - 30 age group and extending to 31- 50 in both.

This can be considered the productive age in which the society strongly needs these men and women to be active and accomplishing instead of them being wasted injuries and traumas that if not tackled well, a huge burden and a great drain is put upon the society and the national economy.

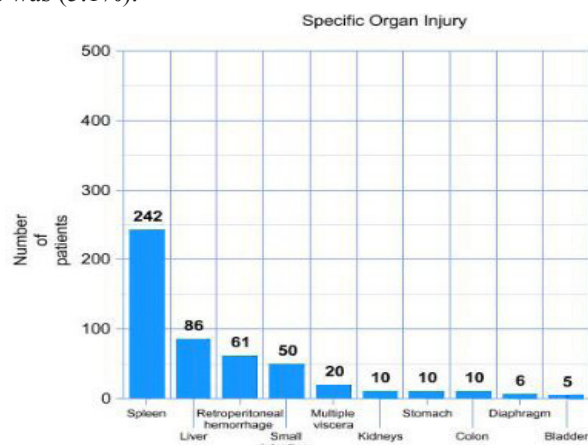
The other notable feature is the overall incidence of male cases (424) 84.8% to female cases (76) 15.2% with a ratio of about 6:1, This shows a reflection that the males are more vulnerable

to trauma and accidents since culturally and traditionally in this region society is male dominant.

Splenic rupture in 242 cases (48.4%) topped the list of specific organ damage as shown in Graph 3, meanwhile delayed rupture of the spleen was not seen in this review. Hepatic injuries in 86 cases account for (17.2%) of the lesions. A combination of both splenic and hepatic injuries was seen in 10 cases (2%), out of which two died on the operative table due to severe uncontrollable bleeding but the other patients survived. Retroperitoneal hematoma and injuries to the small bowel and stomach were seen in 61 (12.2%), 50 (10%) and 10 (2%) cases respectively. There were 50 deaths in this study (10%) out of which 40 were males and 10 were females.

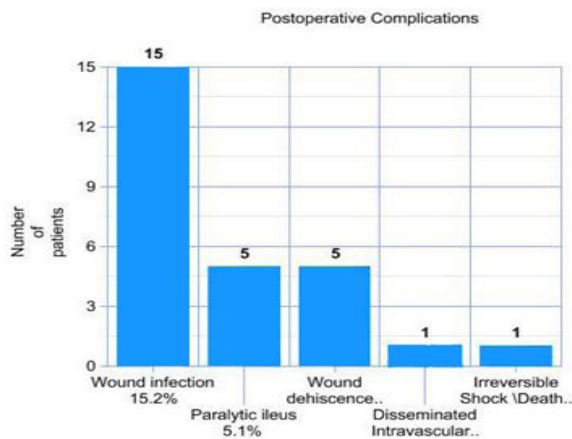
Some of these deaths are caused due to a delay in getting help for early transportation to the hospital and most probably bled at the accident site and might also had associated severe chest and head injuries. With regards to management, three principles emerged regarding these cases, early transportation to the hospital, prompt resuscitation and early laparotomy. Early blood transfusion has not been a problem although most emergency departments rely heavily on the use of colloids and crystalloids. Auto transfusion has not been found to be a suitable alternative in abdominal trauma but has succeeded in few cases of splenic trauma.

The decision to operate was based on the clinical evaluation, signs of peritoneal irritation, unexplained shock despite adequate fluid resuscitation, rigid silent abdomen, evisceration, Findings from abdominal ultrasound, Diagnostic Peritoneal Lavage (DPL) in selected cases and abdominal paracentesis. Delaying operation beyond 24 hours of presentation contributed significantly to the mortality rate. Postoperative complications seen in this study are as shown in Graph 4. Wound sepsis was seen in (15.2%). This is probably related to wound contamination at the time of injury; the same goes for wound dehiscence (5.1%). Incidence of paralytic ileus was (5.1%).



Graph 3: Specific Organ Injury.

Citation: Alsheikhly AS, Fiad AK, Khan K, Mazin M, Alsheikhly MA (2017) Abdominal Trauma: Occurrence and Outcome, An experience from 500 Patients. Emerg Med Inves: EMIG-154.



Graph 4: Postoperative Complications.

Discussion

Abdominal trauma carries a high morbidity and mortality especially if not detected early or if its severity is underestimated [9,10]. Intra-abdominal bleeding should be suspected if there are fractures of the fifth to eleventh ribs, which lie over the liver and spleen [6,11], or if there are marks caused by seat belts or vehicular wheels over the abdomen.

Measurement of pulse and blood pressure were particularly unreliable as indices of serious intraabdominal bleeding. Initial hemoglobin measurement had no relevance to severity of injury. Urinalysis seemed to be a reasonable indication of lower urinary tract injury since most cases of renal trauma showed hematuria or blood at the urethral meatus. The presence or absence of bowel sounds was also misleading.

The role of the plain radiograph is not so significant in assessing abdominal trauma except when there is rupture of the diaphragm and missiles that lodged in the abdomen. Ultrasound used to be the ideal initial imaging modality because it can be performed simultaneously with other resuscitative cares, providing vital information without the time delay caused by radiographs or computed tomography. Although ultrasound is not 100% sensitive for identifying all bleeding, it is nearly perfect for recognizing intraperitoneal bleeding in hypotensive patients who need an emergent laparotomy and for diagnosing cardiac injuries from penetrating trauma [12,13].

This supremacy has been taken over by FAST which has been used in the evaluation of trauma patients in Europe and United States for more than 20 years. It has now become the initial imaging modality of choice for trauma and it is part of the Advanced Trauma Life Support (ATLS) protocol developed by the American College of Surgeons.

The FAST exam, per ATLS protocol, is performed immediately after the primary survey of the patient. The concept behind

the FAST examination is that many life-threatening injuries cause internal bleeding which should be detected by FAST.

The four classic areas examined during FAST for free fluid are the perihepatic space also called Morison's pouch or the hepatorenal recess, perisplenic space, pericardium, and the pelvis. With this technique, it is possible to identify the presence of intraperitoneal or pericardial free fluid. In the context of traumatic injury, this fluid will usually be due to bleeding. FAST's diagnostic accuracy generally is equal to that of diagnostic peritoneal lavage (DPL). Recently, research studies have shown that bedside ultrasound is equivalent to, or better than, chest radiography for identifying a hemothorax or pneumothorax in trauma patients.

For this reason, some trauma centers have begun performing an extended FAST examination (EFAST) evaluating for pneumothorax and hemothorax in addition to intraperitoneal injuries. It can also detect tension pneumothorax which is a deadly complication if not treated immediately at the bedside without the need to shift the unstable patient to a radiology suite.

CT scan of the abdomen with and without contrast as the case may be increased the diagnostic work-up of trauma patients with suspected abdominal injuries. A wide range of intra-peritoneal and retroperitoneal organ injuries can be quickly and accurately diagnosed with CT scan of the abdomen [14]. It should be noted that only hemodynamically stable patients should be transported to the CT scanner and while performing CT scan, close monitoring of the vital signs for clinical evidence of decompensation should be carried out.

The drawbacks of CT scanning are the need to transport the patient from the trauma resuscitation area and the additional time required to perform CT scanning as compared to FAST, EFAST or DPL. The best CT imagery requires both oral and intravenous (IV) contrast. However, helical CT technology permits even faster examinations with its technological advancement lately, with improved intravenous contrast opacification of parenchymal organs and vascular structures and reduced CT artifacts caused by patient motion, respiration, and arterial pulsation. Severely injured and potentially unstable patients, who might not have been able to tolerate the long CT examinations in the past, may be quickly evaluated today with helical CT. Paracentesis abdominis was reported in some series with a sensitivity of 96.6%. Diagnostic peritoneal lavage was done only in six (6) patients (6.1%) in our series [8,15,16].

Laparoscopy is still awaiting a true delineation of utility. It will probably be most useful in cases of penetrating trauma where significant intra-abdominal injury cannot be excluded, but appears clinically doubtful [17,18]. Laparoscopy gives complete visualization of the peritoneal cavity but retroperitoneal structures are not easy to visualize. Even a small amount of blood in the peritoneal cavity precludes adequate visualization and therefore mandates

Citation: Alsheikhly AS, Fiad AK, Khan K, Mazin M, Alsheikhly MA (2017) Abdominal Trauma: Occurrence and Outcome, An experience from 500 Patients. *Emerg Med Inves: EMIG-154*.

laparotomy. The effect of laparoscopy upon intracranial pressure in cases of concomitant head trauma has not been completely delineated. The significant factors affecting prognosis or final outcome noticed in this study include how rapidly the patient was transported to the hospital [19,20]. This could be broken down to the injury admission interval and injury operation interval. Prompt evacuation of the injured and early evaluation and treatment are required to reduce mortality. Secondly the presence of other associated injuries in addition to abdominal trauma also determine final prognosis. The combination of head and chest injuries with abdominal trauma is particularly undesirable [21], while patients with orthopedic injury have a more favorable course.

The nature of the associated injury may decide outcome but as far as the abdominal lesion itself is concerned early recognition and prompt surgical action are the essential features of successful management. The lesions liable to be over-looked in patients with multiple injuries who are not subjected to immediate laparotomy are diaphragmatic tear with subsequent hernia, intestinal rupture and sub capsular hematoma of the hollow viscera and these should be especially considered [22-24].

Conclusion

we recommend that prompt evacuation of the injured patient to the hospital, adequate resuscitation, diagnostic Focused Abdominal Sonogram for Trauma (FAST) as well as EFAST, Peritoneal Lavage (DPL) and other diagnostic modalities, constant monitoring with re-assessment and finally timely surgical intervention all play a key role in the successful outcome of such patients. Adherence to local highway laws and education of road traffic accident prevention should be encouraged and enforced [19,25]. The concept of teamwork in the management of the critically traumatized patient cannot be over-emphasized and has to be promoted, practiced and established in order to improve clinical outcome.

References

- Ghulam NL, Ghulam QP, Khursheed AW, Abdul MB, Naar AW, et al. (2001) An experience with abdominal trauma in adults in Kashmir. *JK-Practitioner* 8: 225-230.
- Ponifasio P, Poki HO, Watters DA (2001) Abdominal trauma in urban Papua New Guinea. *P N G Med J* 44: 36-42.
- Bates T (1973) Abdominal trauma- a report of 129 cases. *Postgrad Med J* 49: 285-292.
- El-Sadig M, Norman JN, Lloyd OL, Romilly P, Bener A (2002) Road traffic accidents in the United Arab Emirates: trends, morbidity and mortality during 1977-1998. *Accid Anal Prev* 34: 465-476.
- Ng KS, Hung WT, Wong WG (2002) An algorithm for assessing the risk of traffic accident. *J Safety Res* 33: 387-410.
- Ohanaka EC, Osime U, Okonkwo CE (2001) A five-year review of splenic injuries in the University of Benin Teaching Hospital, Benin City, Nigeria. *West Afr J Med* 20: 48-51.
- Edna TH, Bjerkeset T, Myrvold HE (1989) Abdominal injuries. Occurrence and outcome. *Tidsskr Nor Laegeforen* 109: 2111-2114.
- Maxwell-Armstrong C, Brooks A, Field M, Hammond J, Abercrombie J (2002) Diagnostic peritoneal lavage analysis: should trauma guidelines be revised?. *Emerg Med J* 19: 524-525.
- Cox EF (1984) Blunt abdominal trauma A 5-year analysis of 870 patients requiring celiotomy. *Ann Surg* 199: 467-474.
- Isenhour JL, Marx J (2007) Advances in Abdominal Trauma. *Emerg Med Clin N Am*: 713-733.
- Iribhogbe PE, Okolo CJ (2009) Management of splenic injuries in a University Teaching hospital in Nigeria. *West African Journal of Medicine* 28: 308-312.
- Rozycki GS, Shackford SR (1996) Ultrasound, what every trauma surgeon should know. *J Trauma* 40: 1-4.
- Rothlin MA, Naf R, Amgwerd M, Candinas D (1993) Ultrasound in blunt abdominal and thoracic trauma. *J Trauma* 34: 488-495.
- Udekwu PO, Gurkin B, Oller DW (1996) The use of computed tomography in blunt abdominal injuries. *Am Surg* 62: 56-59.
- Liu M, Lee CH, P'eng FK (1993) Prospective comparison of diagnostic peritoneal lavage, computed tomographic scanning, and ultrasonography for the diagnosis of blunt abdominal trauma. *J Trauma* 35: 267-270.
- Cuschieri A, Hennessy TP, Stephens RB, Berci G (1988) Diagnosis of significant abdominal trauma after road traffic accidents: preliminary results of a multicenter clinical trial comparing minilaparoscopy with peritoneal lavage. *Ann R Coll Surg Engl* 70: 153-155.
- Ahmed N, Whelan J, Brownlee J, Chari V, Chung R (2005) The contribution of laparoscopy in evaluation of penetrating abdominal wounds. *J Am Coll Surg* 201: 213-216.
- Bokarev MI, Molitvoslov AB, biriukov IuV, Sergeev SV (2004) Laparoscopy in diagnosis of abdominal injuries in patients with combined trauma. *Khirurgiia (Mosk)*: 23-25.
- Berner A, Abu-Zidan FM, Bensiali AK, Al-Mulla AA, Jadaan KS (2003) Strategy to improve road safety in developing countries. *Saudi. Med J* 24: 447-452.
- Anderson ID, Woodford M, de Dombal T, Irving M (1988) Retrospective study of 1000 deaths from injury in England and Wales. *Br Med J* 296: 1305-1308.
- Munns J, Richardson M, Hewett P (1995) A review of intestinal injury from blunt abdominal trauma. *Aust. N. Z. J Surg* 65: 857-860.
- Sayers RD, Bewes PC, Porter KM (1992) Emergency laparotomy for abdominal trauma. *Injury* 23: 537-541.
- Oyo-Ita A, Ugare UG, Ikpeme IA (2012) Surgical versus non-surgical management of abdominal injury. *Cochrane Database Syst Rev* 14: 11.
- Dubose JJ, Scalea TM, Holcomb JB, Shrestha B, Okoye O, et al. (2013) AAST Open Abdomen Study Group.; Open abdominal management after damage-control laparotomy for trauma: A prospective observational American Association for the Surgery of Trauma multicenter study. *J Trauma Acute Care Surg* 74: 113-22.
- Mnguni MN, Muckart DJ, Madiba TE (2012) Abdominal trauma in durban, South Africa: factors influencing outcome. *Int Surg* 97: 161-168.