

# Medical Treatment of a Cystic Macroprolactinoma Mimicking Surgical Excision

Maiza Jean-Christophe

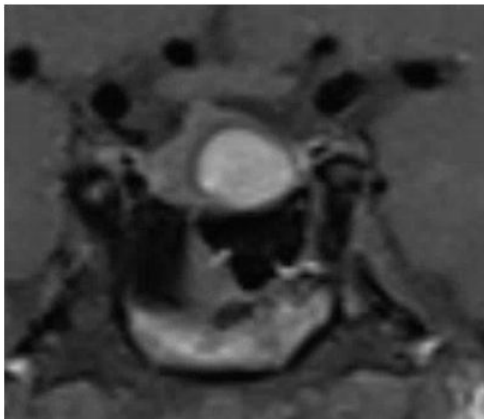Department of Endocrinology and Metabolic Diseases, CHU Reunion, Groupe Hospitalier Sud-Reunion, BP-350, Saint-Pierre, France

**Corresponding author:** Maiza Jean-Christophe, Department of Endocrinology and Metabolic Diseases, CHU Reunion, Groupe Hospitalier Sud-Reunion, BP-350, 97448 Saint-Pierre, France. Tel: +33262359363; Email: jean-christophe.maiza@chu-reunion.fr

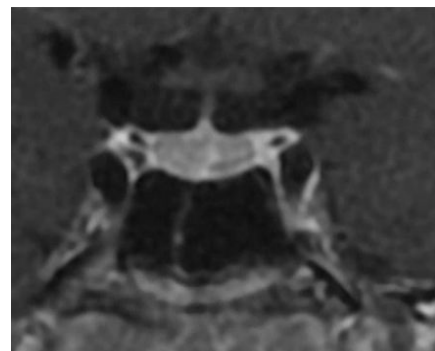
**Citation:** Jean-Christophe M (2017) Medical Treatment of a Cystic Macroprolactinoma Mimicking Surgical Excision. J Clin Endocrinol Metab Disord: JCEMD-105.

**Received Date:** 11 October, 2017; **Accepted Date:** 17 October, 2017; **Published Date:** 23 October, 2017

A 17 years-old patient was referred to our institution for suspicion of delayed puberty. He had no medical history. Phallus was 7 cm length and testis volume was 10 mL. Secondary sexual characteristics were scarce. He had no growth retardation. Testosterone level was 23 ng/dL (normal 32-140) with low gonadotrophins (LH: 4.8 UI/L, FSH: 2.6 UI/L). Prolactin level was 40 ng/mL (normal 3.4-19). Cortisol, TSH, T4I, IGF-1 were in the normal range. MRI revealed a 1 cm pituitary cystic macro adenoma (Figure 1), leading to the diagnosis of cystic macroprolactinoma. Visual fields were normal. NEM1 and AIP genes were negative. The patient was treated with dopamine agonist cabergoline 0.5 mg twice a week. The treatment was poorly tolerated and the cabergoline was thus switched for quinagolide 75 microgram/day. 3 months later prolactin level was 9 ng/ml and testosterone reached 70 ng/dL. Secondary sexual characteristics progressively developed. MRI was periodically controlled and 2 years later (Figure 2), the pituitary mass had totally shrunk mimicking surgical excision.



**Figure 1:** At diagnosis, coronal T1-weighted image showed a 1 cm hyperintense pituitary tumor.



**Figure 2:** Two years later, MRI was normalized.

Optimal management strategies for cystic prolactinomas are poorly defined. Solid prolactinomas are generally treated with dopamine agonists but cystic prolactinomas are frequently assumed to be resistant to volume reduction following dopamine agonists administration and subsequently often treated surgically [1,2]. Nevertheless, a recent study is in favor to dopamine agonists as primary treatment of cystic prolactinomas [3]. Few data are available concerning their management particularly in young patients. Our case demonstrates that medical treatment with dopamine agonists can be efficient and considered before surgical cure even in young patients with cystic macroprolactinomas.

## References

1. Kreutzer J, Buslei R, Wallaschofski H, Hofmann B, Nimsky C, et al. (2008) Operative treatment of prolactinomas: indications and results in a current consecutive series of 212 patients. *Eur J Endocrinol* 158: 11-18.
2. Casanueva FF, Molitch ME, Schlechte JA, Abs R, Bonert V, et al. (2006) Guidelines of the Pituitary Society for the diagnosis and management of prolactinomas. *Clin Endocrinol* 65: 265-273.
3. Faje A, Chunharojrith P, Nancy J, Biller BM, Swearingen B, et al. (2016) Dopamine Agonists Can Reduce Cystic Prolactinomas. *J Clin Endocrinol Metab* 101: 3709-3715.