

## Case Report

# Laparoscopic Liberation of Celiac Artery in Median Arcuate Ligament Syndrome in Infant: A Case Report and Literature Overview

Pierre Jean Aurelus<sup>\*</sup>, Hermilo De La Cruz Yáñez<sup>1</sup>, Ramón Eduardo Salgado Sangri<sup>3</sup>, Arturo Arias Ambrosio<sup>3</sup>, María Del Roció Méndez Méndez<sup>2</sup>, Zapata Carrión Rafael Roberto<sup>1</sup>, Edwin Allen Meía Solís

<sup>1</sup>Department of Gastro-transplantation, HP CMNSXXI (IMSS), Mexico

<sup>2</sup>Department of Pediatric Radiology, HP CMNSXXI (IMSS), Mexico

<sup>3</sup>Department of Pediatric Surgery, HP CMNSXXI (IMSS), Mexico

<sup>4</sup>Department of General Surgery, Regional Hospital of ISSSTE, Puebla, Mexico

\***Corresponding author:** Pierre Jean Aurelus, Hospital of Pediatrics National Medical Center Siglo XXI (Mexican Institute of Social Security "IMSS"), Mexico. Tel: +525556276900; Email: aurelusjean@yahoo.com.mx

**Citation:** Aurelus PJ, Yáñez HDLC, Sangri RES, Ambrosio AA, Méndez MDRM, et al. (2018) Laparoscopic Liberation of Celiac Artery in Median Arcuate Ligament Syndrome in Infant: A Case Report and Literature Overview. J Surg: JSUR-1147. DOI: 10.29011/2575-9760.001147

**Received Date:** 19 June, 2018; **Accepted Date:** 03 July, 2018; **Published Date:** 09 July, 2018

### Abstract

**Introduction:** Median Arcuate Ligament Syndrome (MALS) is a rare cause of chronic abdominal pain in adult and infant. This syndrome typically occurs in thin women, who may present with epigastric pain and weight loss. The aim of this study was to report our first case of a 10-year-old girl patient treated with laparoscopic liberation of the celiac trunk artery in Median Arcuate Ligament Syndrome (MALS) in our Pediatric center.

**Case Report:** A thin female of 10-year-old with chronic postprandial abdominal pain accompanying vegetative symptoms: nausea, vomiting, dizziness, tachycardia, weight loss and sweating. Her physical examination revealed epigastric pain to palpation and low weight. An abdominal ultrasound showed celiac artery flow of 116 cm/s and Resistance Index (RI) = 0.76. In the same sense, an angiotomography was performed and showed a high-grade stenosis involving the origin of the celiac trunk and hemodynamic study was performed too.

**Results:** The duration of the procedure was 154 minutes. The postoperative hospital recovery period was 3 days. No intraoperative or postoperative complications occurred: bleeding events, blood transfusions and stenosis of the celiac trunk. The patient accepted well the cosmetic aspect without pain.

**Conclusion:** The outcome of the pediatric patient was satisfactory, and the laparoscopic procedure liberation of the celiac trunk was sufficient in this case. Laparoscopic liberation of celiac trunk is reliable and a less invasive procedure with good results and cosmetic aspect in pediatric patient.

**Keywords:** Artery; Celiac; Laparoscopic; Liberation; MALS

### Introduction

Median Arcuate Ligament Syndrome (MALS) is a rare cause of chronic abdominal pain in adult and infant. The incidence is not known; in infant with abdominal pain a prevalence of 1.5% was found.<sup>1-3</sup> It is characterized by an abnormally low fibrous or ligament of the aortic hiatus. Although, this ligament usually passes superior to this hiatus [1-5]. This MALS also known as Dumb syndrome or celiac artery compression syndrome was the first described by

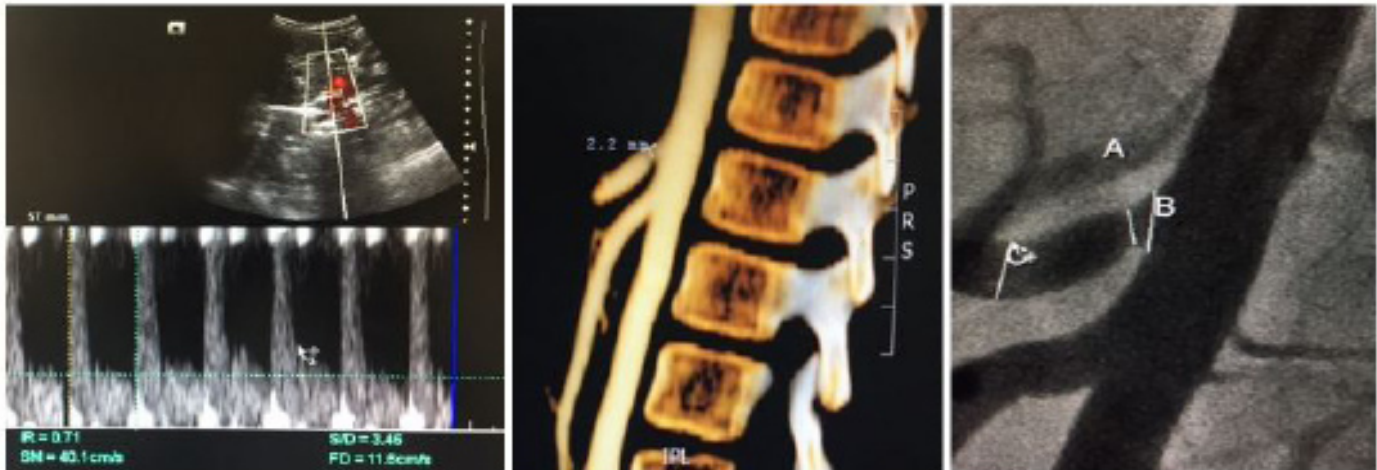
Hartjola in 1963 and may have indentation in 10-24% of people [2,4,5]. Few of these patients have hemodynamically significant stenosis that would cause symptoms. In fact, the literature reports a compression level near to 50% of the celiac axis. However, the two main theories used to explain the pathogenesis of symptoms are mesenteric ischemia and neurogenic stimulation caused by compression of the celiac ganglion and plexus [1,2,5]. This syndrome typically occurs in thin women, who may present with epigastric pain and weight loss [4]. This compression is increased by expiration and decreases with inspiration and the demonstration

of the vascular stenosis itself serves only as a diagnostic marker [3]. Doppler Ultrasonography (DUS) reveals the stenosis/compression of celiac artery with increase flow velocity and Computed Tomography (CT) angiography confirms the compression of celiac trunk [6]. In the actuality, this syndrome has begun to be recognized more frequently in pediatrics population. The aim of this study was to report our first case of a 10-year-old girl patient treated with laparoscopic liberation of the celiac trunk artery in Median Arcuate Ligament Syndrome (MALS) in our Pediatric center [Hospital of Pediatric “Dr. Silvestre Frenk Freund” National Medical Center Siglo XXI: IMSS (Mexican Institute of Social Security) Mexico].

## Case Report

A thin female of 10-year-old with chronic postprandial abdominal pain accompanying vegetative symptoms: nausea,

vomiting, dizziness, tachycardia, weight loss and sweating. Her physical examination revealed epigastric pain to palpation and low weight without other important disorder. She had medical history of food allergy. An abdominal ultrasound showed celiac artery velocities with flow of 116 cm/s and Resistance Index (RI) =0.76, the presumptive diagnosis of the patient was celiac artery compression syndrome. In the same sense, an angiotomography was performed and showed a high- grade stenosis involving the origin of the celiac trunk. Hemodynamic study was performed and showed diameter difference in stenosis trunk during in inspiration and expiration. Finally, the diagnosis was median arcuate ligament syndrome. Furthermore, she continued with postprandial pain and weight loss; that was the indication to perform the laparoscopic surgical procedure. (Figures 1-3).

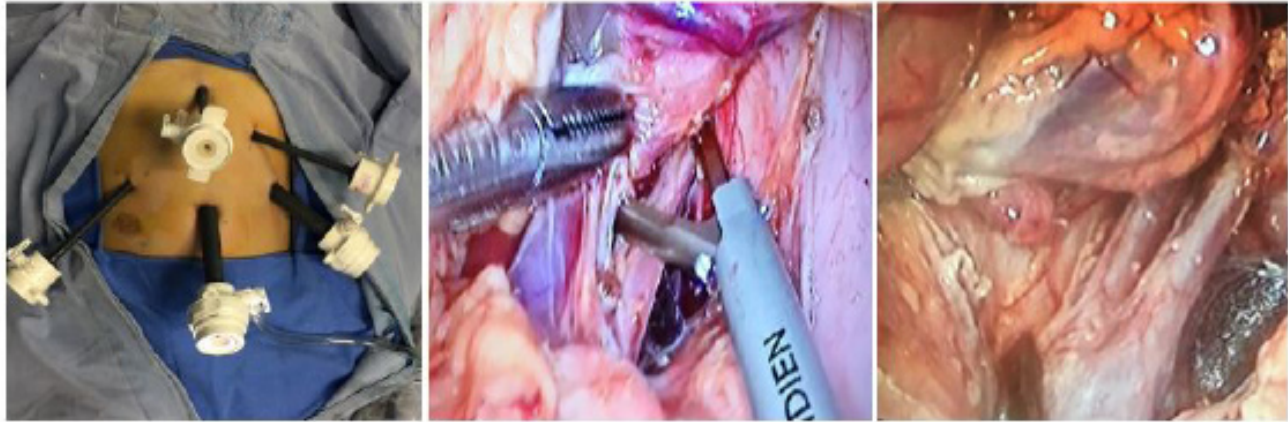


**Figure 1: Doppler Ultrasound. Figure 2: Angiotomography. Figure 3: Hemodynamic study.**

## Technique

Under balanced general anesthesia, the patient was placed in a supine position. Five trocars were inserted like the fundoplication procedure. A 10-mm trocar was inserted in the umbilicus; another 10-mm diameter trocar was inserted too in the left quadrant. Right, left upper quadrant and left middle abdomen with three 5-mm trocars. We acceding to the retroperitoneum beside the stomach,

the two most cranial trocars were placed high, just below the costal margin, medial to or the mammary line. The peritoneum over the right crus was opened and identified the celiac trunk opposite to the left gastric artery. Celiac Ganglion was cauterized and incised with Ligasure. The ligament arcuate was revealed and under continual traction the ligament was exposed and divided step by step with the Ligasure to liberate the celiac artery. The celiac trunk was exposed and observed an erection of the vessel (Figures 4-6).

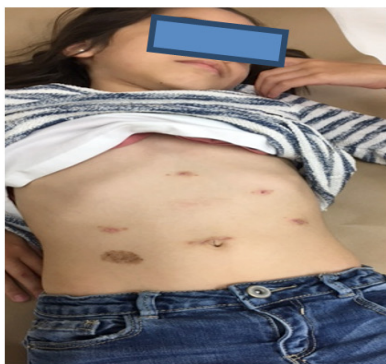

**Figure 4:** Trocars positioning. **Figure 5:** Peritoneum dissecting. **Figure 6:** Liberation Celiac Trunk.

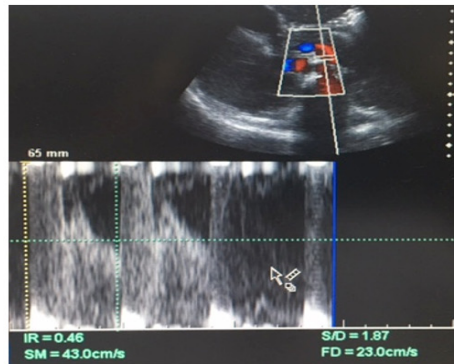
## Result

The duration of the procedure was 154 minutes. The postoperative hospital recovery period was 3 days. During the initial diagnostic others, no relevant diagnoses, Gastro-esophageal reflux and food allergy were found. No intraoperative or postoperative complications occurred: bleeding events, blood transfusions and stenosis of the celiac trunk. None complication of the procedure was observed. The patient accepted well the cosmetic aspect without pain. She had a good outcome and accepted well the oral alimentation and wins 3 kg of height in the first month postoperative without

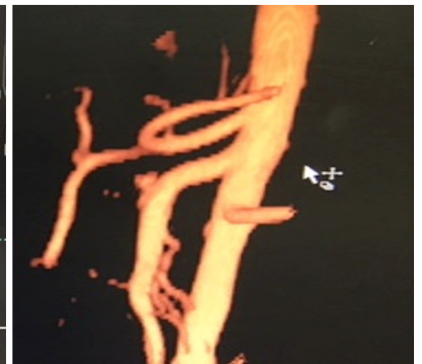
pain, nausea and vomiting. We performed a Doppler ultrasound at 30 days postoperative; the celiac artery velocities with flow were 230 cm/s with RI of 0.46. At two months of the procedure the patient presented nausea and esophageal reflux symptoms that required medical treatments. Angiotomography and gastroesophageal series were performed, and the celiac trunk was successful decompressed with normal blood flow. In fact, the celiac trunk was noted well, the high-grade narrowing showed preoperatively was not observed in control ultrasound and CT angiography and she diagnosed minimum reflux into the series, (Figures 7-9).



**Figure 7:** Cosmetic aspect.



**Figure 8:** Control DUS.



**Figure 9:** Control Angiotomography

## Discussion

Median Arcuate Ligament Syndrome or Celiac Artery Compression Syndrome (CACS) continues to be rarely in the pediatric population, it disorder is caused by an extrinsic compression of the celiac trunk from the median arcuate ligament.

The mechanism of pain is not completely clear in this syndrome, different theories exist but the most accepted, one is that increased blood demand through a compressed celiac artery leads to foregut ischemia and subsequent pain [3,5,7-9]. Langenbecks, et al. reported highly frequency in female than male, in our study the patient was a

female. On the other hands, it is an important differential diagnosis in chronic abdominal without any other imaging finding. In our pediatric center it was the first case that the liberation of the celiac trunk was performed by laparoscopic procedure, which is the mean of this work [5,7,10]. The symptoms of this syndrome include the classical triad observed in mesenterial ischemia characterized by postprandial abdominal pain, nausea, vomiting and subsequently weight loss, in fact, those symptoms were observed in our patient [9-11]. Although, median arcuate ligament compression occurs in about 10-25% of the population and does not cause any symptom. Celiac trunk compression syndrome or Median Arcuate Ligament Syndrome or Dunbar syndrome is a diagnosis of exclusion and it is often difficult. Some other diseases may cause similar symptoms like esophagitis, gastroesophageic reflux, pancreatitis, and cholelithiasis and food intolerance. The diagnosis may be performed by Doppler ultrasound, selective angiography, magnetic resonance angiography, spiral computed tomography angiography and rarely by hemodynamic study [8,11-13]. Aschenbach, et al. reported the peak velocity in Doppler US was 140cm/s in normal patient and in case of Median Arcuate Ligament Syndrome it was between 304 cm/s. In the same sense, Walter reported a peak flow on the celiac axis of more than 200 cm/s during inspiration and expiration; in addition to an angiogram in 15 patients leading to the diagnosis MALS in his study [3,4,9,14]. In our study it was 401 cm/s, with flow diameter of 116 cm/s and the resistance index was 0.7 Preoperatively. Continued in the control US postoperatively, the resistance index was 0.46 with 230 cm/s of flow [5,13]. Unfortunately, we performed an additional hemodynamic study in our patient to make sur of the diagnostic, which it is considered like a disadvantageous for the application of iodinated contrast agents and radiation exposure in pediatric patient [4-6,13].

Surgical management of Median Arcuate Ligament Syndrome is controversial [4,15] Different types of vascular reconstruction exist to performance the celiac axis in this syndrome like: Patch angioplasty of the celiac artery, aortoceliac bypass with saphenous vein or Dacron graft and aortic reimplantation of the celiac artery [4,8,15] Besides open surgery procedures, laparoscopic and endovascular technique have gained interest within the last decade [10,16]. Laparoscopic release of the median arcuate ligament was first used in 2000, providing a promising new treatment option that reduces postoperative hospital care and recovery time [3,7] Even though, some authors thinking; laparoscopy alone may not be sufficient if permanent changes in the celiac artery wall are present [8]. In our few experiences in this case and based in the literature, we recommended the laparoscopic procedure in the first step of treatment in this syndrome when the patient demonstrate worse outcome, like it was the indication in this case [3,6,14,16]. The literature suggests that if an adequate diagnosis is made, laparoscopic release of the median arcuate ligament without

additional reconstruction can be successful in reducing symptoms, in our case we can provide that hypothesis in our pediatric patient [7,10]. Grottemeyer D, et al. reported eleven of 15 patients were completely free of abdominal symptoms and nine of them had gained between 3 and 10 kg in weight after the procedure, similarly situation that had observed in the outcome of our patient, she had gained 3 kg and no pain after celiac trunk liberation by laparoscopic procedure [10]. However, it has been postulated that the pain is neuropathic and that ganglionectomy of the celiac plexus is the appropriate therapeutic choice. Although some authors have argued that the pain is caused by gastroduodenal tract ischemia, others believe it arises from celiac plexus compression resulting in ischemia throughout the foregut [5,7-8]. We accept this point of view due the outcome of our patient after the release or liberation of the celiac trunk artery to the arcuate ligament. Some studies reported the mean in-hospital stay was 11.5 days (range 5 to 27 days) our patient had three days hospital stay [10,14].

## Conclusion

The Median Arcuate Ligament Syndrome is a difficult diagnosis to obtain in pediatric patient. Therefore, in chronic abdominal pain it should undergo a Doppler ultrasound and an angiotomography to rule out this syndrome. The outcome of the pediatric patient was satisfactory, and the laparoscopic procedure liberation of the celiac trunk was sufficient in this case, the patient had continued with minimum reflux symptoms that required medical treatment. Laparoscopic liberation of celiac trunk is reliable and a less invasive procedure with good results and cosmetic aspect in pediatric patient.

## Conflicts of Interest

There are no conflicts of interest to disclose.

## Acknowledgements

To IMSS, Patients, Ortega Rodríguez Ma Del Carmen, Yesenia Navarro Sánchez and Jean Family.

## References

1. Soman S, Sudhakar SV, Keshava SN (2010) Celiac axis compression by median arcuate ligament on computed tomography among asymptomatic persons. *Indian J Gastroenterol* 29: 121-123.
2. Lainez RA and Richardson WS (2013) Median Arcuate Ligament Syndrome: A case Report. *The Ochsner Journal* 13: 561-564.
3. Klimas A, Lemmer A, Bergert H, Brodhun M, Scholbach T, et al. (2015) Laparoscopic treatment of celiac artery compression syndrome in children and adolescents 44: 305-312.
4. Horton KM, Talamini MA, Fishman EK (2005) Median Arcuate ligament Syndrome: Evaluation with CT Angiography. *RadioGraphics* 25: 1177-1182.

5. Aschenbach R, Basche S, Vogl TJ (2011) Compression of the celiac trunk Caused by Median Arcuate Ligament in Children and Adolescent Subjects: Evaluation with Contrast-enhanced MR Angiography and Comparison with Doppler US Evaluation. *J Vasc Interv Radiol* 22: 556-561.
6. Divarci E, Celtik U, Dokumcu Z, Celik A, Ergun O, et al. (2017) Laparoscopic treatment of Median Arcuate Ligament Syndrome: A Rare Cause of Chronic Severe Abdominal Pain. *J Indian Assoc Pediatr Surg* 22: 48-50.
7. Joyce Daniel D, Antiel Ryan M, Oderich Gustavo, Gloviczki Peter, Tung Jeanne, et al. (2014) Pediatric median Arcuate Ligament Syndrome: Surgical Outcomes and Quality of life. *Journal of laparoscopic & Advanced Surgical Techniques* 24: 104-110.
8. Duffy AJ, Panait L, Eisenberg D, Bell RL, Roberts KE, et al. (2009) Management of median Arcuate Ligament Syndrome: A New Paradigm. *Ann Vasc Surg* 23: 778-784.
9. Duran M, Simon F, Ertas N, Schelzig H, Floros N, et al. (2017) Open vascular treatment of median arcuate ligament syndrome. *BMC Surgery* 17: 1-6.
10. Grottemeyer D, Duran M, Iskandar F, Blondin D, Nguyen K, et al. (2009) Median arcuate ligament: vascular surgical therapy and follow-up of 18 patients. *Langenbecks Arch Surg* 394: 1085-1092.
11. Torres OJM, Gama-Filho OP, Torres CCS, Medeiros RM, Oliveira CMB (2017) Laparoscopic treatment of Dunbar syndrome: A case report. *International Journal of surgery Case reports* 37: 230-232.
12. Cienfuegos JA, Rotellar F, Valentí V, Arredondo J, Pedano N, et al. (2010) Síndrome de compresión del tronco celiaco Revisión crítica en la era de la cirugía laparoscópica. *Rev Esp Enferm Dig* 102: 193-201.
13. Uchida H, Sakamoto S, Matsunami M, Sasaki K, Shigeta T, et al. (2014) Hepatic artery reconstruction preserving the pancreaticoduodenal arcade in pediatric liver transplantation with celiac axis compression syndrome: report of a case. *Pediatr transplantation* 18: E232-235.
14. Walter P (2005) Celiac trunk compression: angiographic phenomenon or cause of ischemic abdominal complaints? *Zentralbl Chir* 130: 227-234.
15. Bech FR (1997) Celiac artery compression syndromes. *Surg Clin North Ann* 77: 409-424.
16. Ellebrecht DB, Jung CF, Hoffmann M, Keck T (2016) Laparoscopic Division of the Arcuate Ligament: Treatment of the Coeliac Artery Compression. *Zentralbl Chir* 141: 505-508.