

Case Report

Gigantic Primary Melanoma of the Cheek: A Case Report

Pizzonia Giuseppe^{1*}, Sasso Andrea¹, Rossello Carlo², Musumarra Gaetano³

¹Department of Plastic and Maxillofacial Surgery, Hospital Santa Corona, Italy

²U.O. Hand surgery, ASL 2 Savona, Italy

³Plastic Surgery of the Hand, Azienda Ospedaliera, Via Pergolesi, Monza, Italy

***Corresponding author:** Pizzonia Giuseppe, Department of Plastic and Maxillofacial Surgery, Hospital Santa Corona, Via XXV Aprile, 17027 Pietra Ligure, Italy. Tel: +393492569055; E-mail: g.pizzonia@chirurgo-estetico.it

Citation: Giuseppe P, Andrea S, Carlo R, Gaetano M (2017) Gigantic Primary Melanoma of the Cheek: a case report. *Plast Surg Mod Tech* 2: 114. DOI: 10.29011/2577-1701.100014

Received date: 31 March, 2017; **Accepted date:** 19 April, 2017; **Published date:** 26 April, 2017

Abstract

Gigantic primary melanomas represent a rare clinical finding. Large Melanomas have usually a poor prognosis because of a high risk of extensive metastatic disease at the diagnosis. Six other cases only of primary gigantic melanoma without regional or systemic metastases have been described in medical literature. A 90-year-old woman presented to our Plastic Surgery Department with a six years history of a 13.2 × 12.0 cm melanoma growing on her left cheek. No metastasis has been described by CT or PET. This gigantic melanoma of the cheek demonstrated to be only locally aggressive. A wide excision appeared to be resolutive to the histological and immunostain (Melan-A, S-100) analysis.

Melanomas classification is inflexibly changing course to reclassify melanomas subtypes based on genetic profiles. Not enough data to review classification are available but this and other cases reviewed suggest the existence of giant melanomas typical features: gigantic melanomas appear not necessarily correlated to objective distant aggressiveness and poor outcome although the presence of many negative prognostic factors (Breslow's depth, size, exophytic growth, ulceration).

Introduction

Gigantic primary melanoma is a rare observation in clinical practice. Few cases have been reported in medical literature. Large melanomas generally have a poor prognosis because of the high risk of extensive metastatic disease at the diagnosis [1]. According to our literature review six other cases only of primary giant melanoma without regional or systemic metastases have been described and only one of these deals with the facial region [2]. Moreover this clinical case demonstrated an unconventional clinical behavior of the gigantic melanoma which was remarkable to be described.

Case Report

A 90-year-old woman presented to our Plastic Surgery Department with a six years history of an asymptomatic growth on her left cheek (Figure 1). She and her family neglected the problem because of the patient's elderly age until the mass began to be a se-

vere problem for her and her family, impeding opening her mouth and chewing.

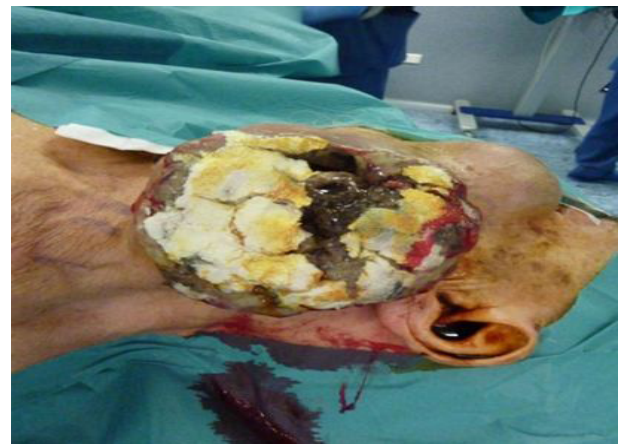

Figure 1: Clinical presentation of the tumour.

Objective structured clinical examination revealed a 13.2 × 12.0 cm malodorous, brown, firm, vegetative mass with necrotic areas covered by purulent exudation. No palpable regional lymph node was identified. Two homolateral laterocervical lymph nodes were enlarged and elastic to palpation. Serum lactate dehydrogenase level was normal.

Total-body positron emission tomography (Figure 2) and computed tomography scan showed no evidence for metastatic disease.

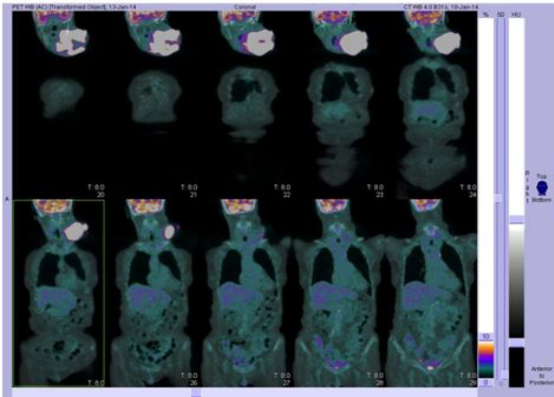


Figure 2: Total-body positron emission tomography scan: note the high metabolic response in the primary melanoma site. Note there is no evidence of systemic metastasis.

After partial endoscopic embolization, the patient underwent wide excision with clear margins extending to the internal mucosa of the mouth and the homolateral cervical lymph nodes (level Ib and II) (Figure 3).

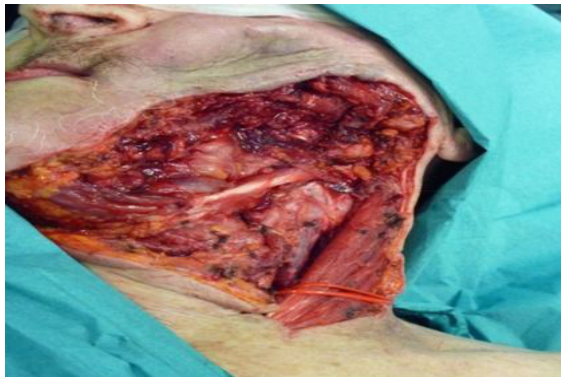

Figure 3: Appearance after wide dissection.

Reconstruction was performed with a Bakamjian deltopectoral flap and a split-thickness skin graft (Figure-4).

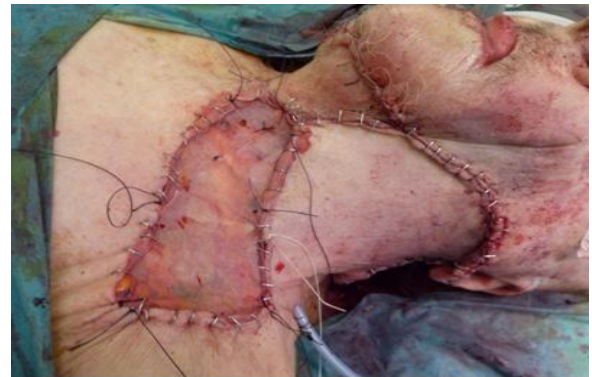

Figure 4: Reconstruction of the defect with local flap and skin graft.

Histological examination of the surgical excision revealed a nodular proliferation of atypical and epithelioid melanocytes positive for Mart-1 and S-100 immunostains. Breslow's depth was 9 cm, Clark level was V, ulceration was positive in some focal areas, and there was no regression signs. All the excisional margins have been histologically tested negative for tumour infiltration by direct microscopic observation and Melan-A, S-100 immunostains. Four mitoses/mm² were identified.

There was no evidence of vascular invasion. One regional lymph node was included in the tumour and macroscopically invaded. The excised homolateral cervical lymph nodes were negative for metastasis by microscopic and immunostains testing.

According to the AJCC TNM staging system, the patient was classified as stage III C disease (pT4b, N1b, M0). Post-operative Total-body positron emission tomography PET and follow-up computed tomography scan confirmed no evidence for metastatic disease.

The patient declined chemotherapy because of her elderly age according with the oncologist. At 6 months' follow-up, the patient was disease free with no clinical evidence of local or distant signs of recurrence. No long term follow up has been possible due to very low rate patient compliance.

Discussion

Few cases of gigantic melanoma have been reported in medical literature. According to the reviewed literature on this topic (Di Meo and associates, and Chong and associates) six others published cases only did not have metastatic disease at the diagnosis [2,3]. Melanoma classification is inflexibly changing course to re-classify melanoma subtypes based on genetic profile. This trend may predict pathologic behavior and outcomes more accurately

than actual histopathologic features.⁴

In the case described, this gigantic melanoma of the cheek was demonstrated to be only locally aggressive, and a wide excision appeared to be the ideal and more effective treatment. Moreover, in this and in all the reviewed cases, the presence of many negative prognostic factors (Breslow's depth, size, exophytic growth, ulceration) did not directly correlate to objective distant aggressiveness or poor outcome and prognosis, as usually happened for smaller conventional nodular melanomas [2-4].

There are not enough data to review classification; anyway these unconventional cases may suggest the existence of gigantic melanomas typical features. For this reason we consider important to share clinical experiences updating information to identify distinct genetic subtypes correlate to gigantic melanoma that, while locally aggressive, appears to lack a propensity for systemic metastatization and gives a much better prognosis despite a terrific clinical presentation.

Acknowledgments

The Authors thank Dr. Mauro Ferraro for his helpful guidance and passionate example during his entire forty years career as a Plastic Surgeon. The authors declare that they have no conflicts of interest to disclose.

References

1. Ching JA, Gould L (2012) Giant scalp melanoma: a case report and review of the literature. *Eplasty* 12: e51.
2. Chong TA, Strazzula L, Hoang MP, Arakaki R, Kroshinsky D (2014) Giant primary melanoma with no apparent metastases: a report of 2 cases. *JAMA Dermatol* 150: 574-575.
3. di Meo N, Stinco G, Gatti A, Errichetti E, Bonin S, Albano A, et al. (2014) Giant melanoma of the abdomen: case report and revision of the published cases. *Dermatol Online J* 15: 20.
4. Chen LL, Jaimes N, Barker CA, Busam KJ, Marghoob AA (2013) Desmoplastic melanoma: a review. *J Am Acad Dermatol* 68: 825-833.