

Research Article

Nipple and Areola Complex Sensitivity Changes after Peri-areolar and Inframammary Incisions for Augmentation Mammoplasty (A Comparative Study)

Yasser Helmy*

Faculty of Medicine, Al-Azhar University, Naser City, Cairo, Egypt

*Corresponding author: Yasser Helmy, Faculty of Medicine, Al-Azhar University, Naser City, Cairo, Egypt. Tel: +00201004406331; Fax: 0020238376114; E-Mail: dryasserhelmy@gmail.com

Citation: Helmy Y (2017) Nipple and Areola Complex Sensitivity Changes after Peri-areolar and Inframammary Incisions for Augmentation Mammoplasty (A Comparative Study). Plast Surg Mod Tech 2: 118. DOI: 10.29011/2577-1701.100018

Received Date: 16 May, 2017; Accepted Date: 26 May, 2017; Published Date: 3 June, 2017

Abstract

Background: Many recent studies are evaluating the aesthetic and adverse outcomes of breast implants with little attention for the skin and nipple sensitivity changes. The purpose of the study is to estimate the incidence of the sensation changes in the nipple and areola skin in patients receiving silicone gel implants, through the two common approach sites.

Materials and Methods: I used 30 pairs of silicone implants for primary retro glandular breast augmentation in 30 patients. The study is designed, after surgery, into two groups, in prospective postoperative follow up. 15 patients who were submitted for peri-areolar incision, (group 1) and 15 patients who were submitted to inframammary incision, (group2). Follow up was done for one year postoperative. The sensation changes were evaluated objectively and subjectively and compared pre-and post- surgery.

Results: The incidence of sensitivity changes in both approaches were 6.6% in group 1, (3.3%) of total numbers of subjects, while they were 10% in group2 (6.6%) of total numbers of subjects. The average resembles 8.3%, at 4 weeks and 6 months. Then this incidence was lowered in both groups at one year to be 0% and 3.33%.

Conclusions: We conclude that, the incidence of nipple and areola skin sensitivity changes is low and almost regained by one year to be 1.66%. Fewer incidences of sensation changes were found when the site of incision is peri-areolar.

Keywords: Breast; Objective; Sensory Assessment; Subjective; Surgical Approaches

Introduction

The preservation of sensitivity of the nipple-areola complex in the breast augmentation is an important achievement in breast surgery. Breast augmentation is one of the most common surgery procedures worldwide. Since many decades, Silicone-gel implants with different manufacturing generations have been used for breast augmentation [1]. Silicon filled-gel implants have been developed using updated technologies for size, shape, texture, and shell layers [2,3]. Planes of implant insertion, operative techniques and adverse outcomes, especially capsular contracture, have been investigated in literature, but few studies have been concerned

with post-operative nipple and skin sensitivity changes [4].

This study reports and compares the incidence of changes in nipple and areola skin sensation, in patients receiving silicone gel implants, in retro-glandular plane, through the two common incision sites, sub mammary and peri-areolar, for primary breast augmentation. The importance of this study is to add some objective observations which haven't been described in literature for the sensitivity of the nipple and areola. Literatures are describing subjective assessments of the sensitivity of the nipple and areola, even in large series recent study [5]. The sensitivity of the nipple is important as an indicator for woman for the ability of her nipple to become erect, sexually satisfied and has erogenous sensation. This makes sense in women satisfaction and self-image, in addition to the pathway for milk ejection reflex. Subjective evaluations for

the degree of the sensory changes have been used in most of studies [5]. Objective assessments of pressure sensation using device was described also for the nipple [6]. Assessment of spinothalamic pathway sensation (pain, temperature and light touch) is well established and reliable clinical screening for the assessments of sensitivity long time ago [7]. So, both subjective and objective methods used are reliable.

Anatomy

Understanding the detailed anatomical facts, [8] about nerve supply of the nipple and areola is essential, [9] as it provides the surgeon direction for dissection. Scanty and contradictory information, about the anatomical details; origin and courses of the sensory nerves which supply the nipple areola-complex, is found in the literature [10,11]. This controversy might attribute the limited number of cadaveric dissection in many literature studies, and this is the result of some bias [12].

A detailed description of the anterior cutaneous branches course has been omitted mostly in the literature, as an important share, in the innervations of the nipple-areola complex, and the two existing studies are controversial [8-13]. Schlenz [12] and his colleagues in Vienna in 2000, carried out a bigger anatomical study dissection for nipple-areola complex on 28 female Caucasian cadavers, they found that; in all cadavers, the nipple-areola complex were innervated by double innervations, lateral and medial, both from the lateral and anterior Cutaneous branches of the 3rd, 4th, or 5th intercostal nerves. (Figure 1).

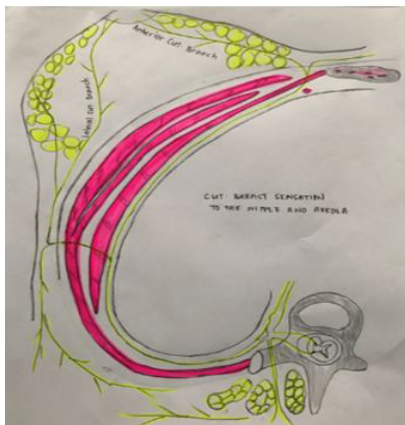


Figure 1: Schematic Drawing of the Breast and The Anterior (ACB) and Lateral Cutaneous Branches (LCB) of the 4th Intercostal Nerve Innervating the Nipple and Areola. Author Drawn It According to Schlenz, et al.

Anatomical Description

In all dissected cadavers, lateral innervations of the nipple-areola complex; is by the 4th lateral Cutaneous branch which was the most common pattern in 93% and in 79 % it was the only lateral supply to the nipple. Its course took a deep plane within the pectoral fascia till the center of the breast and reached the nipple

up to its posterior surface.

The medial innervation of the nipple-areola complex; by the anterior Cutaneous branch of the 3rd, 4th and 5th nerves is either by one nerve only, for example (21.4 % of the study is innervated only by the 4th), or by two nerves with variable combination e.g. (combined innervations by the 3rd and 4th is resembling 57.1% of the study). According Schlenz, et al. study, the innervations took a superficial course, after piercing the fascia in the parasternal line, then divided into a medial branch towards the sternum and a lateral branch for the nipple areola, which courses within the subcutaneous tissue and reached the medial areolar edge in the left breast between 8 and 11 o'clock and in the right breast between 1 and 4 o'clock 9. So, the detailed anatomical concept of double innervation to nipple-areola complex helps in minimizing the risk of sensitivity changes in nipple-areola complex, in variable breast surgery procedures.

Material and Methods

30 female patients underwent retro-glandular augmentation mammoplasty for 60 breasts. Site of incision is decided according to patient request after his detailed discussion with the surgeon about the indications, advantage and disadvantage of each approach. Objective and subjective assessment of the sensitivity of the nipple and areola were establishing pre-surgery and have been recorded as base line data for all patients.

Then, post-operative, two arms, prospective study is designed to involve two comparative groups. First arm is group 1, in which 15 patients (30 breast subjects) were submitted to peri-areolar augmentation mammoplasty approach incision and the second arm is group 2 in which, 15 patients (30 breast subjects) patients were submitted to inframammary augmentation approach incision.

Both groups' subjects were evaluated postoperatively at 4 weeks, 6 months, and 1 year for both objective and subjective examination. Objective evaluation is done for touch, pain and temperature, by the same person (male surgeon) who have doing the pre-operative assessment and the women were asked if they noticed a difference of sensation post surgically. Touch examination was done by a wisp of cotton while the patient is closing her eyes, and covered by dark eye covering, after she was being experienced the cotton's touch sensation in the clavicular skin, then been asked if she feels cotton touch to nipple or not, in terms of yes or no, if yes; the two areas of clavicular and nipple retouched again, then she asked if the intensity of feeling at nipple is equal to the supra-clavicular skin or less. Nipple erection response to touch was noticed, recorded and compared with pre-operative data.

Pain sensation was evaluated by using a pin prick, exactly, by the same technique of touch sensation evaluation. Temperature sensation was evaluated, while the patient is closing her eyes, then

applying one drop of cooled water, then one drop of hot water over the nipple and the patient being asked in each time if she feels cold or hot sensation.

Subjective evaluation was determined in terms; loss of sensation or decreased (anesthesia/hypoesthesia), numbness, unpleasant and abnormal increase sensitivity to stimuli (paresthesia / hyperesthesia). Degrees of paresthesia / hyperesthesia were assessed subjectively in patients own words mild, moderate and severe. Post-operative reporting of sensory changes type, when first occurrence, and resolution status

The data were collected and statistically analyzed using Statistical Package for Social Sciences (SPSS), version 21.0 (SPSS Inc., Chicago, IL, USA). Results were expressed as simple percentage accompanied by qualitative description of comments. Chi-square and Fisher's exact tests were used to compare categorical variables. The significance of differences between the data of the studied groups and the mean and standard deviation values were use t-test. A p-value of 0.05 or less was considered significant.

The study is done between March 2015 and December 2016. Patients were presented with breast size or shape dissatisfaction, asymmetry or ptosis. All cases were operated in the Department of Plastic Surgery, Al-Azhar University Hospitals and private practice. The Ethical committee of Al-Azhar University approved the study protocol and an informed consent was taken from all patients. Pre-operative patient demographics and characteristics in both groups were recorded with intact sensitivity of the nipple and areola in all patients.

Patients' aged from 25-35 with an average age of 30 years. All patients were in BMI range from 20-25. 17 patients were operated for breast augmentation only, and 3 patients were operated for procedure of breast augmentation and abdominoplasty. Exclusion criteria were, in adequate breast tissue, glandular breast atrophy, Poland syndrome, any previous breast surgery or systemic diseases. Patient demographics and characteristics (Table 1).

Characteristics	Peri-Areolar	Infra-Mammary Incision
Patient Distribution		
- Numbers	10	10
- Age (average)	25-35(30)	25-35(30)
- Body mass index (BMI)	20-25	20-25
Marital status		
-Married	6	7
-Single	2	3
-divorced	2	0
Education		
-Collage graduated	7	7

-High school	3	2
-Less than high school	0	1
Product style		
Size	240-420	185-420
-Extra-full projection	6	7
-Full projection	4	3
-Moderate-full projection	0	0
-Low-full projection	0	0

Table1: Patient Demographics and Characteristics in both Groups.

Full history, general and breast examinations and routine investigations were carried up for all patients. Preoperative sensory reporting data of nipple and areola sensation for pain, touch and temperature. All subjects were operated using Silicone gel-filled implants, with the following manufacturing criteria; mammillae texture, Bio-cell pored shell, with average pores diameter of 300 µm (range, 100-600 µm) [4,8] made by (Allergan).

Results

Nipple sensation changes occurred in 5 single subjects from 60 of the study who received various implant styles in retro-glandular plane, at one month postoperative, with the same incidence at 6th months follow up resembling 8.3% total incidence, with 2 breast subject from the peri-areolar incision site (6.6%) in group 1, and (3.3%) of total numbers of subjects, while 3 breast subjects from the inframammary incision site (10%) incidence in group 2, equal (5%) of total numbers of subjects (Table 2).

	Peri-areolar incision (Group1)	Infra-Mammary Incision (Group2)	P value
Total patient NO			
Total subjects of the breasts	15	15	
Incidence of sensory changes in both groups (objective and subjective)	30	30	
Anesthesia	2(6.6%)	3(10%)	
Hyperesthesia	0	0	
Hypoesthesia	1(3.3%)	0	
Paresthesia	1(3.3%)	2(6.6%)	
Right breast	0	1(3.3%)	
Left breast	1(3.3%)	2(6.6%)	
At one year incidence	1(3.3%)	1(3.3%)	
Mean SD of sensory changes	0	1(3.3%)	>0.5
	0.5	0.73	

Table 2: Incidence of Nipple and Areola Complex Sensitivity Changes.

In group1, where the peri-areolar incision, one case was presented with moderate hyperesthesia, and the second with mild hypoesthesia while in group 2, the inframammary incision, one case was presented by feeling mild numbness, paresthesia, and two cases were felt moderate hypoesthesia, but no any case was complained of severe subjective description of sensory changes or complete loss of sensation. This incidence was lowered in both groups at one year to be 0-6.6 %, in the peri-areolar and inframammary approaches subsequently, when the sensation completely regained, at average duration 8-9 months postoperative, in the peri-areolar approach and only one patient of the sub mammary approaches group is still complaining of mild hypoesthesia with total sensory changes of all study subjects equal (1.66%).

I didn't have any report of complete loss of sensation, though in group1, one case (3.3% of the group), was presented with hyperesthesia and one case (3.3% of the group) was presented with hypoesthesia while in group2, 2 cases (6.6% of the group) were presented with hypoesthesia, one case (3.3% of the group) was presented with hyperesthesia. In both groups, 3 subjects (5% of the total sensitivity changes complications) were in the right side while 2 subjects (3.3%) of the total sensitivity changes complications) were finding in left side. (Figures 2-5). Study has no findings for breast size relationship to the changes in the sensitivity of nipple and areola.

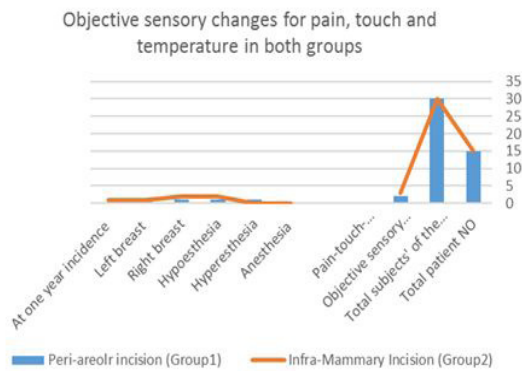


Figure 2: Objective Sensory Changes in Both Groups.

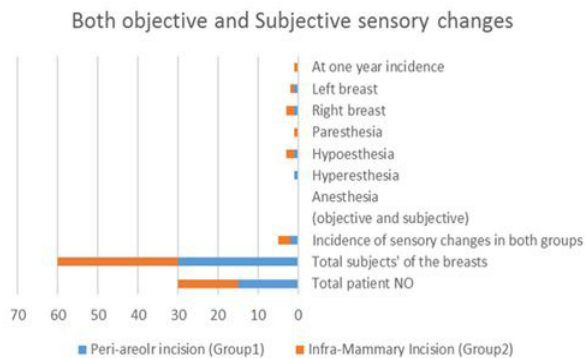


Figure 3: Objective and Subjective Sensory Changes in Both Groups.

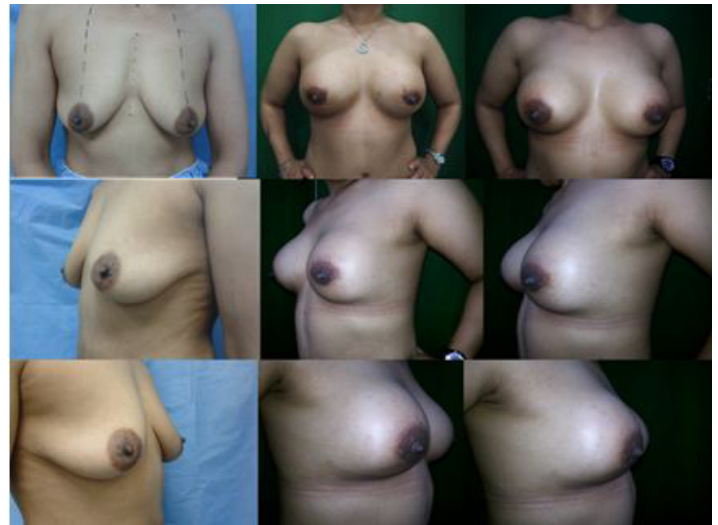

Figure 4: 35 Years old female, submitted for Peri-areolar incision approach for primary augmentation mammoplasty, pre-and post-operative photos at 3m, 6m and 1 year. Above; front views. Middle; left lateral oblique views. Below; Right lateral oblique views.

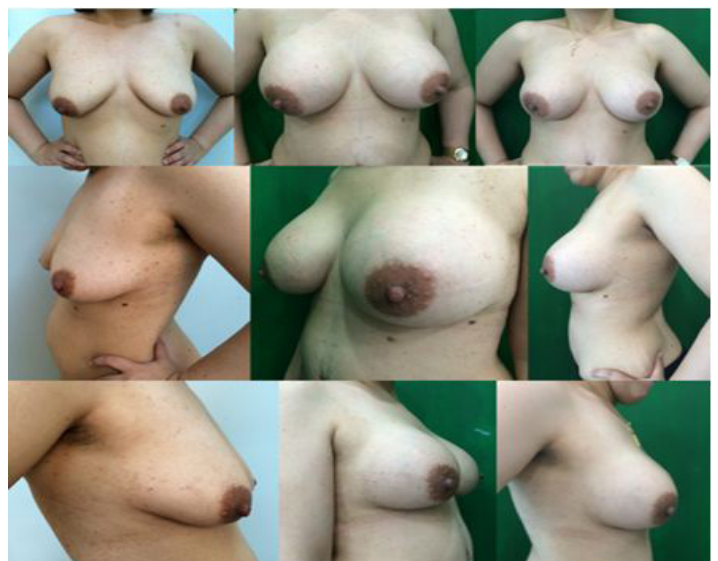

Figure 5: 35 Years old female, submitted for Infra-mammary incision approach for primary augmentation mammoplasty, pre-and post-operative photos at 3m, 6m and 1 year. Above; front views. Middle; left lateral oblique views. Below; Right lateral oblique views.

Discussion

The nerves which supply the nipple-areola complex sensitivity are best protected when surgical dissection is avoided at the base of the breast and skin incisions are not made at medial edge of the areola according to Schlenz, et al. study [12]. Retro mammary augmentation mammoplasty surgery includes pocket creation and dissection at the base of the breast, but fortunately, there are no required incisions at the medial edge of the areola, and that means

preservation of medial nipple-areola complex innervations from anterior Cutaneous branches of the 3rd and 4th nerves.

Sensory changes, as post breast implant complications in nipple and areola complex, are considered in literatures and FDA publications, [14] but they need further detailed analysis and descriptions so we learn how to avoid it as much as we can. My study finding demonstrate, low risk of incidence of the sensation changes 1.66%, after one year in the nipple and areola skin in patients receiving silicone gel implants, by the two common approach sites, for primary breast augmentation. This finding differs with the very low incidence 0.1% which came from Herluf, et al. [5], in 2016 when they did retrospective study on 4927 Subjects, but their study was carried out on review of 10 years' record follow up, and this wide scale and long term follow up may explains the very low incidence.

However, these study findings are showing complete sensory regain within 7-9 months, with 0% incidence of sensory changes after one year, in the peri-areolar approach and 3.3% incidence in the sub mammary approach. This finding is partially agreeing to Herluf, et al. where the proportion achieved resolution of that changes, in range from 100% to 33.3%, and they mentioned approximately 50% sensation changes have been resolved between 7 and 8 months. A study by Mofid, et al. [15] was concluded no impact of difference between certain incision sites and the outcomes on nipple-areola sensitivity changes, in controversy for our findings.

This study shows that the peri-areolar incision site is less results in sensory changes and this result comes in the site of study done by Okwueze, et al. [6] which showed that the peri-areolar incision is less affecting the lower pole of the breast in comparison with the inframammary incision, and this study finding is similar to Herluf, et al.[5] finding's which showed a slightly greater risk of nipple sensation changes in the inframammary cohort than in the peri-areolar one, where there was no risk, this result totally agrees with my study when the incidence of nipple-areola sensitivity is found in our study to be 0% at one year in group submitted for peri-areolar incision approaches.

My study showed that the majority of sensation regained within 7-9 months, but previous studies, showed that sensory impairments improved within 3 to 6 months of surgery [6,15,16], not after that, but supportive findings for my results are coming from another study [5] and agreeing with my results, when sensation changes experienced within 6 months of procedures and were resolved mostly at 8-9 months.

Reports about the relation between breast size and the sensation, in the nipple-areolar complex are concluding that; patients with small to normal size breasts, are having better sensation outcomes more than women with larger breasts, [14,16] and this find-

ing is correlated with our study results when I used implant's sizes ranged from 185-420cc. The sensitivity of the nipple is important as an indicator for woman for the ability of her nipple to become erect, sexually satisfied and has erogenous sensation. This makes sense in women satisfaction and self-image, in addition to the pathway for milk ejection reflex. Inframammary approach has a better outcome for breast-feeding, because of less mammary ducts injuries during the dissection when it is compared with pre-areolar incision, but this observation needs further studies.

Conclusion

This study provided objective and subjective incidence of nipple and areola skin sensitivity changes. These changes are low and almost regained by one year to be equal or less than 1.66%. Changes in nipple-areola sensation that occurred were mostly resolved within 7-9 months. Fewer incidences of sensation changes was found when the sites of incision are peri-areolar.

Acknowledgment

For my daughter, MS Tasnim Ali, for her support in editing, for MS Aida Muratovic for her reviewing and my assistant Mrs. AnalizaBonefecio.

References

1. Jewell ML (2012) Silicone gel breast implants at 50 the state of the science. *Aesthet Surg J* 32:1031-1034.
2. Hedén P (2011) Breast augmentation with anatomic, high cohesiveness silicone gel implants (European experience) In: Spear SL, Willey SC, Robb GL, Hammond DC, Nahabedian MY (3rd edn) *Surgery of the Breast: Principles and Art* Philadelphia, PA: Lippincott, Williams and Wilkins: 1322-1345.
3. Heden P (2012) Cohesive gel breast implants. In: Peters W, Brandon H, Jerina KL, Wolf C, Young VL (2012) *Biomaterials in Plastic Surgery*. Cambridge, United Kingdom: Wood head Publishing Limited: 68-95.
4. Maxwell GP, Van Natta BW, Murphy DK, Slicton A, Bengtson BP (2012) Natrelle style 410 form-stable silicone breast implants core study results at 6 years. *Aesthet Surg J* 32: 709-717.
5. Lund HG, Turkle J, Jewell ML, Murphy DK (2016) Low Risk of Skin and Nipple Sensitivity and Lactation Issues After Primary Breast Augmentation with Form-Stable Silicone Implants: Follow-Up in 4927 Subjects. *Aesthet Surg J* 36: 672-680.
6. Okwueze MI, Spear ME, Zwyghuizen AM, Braun SA, Ajmal N, et al.(2006) Effect of augmentation mammoplasty on breast sensation. *Plast Reconstr Surg* 117: 73-83.
7. Wolf J (1981) *Segmental Neurology A guide for the examination and interpretation of sensory and motor functions*. University Park press Baltimore: 1-160
8. Sarhadi NS, Dunn JS, Lee FD, Soutar DS (1996) An anatomical study of the nerve supply of the breast, including the nipple and areola. *Br J Plast Surg* 49: 156-164.

Citation: Helmy Y (2017) Nipple and Areola Complex Sensitivity Changes after Peri-areolar and Inframammary Incisions for Augmentation Mammoplasty (A Comparative Study). *Plast Surg Mod Tech* 2: 118. DOI: 10.29011/2577-1701.100018

9. Jaspars JJ, Posma AN, van Immerseel AA, Gittenberger-de Groot AC (1997) The cutaneous innervation of the female breast and nipple-areola complex Implications for surgery. *Br J Plast Surg* 50: 249.
10. Farina MA, Newby BG, Alani HM (1980) Innervation of the nipple-areola complex. *Plast Reconstr Surg* 66: 497.
11. Jäger K, Schneider B (1982) The innervation and perfusion of the nipple with regard to perimamillary incision. *Surgeon* 53: 525.
12. Schlenz I, Kuzbari R, Gruber H, Holle J (2000) The Sensitivity of the Nipple-Areola Complex: An Anatomic Study. *Plast Reconstr Surg* 105: 905-909.
13. Craig RD, Sykes PA (1970) Nipple sensitivity following reduction mammoplasty. *Br J Plast Surg* 23: 165-172.
14. US FDA. Breast implant complications. In: Breast Implant topic at FDA official web.
15. Mofid MM, Klatsky SA, Singh NK, Nahabedian MY (2006) Nipple-areola complex sensitivity after primary breast augmentation a comparison of periareolar and inframammary incision approaches. *Plast Reconstr Surg* 117: 1694-1698.
16. Slezak S, Dellon AL (1993) Quantitation of sensibility in gigantomastia and alteration following reduction mammoplasty. *Plast Reconstr Surg* 91: 1265-1269.