

Case Report

Granulomatosis with Polyangiitis (Wegener's) Masquerading as Non-Resolving Pneumonia

Ganesh Kalyanasundaram^{1*}, Poh Yong Tan², Nilesh H Pawar¹, Aza A Taha³

¹Department of Internal Medicine, Sengkang General Hospital, Singapore

²Department of Internal Medicine, Singapore General Hospital, Singapore

³Department of Respiratory Medicine, Changi General Hospital, Singapore

***Corresponding author:** Ganesh Kalyanasundaram, Department of Internal Medicine, Sengkang General Hospital, Level 9, Medical Centre, 110 Sengkang East Way, Singapore. Tel: +6594883040; Email: ganesh.kalyanasundaram@singhealth.com.sg

Citation: Kalyanasundaram G, Tan PY, Pawar NH, Taha AA (2019) Granulomatosis with Polyangiitis (Wegener's) Masquerading as Non-Resolving Pneumonia. Curr Trends Intern Med 3: 117. DOI: 10.29011/2638-003X.100017

Received Date: 24 December, 2018; **Accepted Date:** 31 December, 2018; **Published Date:** 08 January, 2019

Introduction

Non-resolving pneumonia (NRP) includes those cases of presumed pneumonia that progress, resolve slowly, or fail to achieve complete resolution despite appropriate treatment [1]. Granulomatosis with Polyangiitis (GPA), previously known as Wegener's granulomatosis is a multi-system disorder characterized by systemic necrotizing vasculitis which most commonly affects the small and medium vessels of the upper and lower respiratory tract and the kidneys [2,3]. Diagnosis of GPA requires a high index of suspicion, as the initial presentation is usually non-specific, and most patients are usually diagnosed around 3-12 months from the onset of symptoms [4]. We present a case of a patient with non-resolving pneumonia who was eventually diagnosed with GPA.

Case Presentation

A 34-year-old Indian female with no past medical history presented with a three-day history of fever, right-sided pleuritic chest pain and cough with whitish sputum. She had no history of weight loss or night sweats. There was also no recent travel or sick contacts. On examination, she was alert and comfortable. She was afebrile, heart rate was 88 beats per minute, blood pressure was 103/62 mm Hg and pulse oximetry was 98 % on ambient air. She did not have any cervical lymphadenopathy or clubbing. On auscultation, her lung sounds were normal and air entry was equal on both sides. Results of laboratory investigations showed hemoglobin of 12.4mg/dl, elevated White Blood Cells (WBC) count of 14500 cells/microliter, with left shift. C-Reactive Protein (CRP) was elevated (284mg/l). Renal and liver function tests were normal. Chest X-ray at Figure 1 demonstrated a round mass like opacity in the right middle and lower zones.

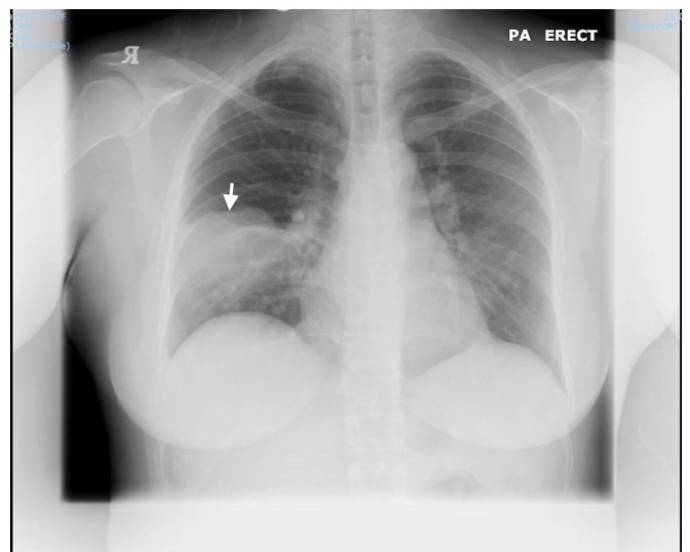


Figure 1: Chest X-ray showing a round mass like opacity in the right middle and lower zones.

Blood cultures were negative for bacterial growth and urine investigations showed that there was no evidence of legionella and pneumococcal antigens. She was initially diagnosed with community acquired pneumonia and was prescribed with a course of augmentin and clarithromycin. The patient didn't respond to the initial treatment. Instead she presented 10 days later with recurrent fever, persistent cough and new onset hemoptysis. She also had nasal congestion with purulent discharge. Physical examination was unremarkable except for fever. Repeat CXR showed persistence

of right middle lobe consolidation. Sinus X-ray shown in Figure 2 had demonstrated opacification of the left maxillary sinus with air fluid level suggestive of sinusitis. Laboratory evaluation revealed a hemoglobin of 11.6mg/dl, WBC count of 15000 cells/microliter, CRP was unchanged at 286mg/l and no bacterial growth on both blood and sputum cultures. Two sets of sputum smears and cultures for acid fast bacilli were also negative.

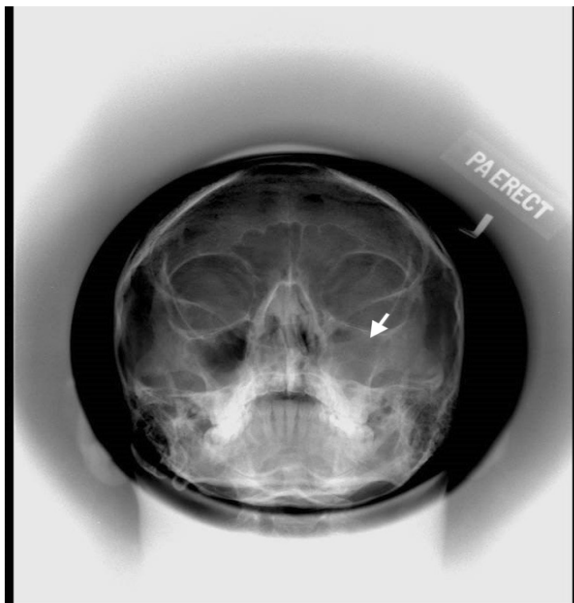


Figure 2: Sinus X-ray showing opacification of the left maxillary sinus with air fluid level (white arrow).

Renal function test was normal although urine microscopy revealed a red blood cell count of 35 cells/microliter with no pyuria or casts and urine culture was negative. She was discharged after being prescribed a course of moxifloxacin. She was still complaining of cough two weeks later and had nasal discharges. In addition, she noticed that both eyes were irritable, red and watery. Upon physical examination, she was found to have bilateral erythematous conjunctiva. Slit lamp examination revealed bilateral diffuse anterior scleritis. Chest X-ray showed mild reduction in size of the right middle zone consolidation with gas lucencies over the opacity suggestive of cavitation, along with left upper lobe collapse (figure 3).

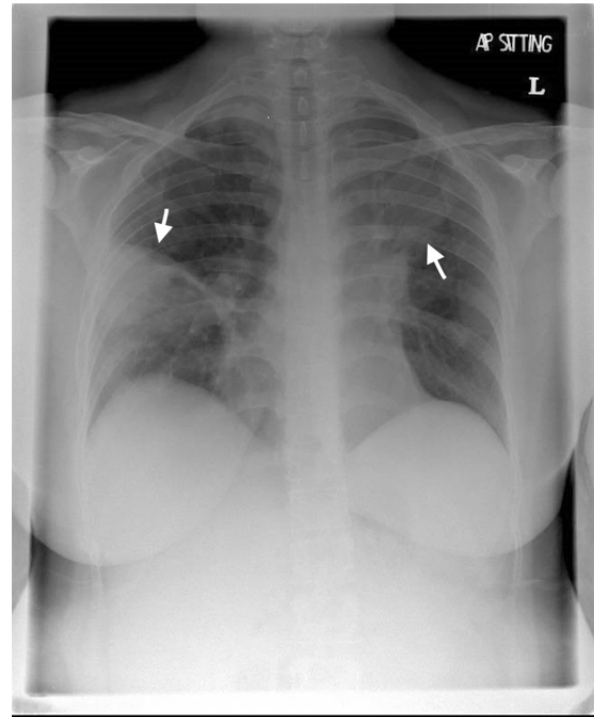


Figure 3: Chest X-ray showed mild reduction in size of the right middle zone consolidation with gas lucencies over the opacity suggestive of cavitation (downward arrow), along with left upper lobe collapse (upward arrow).

In view of these findings, Computed Tomography of the chest (Figure 4-6) was performed which showed consolidation and nodular pulmonary lesions with cavitation of the middle lobe consolidation associated with left hilar and mediastinal adenopathy. We proceeded with Transbronchial biopsy of the right lung mass which showed infarcted tissue with presence of multi nucleated giant cells and ill formed granulomas. Acid fast bacilli (AFB) smear and tuberculosis culture were negative from bronchoalveolar lavage and transbronchial biopsy. Autoimmune screen was positive for anti-proteinase3 and Cytoplasmic Antineutrophil Cytoplasmic Antibodies (C-ANCA). The patient had a renal biopsy done, which showed diffuse crescentic glomerulonephritis with focal segmental sclerosis that is consistent with pauci-immune etiology. Nerve conduction study was done as she had left leg numbness which

showed mono neuritis multiplex in left posterior tibial nerve. A diagnosis of Granulomatosis with Polyangiitis (GPA) was hence made, with cumulative manifestations of granulomatous lung inflammation, left maxillary sinusitis, pauci-immune GN, and mononeuritis multiplex..

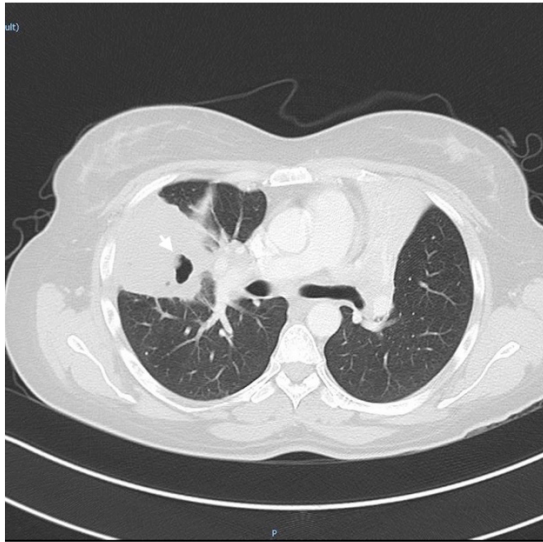


Figure 4: CT thorax shows consolidation and nodular pulmonary lesions with cavitation of the middle lobe consolidation (white arrow).

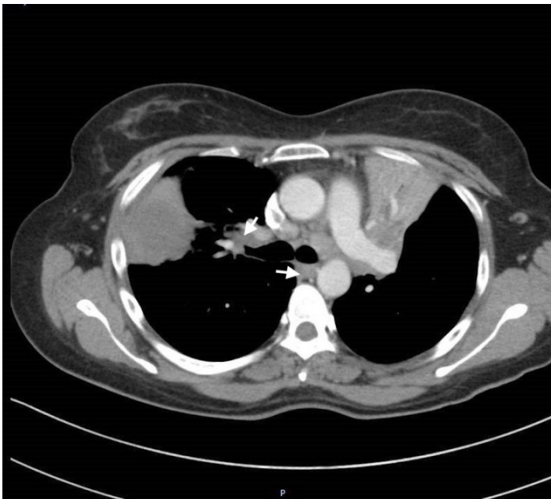


Figure 5: CT Thorax with mediastinal cuts showing enlarged mediastinal lymph nodes (white arrows).

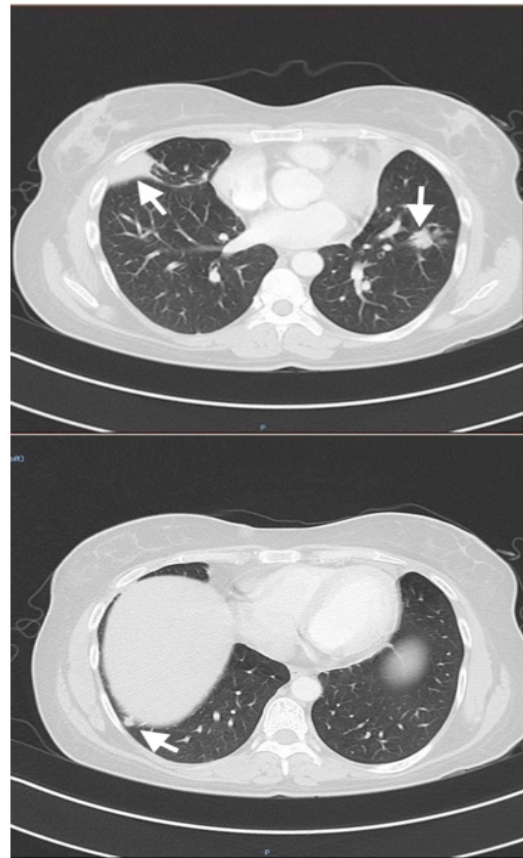


Figure 6 a, b: CT showing multiple nodules over both lung bases (white arrows).

Discussion

Patients with Community Acquired Pneumonia (CAP) should be evaluated within 72hrs of antimicrobial treatment. Treatment failure (TF) in CAP is defined as a clinical condition with inadequate response to antimicrobial therapy [1]. Treatment failure occurs in 10 to 15% of patients with CAP [2]. Patients with CAP are expected to achieve clinical stability in terms of normalization of temperature, hemodynamic parameters and oxygen saturation within 72 hrs. of antibiotic therapy [3]. Among those with treatment failure two patterns were observed. Some develop progressive pneumonia causing respiratory failure and septic shock within first 72hrs and some develop non-resolving pneumonia (NRP) if persistence of fever and clinical symptoms without achieving

clinical stability [4]. Our patient had NRP as she didn't respond to initial therapy. The causes can be broadly classified into two groups. Infectious and non-infectious causes. 40% of the causes are attributable to infections which may be primary, persistent or nosocomial infections [5].

Approximately 20 percent of presumed NRP is due to non-infectious causes [6]. In this group further radiologic studies, non-invasive samples, and Bronchoscopy should be performed to evaluate the lungs and to obtain samples for microbiological tests and other studies. It was challenging to diagnose granulomatosis with polyangiitis in this patient with NRP. With Singapore being one of the south-east Asian countries which harbor one third of the world's TB cases, tuberculosis should be one of the main differential diagnosis [7]. Friedrich Wegener in the late 1930s, described a syndrome characterized by chronic rhinitis and renal failure with histologic features of granulomatous necrotizing inflammation [8]. The new name, granulomatosis with Polyangiitis (GPA), reflects the pathologic basis of the disease. It is a multi-system vasculitis that primarily involves small and medium vessels of the upper and lower respiratory tracts and kidneys. Pulmonary Wegener's granulomatosis can present with multifocal lung involvement or solitary lung lesions with no evidence of extra pulmonary disease [9]. American college of Rheumatology/European league against rheumatism (ACR/EULAR) Provisional Classification Criteria for GPA states the presence of c-ANCA and PR3-ANCA antibodies score of 5, Bloody or nasal discharge or other nasal symptoms or a granuloma on biopsy were both given a score of 3. Lung nodules, a mass or cavity on chest imaging were scored 2, or if there was cartilaginous involvement. Loss or reduction in hearing or if the patient had red or painful eyes were given score of 1. High eosinophil count and nasal polyps were given negative scores (-3 and -4, respectively). A score of 5 or more is suggestive of GPA [10].

The granulomatous inflammatory process can destroy the septum and cause saddle nose deformity. Trachea, bronchi, and lung parenchyma can be affected. Later, the disease progresses to a more vasculitis stage heralded by constitutional symptoms. At this stage, arthralgia, cutaneous vasculitis, and mono neuritis or polyneuritis can take place. More than 70% of patients will have renal involvement as a result of necrotizing glomerulonephritis [11,12]. CT scan aids in diagnosing the patient at the initial presentation, and the most common features are multi nodular lesion, seen in 90% of the patients [13]. Our patient had involvement of lung, nasal sinuses, kidney, eyes, and nerves fulfilling ACR/EULAR provisional criteria. CT scan of our patient showed a multi nodular lesion with consolidation. Approximately 82% to 94% of patients with either GPA or MPA have a positive ANCA, depending upon severity of disease [14,15]. GPA is primarily associated with PR3-ANCA. Renal involvement is common in GPA and Microscopic Polyangitis [16,17]. In studies from the National Institutes of Health (NIH) in the United States, evidence of glomerulonephritis was present in only 18% of patients at presentation of symptoms

[15], but glomerulonephritis subsequently developed in 77% to 85% of patients, usually within the first two years of disease onset [16].

Treatment recommendations in GPA includes induction of remission with Rituximab or Cyclophosphamide (CYC) and steroids and maintenance with Azathioprine or steroids or Mycophenolate mofetil [17]. Our patient was started on pulse CFC 750mg once and pulse Methylprednisolone 1 gram for three days followed by oral CYC and prednisolone. Her symptoms resolved following initiation of steroid and CYC. Her CYC was stopped 4 months later but Prednisolone was continued at tapering dose for 2 years and was switched to Azathioprine 100mg once daily. She has remained in full remission over 2 years on azathioprine with no flares.

Conclusion

Multitude of GPA-induced manifestations presents significant diagnostic challenges and clinicians need to have high index of suspicion, especially if pneumonia does not resolve with appropriate antibiotics and a given timeline. If clinically indicated further evaluation such as bronchoscopy should be considered as part of work up in patients with non-resolving pneumonia.

References

1. Menendez R, Torres A (2007) Treatment failure in community-acquired pneumonia. *Chest* 132: 1348-1355.
2. Falk RJ, Gross WL, Guillevin L, Hoffman GS, Jayne DR, et al. (2011) Granulomatosis with polyangiitis (Wegener's): an alternative name for Wegener's granulomatosis. *Arthritis Rheum* 63: 863-864.
3. Jennette JC, Falk RJ (1997) Small vessel vasculitis. *N Engl J Med* 337: 1512-1523.
4. Abdou NI, Kullman GJ, Hoffman GS, Sharp GC, Specks U, et al. (2002) Wegener's granulomatosis: survey of 701 patients in North America. changes in outcome in the 1990s. *The Journal of Rheumatology* 29: 309-316.
5. Menendez R, Torres A (2003) Risk factors for early and late treatment failure in community-acquired pneumonia. *Am J Respir Crit Care Med* 167: A560.
6. Halm EA, Fine MJ, Marrie TJ, Coley CM, Kapoor WN, et al. (1998) Time to clinical stability in patients hospitalized with community-acquired pneumonia: implications for practice guidelines. *JAMA* 279: 1452-1457.
7. Nair N, Wares F, Sahu S (2010) Tuberculosis in the WHO South-East Asia Region *Bulletin of the WHO* 88: 164.
8. Wegener F (1939) Ueber eine eigenartige rhinogene Granulomatose mit besonderer Beteiligung des Arteriensystems und der Nieren. *Beitr Pathol Anat* 102: 36.
9. Holle JU, Gross WL, Holl-Ulrich K, Ambrosch P, Noelle B, et al. (2010) Prospective long-term follow-up of patients with localized Wegener's granulomatosis: does it occur as persistent disease stage?. *Ann Rheum Dis* 69: 1934-1939.

10. Luqmani R, Merkel PA, Watts R (2016) New classification criteria for ANCA-associated vasculitis: implications for clinical practice. In: Proceedings of the ACR/ARHP Annual Meeting, J Robson (Ed.), Washington, DC, USA.
11. Jennette JC, Falk RJ (1997) Small vessel vasculitis. *N Engl J Med* 337: 1512-1523.
12. Lee KS, Kim TS, Fujimoto K, Moriya H, Watanabe H, et al. (2003) Thoracic manifestation of Wegener's granulomatosis: CT findings in 30 patients. *Eur Radiol* 13: 43-51.
13. Guillevin L, Durand-Gasselin B, Cevallos R, Gayraud M, Lhote F, et al. (1999) Microscopic polyangiitis. *Arthritis Rheum.* 1999; 42: 421-430.
14. Finkelstein JD, Lee AS, Hummel AM, Viss MA, Jacob GL, et al. ANCA are detectable in nearly all patients with active severe Wegener's granulomatosis. *Am J Med* 120: 643.
15. Hoffman GS, Kerr GS, Leavitt RY, Hallahan CW, Lebovics RS, et al. (1992) Wegener granulomatosis: an analysis of 158 patients. *Ann Intern Med* 116: 488-498.
16. Fauci AS, Haynes BF, Katz P, Wolff SM (1983) Wegener's granulomatosis: prospective clinical and therapeutic experience with 85 patients for 21 years. *Ann Intern Med* 98: 76-85.
17. Stone JH, Merkel PA, Spiera R, Seo P, Langford CA, et al. (2010) Rituximab versus cyclophosphamide for ANCA-associated vasculitis. *N Engl J Med* 363: 221-232.