

Case Report

Pancreatic Heterotopia

Daniel Farishta^{1*}, Justin Noroozian¹, Aakash Gajjar², Suimin Qiu³

¹School of Medicine, University of Texas Medical Branch at Galveston, USA

²Department of Surgery-General Surgery, University of Texas Medical Branch at Galveston, USA

³Department of Pathology, University of Texas Medical Branch at Galveston, USA

***Corresponding author:** Daniel Farishta, University of Texas Medical Branch at Galveston, 402 Post Office, St. #219 Galveston, TX 77550, USA, Tel: +763 732-8454, Fax: +936 560-1818, Email: dzfarish@utmb.edu

Citation: Daniel F, Noroozian J, Gajjar A, Qiu S (2016) Pancreatic Heterotopia. A Cas Rep 2016: G131. DOI: 10.29011/2574-7754/100031

Received Date: 01 December, 2016; **Accepted Date:** 15 December, 2016; **Published Date:** 23 January, 2017

Abstract

Pancreatic heterotopia is a rare condition of the gastrointestinal system where pancreatic tissue is found outside of the normal anatomic location. When present, it is usually asymptomatic until obstruction of the gastrointestinal tract occurs. In this report, a 35-year-old female has an unusual presentation of pancreatic heterotopia, which includes abdominal pain and unintentional weight loss. The workup for differential and treatment is discussed.

Keywords: Abdominal pain; Heterotopia; Pancreas; Unintentional weight loss

Case Report

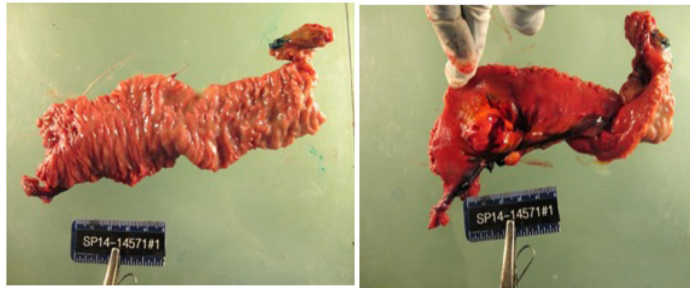A previously healthy, 35-year-old, African-American female presented to clinic complaining of abdominal pain and 30-pound unintentional weight loss. She was in her usual state of health until one month prior. At onset, the pain was cramping in nature and located in bilateral lower quadrants with radiation to her low back and pelvis. At the time of our visit, the pain had progressed to involve the abdomen diffusely. She reported associated loss of appetite, with intermittent nausea. She denied any vomiting, diarrhea, constipation, gastrointestinal blood loss, or systemic symptoms such as fever, chills, night sweats, or malaise.

Review of her medical record during our initial encounter revealed significant workup done during the one month she had experienced symptoms. At initial onset of symptoms, she had sought care in the Emergency Department (ED), where she had Computed Tomography (CT) of the abdomen with Intravenous (IV) and oral contrast. This revealed a 1.1x1.4cm focus of enhancement among crowded loops of jejunum in the Left Upper Quadrant (LUQ). Unfortunately, a lack of intraluminal contrast in this segment limited examination of the nearby jejunum. An Esophago Gastro Duodenoscopy (EGD) and colonoscopy were performed by an outside gastroenterologist. A hiatal hernia and antral erythema were found. Random biopsies of the duodenum found normal villi with evidence of chronic inflammation. Gastric biopsies identified chronic gastritis without activity and no evidence of *Helicobacter pylori*. Colonoscopy was grossly normal. A CT enterography was ordered

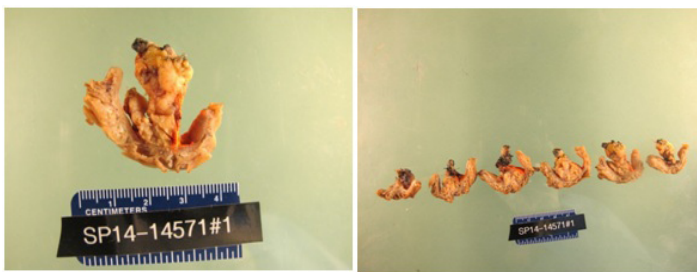and again identified the lesion, which measured 2.0x1.8x1.5cm. The mass was ill-defined, hyper attenuating, mesentery based, and caused tethering of bowel loops in the vicinity.

At our evaluation her labs revealed a Hemoglobin (Hgb) of 11.9g/dL, Mean Corpuscular Volume (MCV) of 88.2fL, White Blood Cells (WBC) of 7,600/ μ L with a normal differential, and platelets of 293,000/ μ L. Blood chemistries were normal. Aspartate aminotransferase (AST) was 14U/L, alanine aminotransferase (ALT) was 16U/L, and alkaline phosphatase was 95U/L, all normal. Her lipase was not elevated, at 44U/L. She was referred for surgical resection.

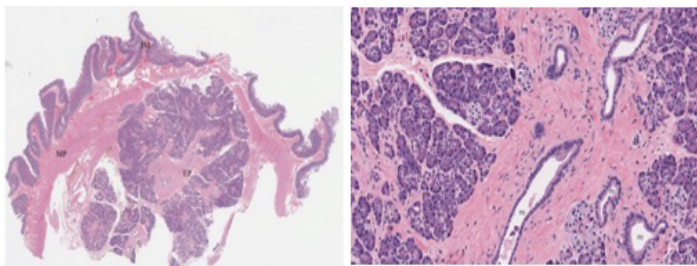
At her surgical evaluation she reported diarrhea, thus chromogranin A and twenty-four-hour urine 5-HydroxyIndolAcetic Acid (5-HIAA) were checked and found to be normal. She then proceeded to surgery for exploratory laparotomy during which time the mass was excised. A 23cm long by 4cm diameter segment of jejunum was removed, with a well-circumscribed, tan-yellow, soft, lobular nodule identified in the mesentery adjacent to small bowel muscle layer which measured 2.0x2.0x1.5cm. This is shown by gross pathology images provided (Figures A-B). Gross microscopic examination identified the pathologic lesion (Figure C-high power, Figure D-low power). Histologic examination revealed a well demarcated 2cm Ectopic Pancreatic tissue (EP) beneath the Jejunum Mucosa (JM) or around the Muscularis Propria (MP) of the jejunum (Figure E-low power). High magnification showed the ectopic pancreatic tissue contained both exocrine acinar component (PA) and endocrine Pancreatic Islets (PI) with normal but dilated Pancreatic Ducts (PD) (Figure F-high power).



Figures A: Gross pathology image. Figures B: Gross pathology image.



Figures C: Gross microscopic examination identified the pathologic lesion- high power. Figures D: Gross microscopic examination identified the pathologic lesion- low power



Figures E: Histologic examination of Jejunum Mucosa- low power. Figures F: High magnification of ectopic pancreatic tissue high power.

After the operation, she recovered uneventfully. By her two-week follow-up appointment, she was tolerating foods and fluids without difficulty, had normal bowel movements, and did not have fever, tenderness, redness, nor discharge. Her dermabond was in place and the wound had well approximated edges.

Discussion

Pancreatic heterotopia was first characterized by Jean Schultz in 1729 and is defined as any pancreatic tissue found outside the location of the normal pancreas. It is believed to arise during embryologic formation of the pancreas and is most commonly found in the stomach, duodenum, and jejunum, with rare cases identified in the biliary tree, gallbladder, spleen, esophagus, colon, mediastinum, and Meckel's diverticulum. It has a very low incidence rate overall, found in 0.11%-0.21% of all autopsies, and has a male to female ratio of 3:1. The stomach, jejunum or duodenum is involved in over 90% of cases, having an average diameter of 1-2cm. Despite its rarity, pancreatic heterotopia should still be considered as a cause for bowel intussusception and obstruction, along with other small bowel lesions such as Gastro Intestinal Stromal Tumors (GIST). Pancreatic heterotopia can be difficult to distinguish from GIST and metastatic tumors, and while endosonography may be helpful, it can only be definitively diagnosed by histopathological examination. The majorities of cases are asymptomatic and found incidentally during abdominal surgery for other conditions, but patients may present with abdominal pain, distention, or other signs of bowel obstruction. Rarely, patients can present with acute or chronic pancreatitis involving the heterotopic pancreas. Case reports also exist of adenocarcinoma arising in a heterotopic rest. Medical treatment has not proven effective for pancreatic heterotopia and surgical resection is the only curative option.

Conclusion

Although pancreatic heterotopia is a rare condition, it should remain in the differential diagnosis for unintentional weight loss and abdominal pain.

References

1. Yan M-L, Wang YD, Tian YF, Lin Y (2012) Pancreatic Heterotopia, Adenocarcinoma arising from intrahepatic heterotopic pancreas: A case report and literature review. *WJG* 18: 2881-2884.
2. Seo N and Kim JH (2014) Pancreatic Heterotopia, Characteristic CT features of heterotopic pancreas of the mesentery: "another pancreas" in the mesentery. *Clin Imaging* 38: 27-30.