

Case Report

Ewing's Sarcoma in Young Malian: A Case Report

Boureima Kodio^{1*}, Ibrahim S Pamanta¹, Hamsatou Cissé², Sidi Touré¹, Fatoumata Diakité¹, Seydou Diallo¹, Fanta Sangaré¹, Idrissa Ah Cissé¹

¹Department of Rheumatology, Point-G University Teaching Hospital of Bamako, Mali

²Department of Infectious and Tropical Disease, University Teaching Hospital of Kati, Mali

***Corresponding author:** Boureima Kodio, Department of Rheumatology, Point-G University Teaching Hospital of Bamako, Mali. Tel: +23375791055; Email: boureimakodio@gmail.com

Citation: Kodio B, Pamanta IS, Cissé H, Touré S, Diakité F, et al. (2018) Ewing's Sarcoma in Young Malian: A Case Report. Acad Orthop Res Rheum 2: 109. DOI: 10.29021/2688-9560.100009

Received Date: 29 January, 2018; **Accepted Date:** 02 February, 2018; **Published Date:** 14 February, 2018

Abstract

Ewing sarcoma is a primary malignant bone tumour rarely observed in black populations. We report a case of Ewing sarcoma in a 20-year-old boy manifested by painful swelling of the left shoulder with functional impotence evolving for 2 years. The patient was transferred for care to the Rheumatology Department of Point G University Teaching Hospital on February 13, 2012. The diagnosis of Ewing's sarcoma with vertebral (L1) metastasis was retained after a bone biopsy pathological examination.

Keywords: Ewing's sarcoma; Humerus; Malian

Introduction

Described by James Ewing in 1921, Ewing's Sarcoma is the second most common primary bone tumour after osteosarcoma, accounting for 3 % of all childhood malignancies [1] typically affecting the trunk and long bones? It usually affects children mostly male of 5-30 years of age with a peak of incidence between 10 and 15 years. Ewing's sarcoma is rarely observed in black populations [2]. Rarely, 1%-2% of Ewing sarcomas may involve epiphysis [3]. We present a case of Ewing's sarcoma of the proximal humeral epiphysis in a 20 -year- old boy.

Case Report

It is O.F, 20-year-old farmer with no known surgical history treated for 3 weeks with anti-tuberculosis drugs for probable humeral mycobacterium osteomyelitis. He is referred and hospitalized in the Rheumatology Department of Point G University Teaching Hospital on February 13, 2012, for a pyretic painful swelling of the left shoulder with functional impotence evolving for 2 years. He also suffered from low back pain and deterioration of the general condition.

On examination, there was a marked increase in the soft tissue swelling in the left shoulder with severe tenderness (Figure 1) at the level of the spine we noted a dorsal gibbosity and marked lumbar spinal syndrome with a schöber index at 10± 2cm without

neurological deficit. The weight loss was 3 kg.

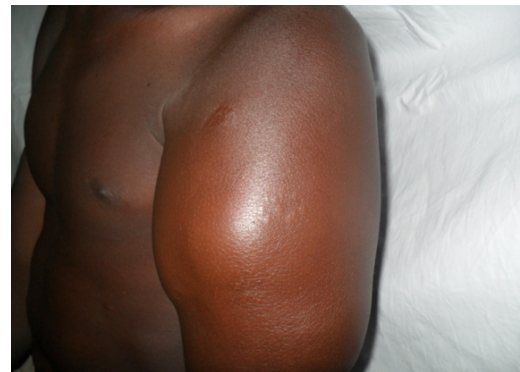

Figure 1: Soft tissue swelling in the left shoulder with severe tenderness.

Biology included inflammatory anaemia, CRP> 15 mg/L, accelerated ESR at 80 mm, hypocalcaemia at 2.7 mmol/L and hyperuricemia at 449 µmol/L. The myelogram was normal. Tuberculosis research was negative. Liver and renal functions were normal.

Radiograph revealed lytic lesion within the right proximal humeral epiphysis, a periosteal reaction in grass fire with soft tissues invasion (Figure 2) and vertebral (L1) osteolytic images were also noted. The chest X-ray was normal. Ultrasound of the left shoulder shows collected deltoid myositis.

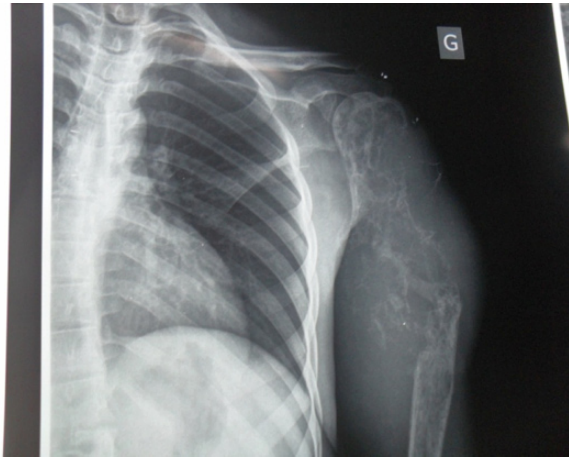
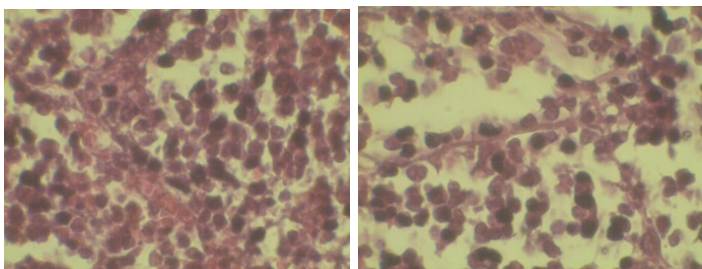


Figure 2: Lytic lesion within the right proximal humeral epiphysis, a periosteal reaction in grass fire with soft tissues invasion.

A bone biopsy was performed. The histological slices showed clusters of small hyperchromatic round cells of lymphocytic appearance oval vesicular nuclei (Figures 3 (A, B)). Immunohistochemical staining is not feasible in Mali.



(A)

(B)

Figures 3 (A-B): Clusters of small hyper chromatic round cells of lymphocytic appearance, oval vesicular nuclei.

The diagnosis of Ewing's sarcoma with vertebral (L1) metastasis is retained. Prior to chemotherapy, oncologists had planned disarticulation. This is rejected by the patient. He receives an infusion of zoledronic acid and he failed to report at the next appointment.

Discussion

We report a case of SE in a 20-year-old boy with no known family history. This is the only case in the service of Rheumatology in 15 years and first case in Mali to our knowledge. It confirms the rarity of Ewing's tumour in black populations [2,4]. Ewing's Sarcoma is the second most common primary bone tumour after osteosarcoma, accounting for 3 % of all childhood malignancies [1]. Ewing's sarcoma has a predilection for the male sex (male/female ratio, 1.3-1.5:1) [4]. It occurs in a wide range of ages from infants to the elderly, although approximately 80% of patients

afflicted are younger than 20 years of age [4]. Peak incidence is during the second decade of life, although 20–30% of cases are diagnosed in the first decade [4]. Ewing's sarcoma is ubiquitous, preferentially affecting flat bones and is most often associated with extensive soft tissue extension: pelvis (26%), thorax (rib, clavicle, scapula, 20%), femur (16%), tibia (9%), spine (8%), humerus (5%) skull (1%) [5,6]. Rarely, 1%–2% of Ewing sarcoma may involve epiphysis [3]. Ewing's Sarcoma has a strong potential to metastasize, most commonly occur in the lungs and bone and more than 10% of patients present with multiple bone metastases at initial diagnosis [4].

The earliest symptom was a painful swelling of the left shoulder, accompanied by fever followed by low back pain and deterioration of the general condition. In the literature, the most common presenting symptoms in a patient with Ewing's sarcoma include pain, swelling, or a mass. Approximately 20% of patients present with a fever which may lead to the mistaken diagnosis of osteomyelitis [7]. Laboratory studies may reveal anaemia, leucocytosis or an increased erythrocyte sedimentation rate [7]. The initial imaging investigation of a suspected bone tumour is a radiograph in two planes. It revealed lytic lesion within the right proximal humeral epiphysis and periosteal reaction, suggesting diagnosis of primary malignant tumour. These lesions are also reported during eosinophilic granuloma, Burkitt lymphoma, fibrous dysplasia, aneurysmal cyst, giant cell repair granuloma [6]. Typically, Ewing's sarcoma appears as an ill-defined, permeative or focally moth-eaten, destructive intramedullary lesion accompanied by a periosteal reaction that affects the diaphysis of long bones [4].

The patient is staged for both local and metastatic disease. A vertebral (L1) metastasis was associated. Diagnostic staging should include a CT scan of the chest to determine pulmonary metastases and a technetium-99 m whole-body radio nucleotide bone scan to identify skeletal metastases [4,6]. This could not be done in patient because of the cost of these exams. In Africa, the endemicity of tuberculosis may lead to the mistaken diagnosis, as was the case with the patient. The definitive diagnostic method is biopsy. Pathological examination in patient described small round cells suggestive of Ewing's Sarcoma [8]. Histological, Ewing's sarcoma is composed of a homogeneous population of small round cells with high nuclear to cytoplasm ratios that are arrayed in sheets [4]. Cytogenetic examination is not feasible on site.

The patient had only received an infusion of zoledronic acid. He had refused surgical amputation of the limb before the chemotherapy. Tremendous strides have been made in the treatment of Ewing's sarcoma [7], as approximately 70% of patients are long-term survivors. A multi-disciplinary team approach is necessary to combine chemotherapy, surgery and/or radiation in the care of the patient. The presence of distant metastasis at diagnosis is the most unfavorable prognostic factor [4] in Ewing's sarcoma, and the patient had. Even with aggressive treatment, patients with metastases have only an approximately 20% chance of long-term survival [4].

Conclusion

Ewing's sarcoma remains a relatively rare disease in Mali. Histo-pathology confirms the diagnosis. Chemotherapy, surgery and/or radiotherapy remain the mainstay of treatment. The prognosis remains unfavorable in Africa, due to the delayed diagnosis and the expensive cost of treatment.

Compliance with Ethical Standards

Conflict of Interest: None

References

1. Galindo CR, Liu T, Krasin MJ, Wu J, Billups CA, et al. (2007) Analysis of prognostic factors in Ewing's sarcoma family of tumours review of St. Jude Children's Research Hospital Studies. *Cancer* 110: 375-384.
2. Mostert S, Njuguna F, Kemps L, Strother M, Aluoch L, et al. (2012) Epidemiology of diagnosed childhood cancer in Western Kenya. *Arch Dis Child* 97: 508-512.
3. Esmaili HA, Niknejad MT, Mohajeri S (2015) Ewing's Sarcoma of Proximal Humeral Epiphysis. *Arch Iran Med* 2015: 133-134.
4. Iwamoto Y (2007) Diagnosis and treatment of Ewing's sarcoma. *Jpn J Clin Oncol* 37: 79-89.
5. Taylor M, Guillon M, Champion V et al. (2005) La tumeur d'Ewing. *Arch Ped* 12: 1383-1391.
6. Bricha M, Jroundi L, Boujida N, El Hassani MR, Chakir N, et al. (2007) Sarcome d'Ewing primitif de la voûte du crâne. *Journal de Radiologie* 88: 1899-1901.
7. Weber KL, Sim FH (2001) Ewing's sarcoma: presentation and management. *J Orthop Sci* 6: 366-371.
8. Wigger HJ, Salazar GH, Blanc WA (1977) Extra skeletal Ewing sarcoma. An ultra-structural study. *Arch Pathol Lab Med* 101: 446-449.