



Case Report

A Rare Presentation of Twins with Situs Inversus Totalis - Case Report

Khalil Salameh*, Rajesh Pattu Valappil, Samer Alhoyed, Anvar Vellamgot, Lina Habboub

Department of Pediatrics, Alwakra Hospital Hamad Medical Corporation, Qatar

*Corresponding author: Khalil Salameh, Department of Pediatrics, Alwakra Hospital Hamad Medical Corporation, Qatar

Citation: Salameh K, Valappil RP, Alhoyed S, Vellamgot A, Habboub L (2020) A Rare Presentation of Twins with Situs Inversus Totalis - Case Report. Ann Case Report 14: 493. DOI: 10.29011/2574-7754.100493

Received Date: 08 October, 2020; **Accepted Date:** 13 October, 2020; **Published Date:** 19 October, 2020

Abstract

Introduction: Situs Inversus Totalis is a rare congenital anomaly that is usually asymptomatic and compatible with everyday life. Incidence is reported to be 1 in 10000 live births. It may be discovered in infancy because of associated anomalies but often remains asymptomatic and is usually discovered incidentally in adult life. But cases of situs inversus with levocardia are often associated with other congenital heart diseases.

Case Presentation: We report a case of newborn twins, born out of consanguineous marriage, from a second gravida mother, with an uneventful antenatal period, at 35 weeks of gestation. Routine examination revealed that both the twins had situs inversus, which was confirmed by imaging modalities such as chest x-ray, echocardiography, and abdominal ultrasound. They were a case of situs inversus totalis (cardiac apex on the right side) without any congenital heart disease.

Conclusions: Newborn babies should have a thorough physical examination after delivery before discharge to enable early diagnosis of congenital anomalies for appropriate referral. Though situs inversus in a single neonate is well described, we have not come across any case report in which both twins have situs inversus with dextrocardia, which makes this case worth reporting.

Keywords: Dextrocardia; Neonate; Situs inversus; Twins

Introduction

Situs, the Latin word for the site, describes the normal position of the cardiac atria and internal organs [1,2]. Situs inversus is a congenital positional anomaly characterized by transposition of abdominal viscera, and when associated with a right-sided heart (Dextrocardia), is termed as situs inversus totalis [3]. The incidence of Situs Inversus Totalis is about 1:10,000 live birth. It is usually asymptomatic and presents a coincidental finding in many people when seeking medical attention for unrelated conditions. Individuals with isolated dextrocardia and situs inversus totalis may have associated congenital heart malformations, primary ciliary dyskinesia, or splenic malformations [4,5]. We present a rare case of newborn twins, both having situs inversus with dextrocardia (situs inversus totalis).

Case Presentation

A second gravida mother delivered a pair of male twins by cesarean section (indication- twin pregnancy with decreased fetal movement) prematurely at 35 weeks of gestation. History showed the presence of third-degree consanguinity between the parents.

Antenatal, natal, and immediate postnatal periods were uneventful. Both the babies did not require active resuscitation; only routine care was given. The first baby was admitted to NICU to manage asymptomatic hypoglycemia requiring treatment with IV dextrose infusions for three days. The examination of the 1st twin revealed normal vital parameters. Upon auscultation, heart sounds were more audible on the right side of the chest, and palpation of the abdomen detected the liver on the left side. The 2nd twin also revealed the same findings.

With these findings' diagnosis of situs inversus was suspected in both the cases and investigations done for confirmation. X-ray of the chest and upper abdomen of both twins (Figures 1 and 2) showed dextrocardia with situs inversus of the abdominal organs (heart in the right hemithorax with the base to apex axis pointing towards the right fundic gas on the right side and liver on the left side of the abdomen). Echocardiography showed dextrocardia with situs inversus totalis in both babies (Figures 3 and 4). No other structural abnormalities were detected. Ultrasonography of the abdomen confirmed the transposition of abdominal viscera (Figure 5 and 6). Chromosomal Microarray for both babies was normal. Babies were breastfed, stable, and discharged with follow-up.

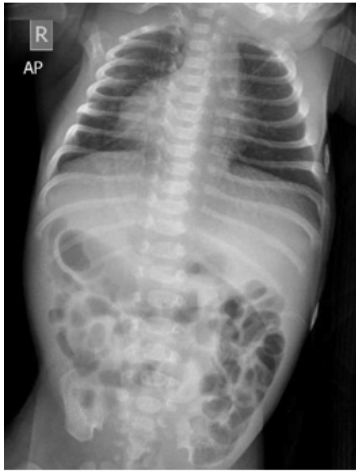

Figure 1: Chest x ray-Twin-A.

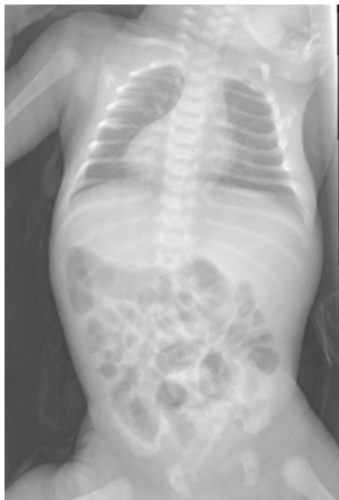


Figure 2: Chest x ray-Twin-B.

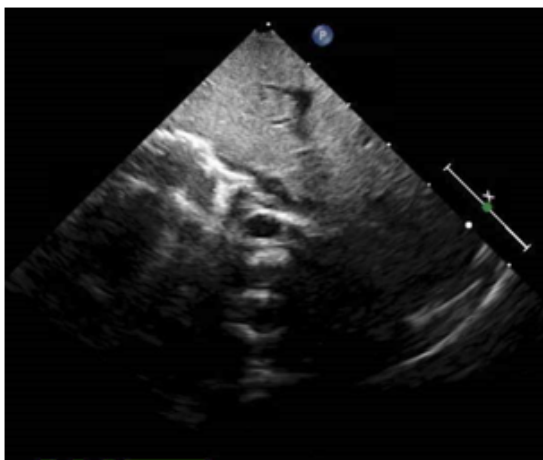


Figure 3: Echo-Twin-A.

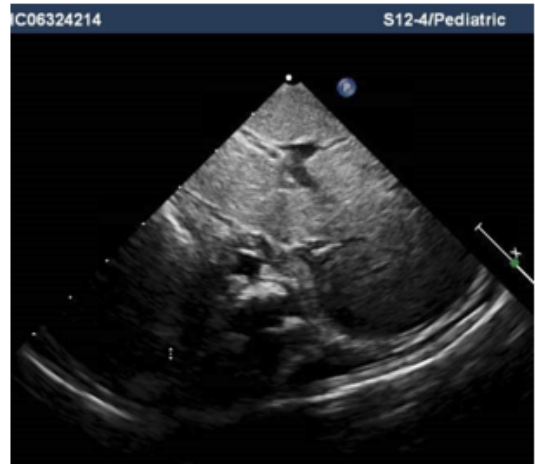


Figure 4: Echo-Twin-B.

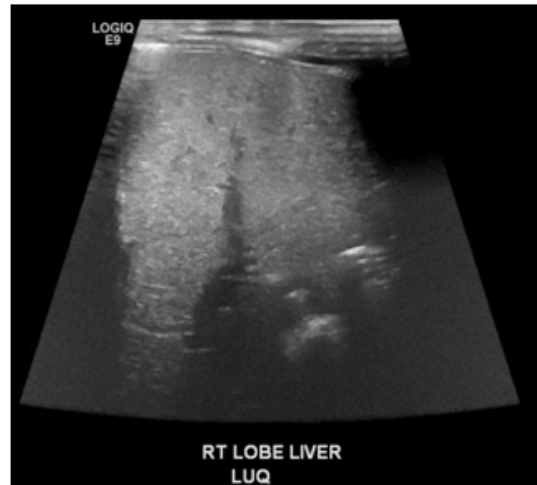

Figure 5: Ultrasound-Twin-A.

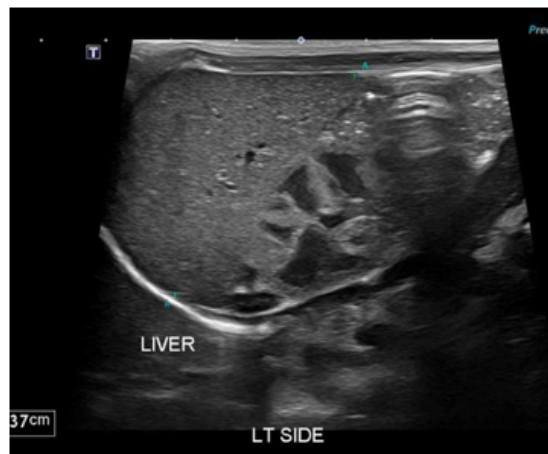

Figure 6: Ultrasound-Twin-B.

Discussion

Situs inversus is a rare congenital anomaly reported in 1 in 8000 to 1 in 25,000 patients with similar incidence in both males and females [6]. No racial predilection exists for situs inversus. The arrangements of the position of the abdominal viscera in dextrocardia may be normal (situs solitus), reversed (situs inversus), and indeterminate (situs ambiguous or isomerism) in 32 to 35%, 35 to 39%, and 26 to 28% of cases respectively [7]. In the intrauterine life, early during embryonic development, the tube-like structure that becomes the heart forms a loop towards the left, identifying the left/right axis along which the other organs should be positioned. Although the mechanism that causes the heart loop to go left is not fully understood, many causative factors may be involved.

Dextrocardia with a normal abdominal situs has a high incidence of associated congenital cardiac anomalies like transposition of the great vessels and ASDs and VSDs in 90 to 95% of cases [8,9]. However, dextrocardia with situs inversus is associated with a lower incidence of congenital heart disease (0 to 10%), as was our case. Clinical presentation varies depending on associated malformation [1,2]. Other associated congenital anomalies reported are duodenal atresia, asplenia, multiple spleens, ectopic kidney, horseshoe kidney, and various pulmonary and vascular abnormalities. Situs inversus totalis associated with primary ciliary dyskinesia is known as Kartagener syndrome (about 25% of people) [10,11]. Patients with primary ciliary dyskinesia have repeated sinus and pulmonary infections [10,12]. Frequent pulmonary infections often result in bronchiectasis, which predominantly affects the lower lungs.

Typically, persons having situs inversus with dextrocardia without other congenital anomaly have a normal life expectancy and have a similar risk of getting acquired disease as that of other persons of the same age and sex group. In the rare instances of cardiac anomalies, life expectancy is reduced, depending on the severity of the defect [13]. The recognition of situs inversus is also essential for preventing surgical mishaps that result from the failure to recognize reversed anatomy or an atypical history. The atrial location determines cardiac situs. In situs inversus, the morphologic right atrium is on the left, and the morphologic left atrium is right. The normal pulmonary anatomy is also reversed so that the left lung has three lobes and the right lung has two lobes. The liver and gallbladder are located on the left, whereas the spleen and stomach are located on the right. The remaining internal structures are also a mirror image of the normal.

In a study of 111 cases, Merklin and Varano classified cases of situs inversus into (a) complete situs inversus, (b) dextrocardia with situs solitus, (c) partial situs inversus; (d) dextroposition of the heart; and (e) levocardia [14]. Most often, situs inversus is an

isolated and accidental event occurring in an individual for the first time in the family, but rarely, it can occur in families. Situs inversus is generally an autosomal recessive genetic condition, although it can be X-linked or found in identical twins, as was found in the above case [14-17]. Diagnosis of dextrocardia is usually confirmed by several modalities: chest radiography, ECG, echocardiography, computed tomography, magnetic resonance imaging, and abdominal ultrasonography. Our twins were a case of situs inversus totalis without any congenital heart disease and normal chromosomal microarray analysis [18].

Conclusions

Dextrocardia with situs inversus is a rare congenital malformation that must be thoroughly evaluated when noticed because it may result in fatal outcomes in rare instances. There is a need for a complete and elaborate diagnostic work up of suspected cases by various imaging modalities to not be missed. Doctors should encourage routine medical examinations for their patients, which could help identify this anomaly, thereby preventing the wrong diagnosis and possibly death due to delay in management. To confirm the suspected cases of situs inversus, imaging studies should be done, such as a chest x-ray or ultrasound, and a referral may be made to a cardiologist. Imaging studies will also rule out the possibility of random arrangement of the organs, or heterotaxy, which has a much higher risk for serious medical complications. Documenting situs inversus in an individual is essential to correctly interpret any future symptoms and avoid any inadvertent clinical or surgical mishap. Our case is one of the rarest reported combinations of situs inversus totalis in identical twins, which we thought is worth reporting.

Consent

We obtained written informed consent from the patient's legal guardian(s) to publish this case report and any accompanying images. A copy of the written consent is available for review by the Editor-in-Chief of this journal.

Disclosure

The authors report no conflicts of interest in this Report.

References

1. Perloff JK (1998) The cardiac malposition. In *The Clinical Recognition of Congenital Heart Disease*. Fourth edition, India edition. Edited by Perloff JK. Philadelphia: Harcourt Brace & Company Asia PTE Ltd, W B Saunders Co 21-52. Chapter 3.
2. Kulkarni PR and Inamdar VV (2005) Situs inversus with dextrocardia associated with ventricular septal defect - a case report, *Abstract. J Anat Soc India* 54.
3. Applegate KE, Goske MJ, Pierce G, Murphy D (1999) Situs revisited: Imaging of heterotaxy Syndrome. *Radiographics* 19: 837-852.

4. Chib P, Grover DN, Shahi BN (1977) Unusual occurrence of dextrocardia with situs inversus in succeeding generations of a family. *J Med Genetics* 14: 30-32.
5. Nawaz A, Matta H, Hamchou M, Jacobez A, Trad O, et al. (2005) Situs inversus abdominus in association with congenital duodenal obstruction: a report of two cases and review of literature. *Pediatr Surg Int* 21: 589-592.
6. Madan Kumar K, Irineu, Babu C, Chander S, Kumar A, Balchander J, et al. (2003) Complete A-V canal defect with dextrocardia with CCTGA - A case Report. *IJT CVS* 19: 55.
7. Isezuo SA, Ma'aji SM, Isah U, Makusidi A (2010) Dextrocardia with situs viscerum inversus totalis in a 65 year old man: a case report. *Niger J Clin Pract* 13: 98-100.
8. Iino K, Watanabe G, Ishikawa N, Tomita S (2012) Total endoscopic robotic atrial septal defect repair in a patient with dextrocardia and situs inversus totalis. *Interact CardioVasc Thorac Surg* 14: 476-478.
9. Piryani RM, Shukla A, Prasad DN, Kohli SC, Shrestha G, et al. (2007) Situs inversus with dextrocardia with multiple cardiac lesions in adult. *Kathmandu Univ Med J* 5: 247-249.
10. Ortega HA, Vega Nde A, Santos BQ, Maia GT (2007) Primary ciliary dyskinesia: considerations regarding six cases of Kartagener syndrome. *J Bras Pneumol* 33: 602-608.
11. Holzmann D, Ott PM, Felix H (2000) Diagnostic approach to primary ciliary dyskinesia: a review. *Eur J Pediatr* 159: 95-98.
12. Kennedy MP, Omran H, Leigh MW, Dell S, Morgan L, et al. (2007) Congenital heart disease and other heterotaxic defects in a large cohort of patients with primary ciliary dyskinesia. *Circulation* 115: 2814-2821.
13. Bohun CM, Potts JE, Casey BM, Sandor GG (2007) A population-based study of cardiac malformations and outcomes associated with dextrocardia. *Am J Cardiol* 100: 305-309.
14. Distefano G, Romeo MG, Grasso S, Mazonne D, Sciacca P, et al. (1987) Dextrocardia with and without situs viscerum in two siblings. *Am J Med* 27: 929-934.
15. Radhika D, Rekha NS, Mohan KVM (2011) Dextrocardia with Situs inversus - a case report. *Int Jour Anat Variat* 4: 88-89.
16. Olbrich H, Haffner K, Kispert A, Volkel A, Volz A, et al. (2002) Mutation in DNAH5 causes primary dyskinesia and randomisation of left-right asymmetry. *Nat Genet* 30: 143-144.
17. Agirbashi M, Hamid R, Jennings HS, Tiller GE (2000) Situs inversus and hypertrophic cardiomyopathy in identical twins. *Am J Genetics* 91: 327-330.
18. Merklin RJ and Varano NR (1963) Situs inversus and cardiac defects. A study of 111 cases of reversed asymmetry. *J Thoracic Cardiovasc Surg* 45: 334-342.