

A Giant Pilomatricoma in the Left Shoulder of a 14-Year-Old Girl

D. Hanine*, A. Skiredj, Z.F. El Alami, T. Elmadhi

Orthopedic Pediatric Surgery Department, Children's Hospital of Rabat, Mohammed V University of Rabat. Morocco

***Corresponding author:** Driss Hanine, Orthopedic Pediatric Surgery Department, Children's Hospital of Rabat, Mohammed V University of Rabat, Morocco

Citation: Hanine D, Skiredj A, El Alami ZF, Elmadhi T (2020) A Giant Pilomatricoma in the Left Shoulder of a 14-Year-Old Girl. Arch Pediatr 5: 185. DOI: 10.29011/2575-825X.100185

Received Date: October 12, 2020; **Accepted Date:** October 23, 2020; **Published Date:** October 30, 2020

Abstract

Pilomatricoma, also known as pilomatrixoma, is a benign skin tumor arising from the cortex of a hair follicle. They are usually asymptomatic, solitary, firm or hard, freely mobile, dermal or subcutaneous nodules. The most common sites of involvement are the face and neck, followed by the upper extremities, the trunk, and the lower extremities. Pilomatrixoma are more common in children and are seen more frequently in girls. The average size is 1cm, and it very rarely exceeds 3cm in diameter. We present a case of left shoulder giant ulcerated pilomatrixoma in a 14-year-old girl with special emphasis on histopathology of pilomatricoma and the relevant differential diagnoses.

Keywords: Calcifying epithelioma of malherbe; Children; Female; Pilomatricoma; Pilomatrixoma; Shoulder

Introduction

A pilomatrixoma (also called Malherbe's calcifying epithelioma) is a benign tumor originating from hair follicle matrix cells [1]. That may occur at any age, although it is most common in childhood and adolescence and in adults over 60 years of age [2]. The tumor most commonly occurs in the head and neck region [3]. Pilomatricoma usually presents as a solitary, asymptomatic, firm, skin-colored to faint blue/red nodule and the average size is 1cm, and it very rarely exceeds 3cm in diameter [4]. The prognosis is typically good, and the treatment of choice is surgical removal. We report a huge pilomatricoma in the left shoulder of a 14-year-old girl.

Case Report

A 14-year-old girl presented with an ulcerated nodule. It was measured 9.5x6x5 cm and was located on the left deltoid region. The lesion had been present for many years; it had rapidly increased in size and ulcerated during the last 8 months. The patient complained of occasional burning and pain. Physical examination revealed a firm but movable tumor overlying the left clavicle (Figure 1).

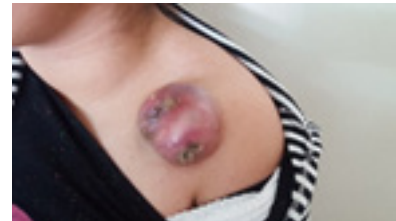

Figure 1: Physical examination showing the tumor in the left shoulder.

A standard Radiography figure doesn't show lesions in the clavicle or in any other bone (Figure 2).

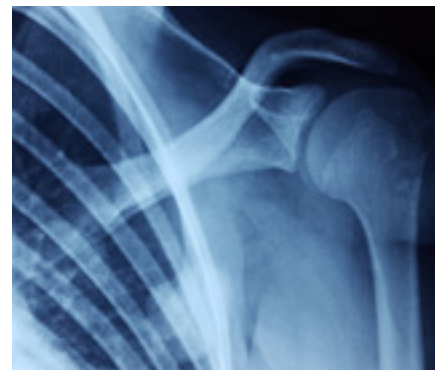


Figure 2: Standard Radiography.

Ultrasound examination of the lesion revealed an exulcerated mass with abundant calcification and hypervascularity at the periphery of the tumor. Magnetic Resonance Imaging showed a well-defined soft tissue mass involving the cutaneous and subcutaneous layers. It displayed iso/hypointense T1 signal to muscles, heterogeneous T2 signal (Figure 3) and heterogeneous enhancement in post intravenous gadolinium study (Figure 4).

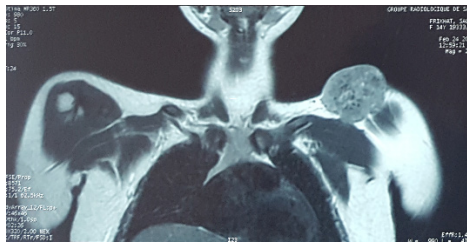


Figure 3: MRI showing a well-defined soft tissue mass involving the cutaneous and subcutaneous layers. It displayed iso/hypointense T1 signal to muscles, heterogeneous T2 signal.

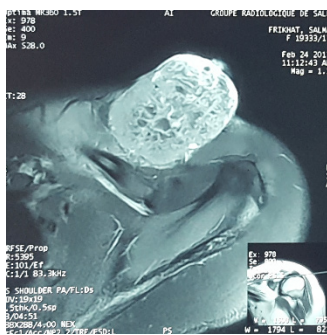


Figure 4: MRI showing heterogeneous enhancement in post intravenous gadolinium study.

The child benefited from a complete resection of the mass (Figure 5).

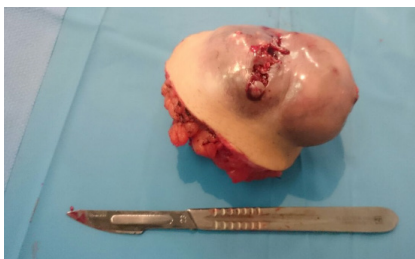

Figure 5: Macroscopic examination of the tumor all resected.

Histopathologic examination of an incisional biopsy specimen revealed the hair matrix origin of the neoplasm, with shadow cells, calcification, and metaplastic ossification. Subsequently, complete surgical excision of the skin nodule was performed.

Macroscopic examination revealed a firm exophytic swelling with central ulceration. Histopathologic examination revealed a well-circumscribed neoplasm involving the whole dermis and the subcutis composed of partially confluent aggregates of matrical cells admixed with eosinophilic cornified material containing shadow cells (Figure 6 A & B).

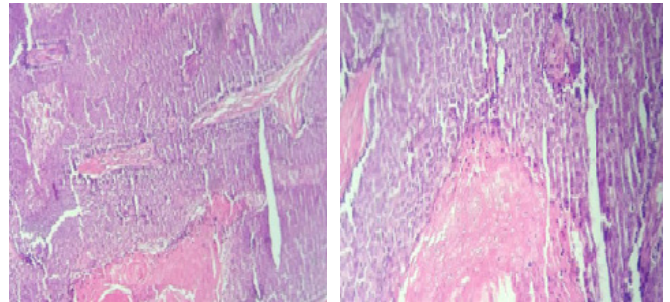


Figure 6: Histopathologic examination revealing a well-circumscribed neoplasm involving the whole dermis and the subcutis composed of partially confluent aggregates of matrical cells admixed with eosinophilic cornified material containing shadow cells (A: HE X40 / B: HE X100).

The child was operated with a total resection of the mass. With a two-year follow-up, the child didn't present any complications or recurrence.

Discussion

Pilomatixoma, a benign neoplasm of the hair follicle, was initially thought to arise from sebaceous glands and was called calcifying epithelioma of Malherbe by Malherbe and Chenantais [5]. It typically presents as a solitary, slow growing, firm, dermal or subcutaneous nodule, frequently occurring in the head, neck, and upper extremities [6].

Pilomatixomas are usually solitary, but multiple foci have been reported in 3.5% of all cases. Familial pilomatixomas and multiple familial pilomatixomas are much rarer. Multiple pilomatixomas and multiple familial pilomatixomas have been associated with myotonic dystrophy [7], Gardner syndrome [8], and Rubinstein-Taybi syndrome [9].

The size of the tumor is usually <3cm, and the term giant pilomatixoma has been used for lesions >5 cm in diameter. There have been very few reported cases of giant pilomatixoma >10cm [10]. Radiologically, Plain X-ray films have limited utility, but may detect calcific foci. The characteristic sonographic picture of pilomatixoma is an ovoid mass with echogenic center surrounded by a hypoechoic rim with acoustic shadows at the junction of dermis and subcutaneous fat with focal thinning of overlying dermis. It also shows calcification [11,12].

Computed tomography demonstrates a sharply demarcated, subcutaneous lesion of soft tissue density, with or without calcification. MRI may show a rim-enhancing lesion with small areas of signal dropout which may be consistent with calcifications [13].

The microscopic appearance of pilomatricoma is characterized by irregularly shaped well-circumscribed masses of epithelial cells. Basophilic cells and shadow cells may be observed in the cellular stroma. Areas of keratinization, calcification and ossification may be seen in the stroma. The stroma often contains a chronic inflammatory cell infiltrate with foreign body giant cells. Mitotic figures may be numerous. Active proliferating hyperchromatic cells with numerous mitoses and infiltration of surrounding structures are microscopic features suggestive of malignant pilomatricoma [14,15].

Spontaneous regression of pilomatricoma has not been reported. Surgical excision is the primary treatment for pilomatricoma. However, there is no standard surgical margin for excision. A narrow excisional margin is generally necessary for complete removal of typical lesions, whereas a wide excision margin of 1–2 cm with preoperative diagnostic imaging has been recommended for giant Pilomatricoma [16,17].

Conclusion

Pilomatricoma, also known as pilomatricoma, is a benign, usually single, small skin tumor. The cervico-facial seat and the female sex are the usual features. The involvement of the members is exceptional.

References

1. Lan MY, Lan MC, Ho CY, Li WY, Lin CZ (2003) Pilomatricoma of the head and neck: a retrospective review of 179 cases. Arch Otolaryngol Head Neck Surg 129: 1327-1330.
2. Julian CG, Bowers PW (1998) A clinical review of 209 pilomatricomas. J Am Acad Dermatol 39: 191-195.
3. Yencha MW (2001) Head and neck pilomatricoma in the pediatric age group: a retrospective study and literature review. Int J Pediatr Otorhinolaryngol 57: 123-128.
4. Ismail W, Pain S, al-Okati D (2000) Giant pilomatricoma simulating carcinoma of the male breast. Int J Clin Pract 54: 55-56.
5. Kawamura N, Tamura H, Obana S, Wenner M, Ishikawa T, et al. (1998) Differential effects of neuropeptides on cytokine production by mouse helper T cell subsets. Neuroimmunomodulation 5: 9-15.
6. Danielson-Cohen A, Lin SJ, Hughes CA (2001) Head and neck pilomatricoma in children. Arch Otolaryngol Head Neck Surg 127 : 1481-1483.
7. Cantwell AR, Reed WB (1965) Myotonia atrophica and multiple calcifying epithelioma of Malherbe. Acta Derm Venereol 45: 387-390.
8. Pujol RM, Casanora JM, Egido R, Pujol I (1994) Multiple familial pilomatricoma: a cutaneous marker for Gardner syndrome? Pediatr Dermatol 12: 331-335.
9. Cambiaghi S, Ermacora L, Brusasco A, Canzi L, Caputo R (1994) Multiple pilomatricomas in Rubinstein-Taybi syndrome: a case report. Pediatr Dermatol 11: 21-25.
10. Yamauchi M, Yotsuyanagi T, Saito T (2010) Three cases of giant pilomatricoma – considerations for diagnosis and treatment of giant skin tumours with abundant inner calcification present on the upper body. J Plast Reconstr Aesthet Surg 63: 519-524.
11. Hughes J, Lam A, Rogers M (1999) Use of ultrasonography in the diagnosis of childhood pilomatricoma. Pediatr Dermatol 16: 341-344 .
12. Hwang JY, Lee SW, Lee SM (2005) The common ultrasonographic features of pilomatricoma. J Ultrasound Med 24: 1397-1402.
13. Agarwal RP, Handler SD, Matthews MR, Carpentieri D (2001) Pilomatricoma of the head and neck in children. Otolaryngol Head Neck Surg 125: 510-515.
14. Fayyazi A, Soruri A, Radzun HJ, Peters JH, Berger H (1997) Cell renewal, cell differentiation and programmed cell death (apoptosis) in pilomatricoma. Brit J Dermatol 137: 714-720.
15. Kaddu S, Soyer HP, Hödl S, Kerl H (1996) Morphological stages of pilomatricoma. Am J Dermatopathol 18: 333-338.
16. Duflo S, Nicollas R, Roman S (1998) Pilomatricoma of the head and neck in children: a study of 38 cases and a review of the literature. Arch Otolaryngol Head Neck Surg 124: 1239-1242.
17. Kovacic M, Rudic M, Nekić I (2007) Giant pilomatricoma (benign calcifying epithelioma of Malherbe) of the neck and face. Dermatol Surg 33: 340-343.