



Case Report

Efficacy of Direct Acting Antivirals and the Role of Corticosteroids in Rapidly Progressive Cryoglobulinemic Glomerulonephritis Associated to Hepatitis C Related Liver Cirrhosis

Ioana Adela Ratiu¹, Ileana Peride^{2*}, Ovidiu Fratila^{1*}, Baidog Adriana^{3*}, Gabriel Cristian Bako¹, Cristian Ratiu¹, Alina Tantau⁴, Tiberia Ilias¹

¹Faculty of Medicine and Pharmacy, University of Oradea, Romania

²Department of Nephrology and Dialysis, “Carol Davila” University of Medicine and Pharmacy Bucharest, Romania

³Department of Nephrology, “Gavril Curteanu” Municipal Clinical Hospital, Romania

⁴Associate Professor, University of Medicine and Pharmacy “Iuliu Hațieganu” Cluj-Napoca, Romania

***Corresponding authors:** Ovidiu Fratila, Associate Professor, Department of Internal Medicine, University of Oradea, Gheorghe Doja Street, no 65, 410169, Oradea, Bihor County, Romania

Ileana Peride, Assistant Professor, Department of Nephrology and Dialysis, “Carol Davila” University of Medicine and Pharmacy Bucharest, Romania

Baidog Adriana, Department of Nephrology, “Gavril Curteanu” Municipal Clinical Hospital, Oradea, Romania

Citation: Ratiu IA, Peride I, Fratila O, Adriana B, Bako GC, et al. (2020) Efficacy of Direct Acting Antivirals and the Role of Corticosteroids in Rapidly Progressive Cryoglobulinemic Glomerulonephritis Associated to Hepatitis C Related Liver Cirrhosis. Ann Case Report 14: 510. DOI: 10.29011/2574-7754.100510

Received Date: 19 October, 2020; **Accepted Date:** 24 October, 2020; **Published Date:** 30 October, 2020

Abstract

Background/Aims: The incidence of Hepatitis C Viral (HCV) infection is relatively high, but the percentage of cryoglobulinemic glomerulonephritis as an extrahepatic manifestation, remains low. When it occurs, this kind of vasculitis correlates with a bad outcome in lack of proper treatment. Until recently, the therapy for this disease was interferon-based, but the corticosteroids or/and cyclophosphamide were also added, in order to decrease the cryoglobulin synthesis. All the studies showed the lack of efficiency of interferon regimens administrated in renal disease. Direct Acting Antiviral Agents (DAA) demonstrated a high efficiency for viral clearance, as well as a good effect on the kidney when cryoglobulinemic glomerulonephritis developed.

Case Presentation: We present a special case of a female patient with hepatitis C viral infection, treated with peginterferon and ribavirin five years ago, non-responder, who developed a rapidly progressive cryoglobulinemic glomerulonephritis, with life-threatening complications. This critical situation imposed critical measures, with the initiation of the corticosteroids prior to the antiviral treatment. When the combination: ombitasvir/paritaprevir/ritonavir and dasabuvir was introduced, all the clinical and laboratory findings improved, liver and renal functions stabilized, proteinuria decreased, except for the immunological markers that remained positive (in low titer). Our data indicates the efficacy and safety of using the combination of direct-acting antiviral agents along with corticosteroids in rapidly progressive cryoglobulinemic glomerulonephritis.

Conclusions: In patients diagnosed with HCV related cryoglobulinemic glomerulonephritis, we strongly recommend including DAA drugs into the treatment regimens, regardless of the liver fibrosis level.

Keywords: HCV infection; Cryoglobulinemic glomerulonephritis; Direct-acting antivirals; Outcome

Abbreviations: HCV: Hepatitis C Virus; DAA: Direct-Acting Antivirals; MPGN: Membranoproliferative Glomerulonephritis;

RTX: Rituximab; SVR: Sustained Virologic Response; eGFR: Estimated Glomerular Filtration Rate; OBV+RITV+PTV+DSV: Ombitasvir-Ritonavir-Paritaprevir-Dasabuvir; PEG-INF: Pegylated Interferon

Introduction

The incidence of hepatitis C viral infection is 3.5% in our country, while the worldwide prevalence runs around 170 million people [1,2]. The association with type II mixed cryoglobulinemia is estimated at a quarter of all the HCV infections, and of these, only 10-15% develop symptomatic vasculitis [2]. The incidence of membranoproliferative glomerulonephritis, as a result of renal vasculitis, was estimated at around 80% of the patients with HCV cryoglobulinemia [1]. Therefore, prevention of MPGN should represent an important part of the management of these patients, and recently there are a few studies focused on the evaluation of renal impairment using non-invasive methods, such as shear wave elastography of the kidneys [3,4]. In HCV infection, cryoglobulinemia is viral induced by B cells proliferation. The B cell clones produce monoclonal IgM with rheumatoid factor activity against polyclonal IgG which recognize HCV antigens and form circulating immune complexes.

When these immune complexes bind to the small vessels wall, the complement will be activated through the classic pathway, the leukocytes will be recruited and the vasculitis occurs [5]. Once the pathogenesis is understood, it becomes clear that the viral eradication has to be the mainstay of the cryoglobulinemic glomerulonephritis therapy. As a general approach, there are three steps in the treatment of mixed cryoglobulinemic vasculitis secondary to HCV infection: 1) antiviral treatment, 2) decrease of B cell proliferation and 3) remove/decrease production of circulating immune complexes in life-threatening conditions [6]. Rituximab, a monoclonal antibody anti-CD20, is used in cases of severe disease or if the antiviral therapy failed. Plasmapheresis can be used alone or in conjunction with rituximab and immunosuppression therapy in critical cases. Cyclophosphamide is indicated when RTX/plasmapheresis and antiviral therapy cannot be used. The use of high-dose prednisone is still uncertain, even if there are some studies that recommend it in the treatment of active disease [5,7].

The use of direct-acting antivirals has changed the treatment of the HCV infection: the side effects are insignificant, the compliance to treatment is very good and the capacity to induce sustained virologic response overcomes 90% [8]. RUBY-1 study demonstrated the safety and efficacy of ombitasvir-ritonavir-paritaprevir-dasabuvir ± ribavirin in patients with Chronic Kidney Disease (CKD) stage 4 and 5 infected with genotype 1 virus [8]. There are only few data regarding the efficacy of DAA against the extra-hepatic disorders associated to HCV infection [9,10]. When Estimated Glomerular Filtration Rate (eGFR) is higher than 30 mL/min, some studies showed that the use of sofosbuvir based regimens decreased proteinuria and improved eGFR [11]. The combination OBV+PTV+RITV+DSV, accepted in our country for the treatment of HCV infection, has the great advantage to be used regardless of the eGFR value. We report one case of cryoglobulinemic MPGN secondary to HCV infection in a patient

with liver cirrhosis in which the use of DAA regimens, ombitasvir/paritaprevir/ritonavir and dasabuvir, induced SVR, improved the renal function, decreased the proteinuria and hematuria and finally saved the patient's life.

Case Presentation

A 57 years old female patient with known HCV infection - diagnosed 5 years ago and non-responder at that time to pegylated interferon and ribavirin regimen - was admitted through the emergency unit into our Department of Nephrology. She presented with the following clinical features: peripheral oedema, purpuric lesions located merely on the lower limbs, shortness of breath, severe arterial hypertension (Figure 1). The laboratory examinations showed: hematuria and proteinuria associated with a progressive decrease of eGFR, cholestasis and hypoproteinemia; eGFR was calculated using Chronic Kidney Disease- Epidemiology Collaboration (CKD-EPI) 2009 equation (Table 1). The immunological tests revealed: C4 component of the complement severely decreased (suggestive for cryoglobulinemia), rheumatoid factor highly increased and positive cryoglobulins. We established the diagnosis of rapidly progressive glomerulonephritis and severe secondary arterial hypertension, in a patient with known history of HCV infection.

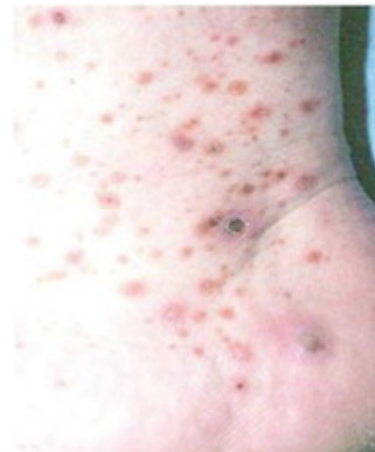

Figure 1: Skin lesions of the lower limb.

Although the renal biopsy was not necessary due to the obvious context, the uncontrolled elevated blood pressure and significant thrombocytopenia were other two aspects that contraindicated renal biopsy. The great challenge was the clinical evolution, marked by the severe hypertension, only partly controlled with five classes of antihypertensive drugs: angiotensin-II-receptor antagonists, beta-blockers, calcium channel blockers, diuretics, selective agonists at the Imidazoline Receptor Subtype 1 (I1) - moxonidine. In this context an episode of stroke was diagnosed, with right bulbar infarction and Wallenberg syndrome. The skin vasculitis was pronounced, with area of cutaneous

necrosis. Proteinuria increased in time and a rapidly progressive renal failure developed. Because of the lack of antiviral therapy in emergency situation, and of rituximab and cyclophosphamide as well, we decided to initiate corticosteroids: methyl-prednisolone 1 g/day 3 consecutive days, followed by prednisone, 1 mg/kg body/day.

After 2 weeks the proteinuria and hematuria decreased, the renal function improved, but diabetes mellitus insulin-dependent and decompensation of the liver functions developed: increased oedema and ascites, depreciation of the synthesis function of the liver, inflammatory and cholestasis syndrome, signs of overacting spleen function (anemia, leucopenia, thrombocytopenia). The viral load (HCV RNA) markedly increased: 10 mil UI/mL, and the FIBROMAX score revealed F4 fibrosis level. After another 3 weeks, the antiviral therapy was finally available: dasabuvir 250 mg twice a day and ombitasvir 12.5 mg/paritaprevir 75 mg/ritonavir 50 mg, 2 tablets once daily, with the maintenance of the corticosteroids. In 2 weeks, the renal function became normal,

proteinuria decreased (1.2 g/day), the liver function improved, the serum cholinesterase remained low. The complete blood count became normal and the viral load was undetectable.

The glycemic values maintained high, so the patient remained insulin-dependent (low dose, basal insulin). Immunologically, the level of C4 complement and the cryoglobulins as well continued to decrease. Six weeks after the initiation of combined treatment, with prednisone progressively reduced (40 mg per day), the renal function remained normal, the liver panel became normal with the persistence of the low level for serum cholinesterase, hematuria disappeared and the proteinuria was significantly low (Table 1). After completing the antiviral treatment, without corticosteroids, the clinical status of the patient was satisfactory with a convenient blood pressure and normal glycemic values, with normal liver functions, eGFR 60 mL/min, low proteinuria, absent hematuria, low level of cryoglobulins and undetectable viral load. During the last medical visit, after 3 months since completion of the therapy, we noticed a sustained virological response (Figure 2).

Parameter / Clinical feature	Pre-therapy	During prednisone therapy	DAA THERAPY (WEEKS)			3 months after the DAA therapy
			4	6	12	
Serum urea (mg/dL)	67/104/91	72	37	42	36	30
Serum creatinine (mg/dL)	1.38/2.13/1.74	1.05	0.9	0.9	0.92	0.9
eGFR (mL/min)	40	70	80	80	79	80
Proteinuria (g/day)	0.9-5.4	1.9	0.7	0.45	0.3	0.3
Hematuria	+++ (50/field)	+/-	+ 10-15/field	+/- 0-1/field	+/- 0-1/field	+/- 0-1/field
C4 (mg/dL)	0.2	6	7	7	10	12
Cryoglobulin	+	+	+	+/-	-	-
Rheumatoid factor	1/64	1/8	+	+	+	+
Serum total proteins (g/dL)	4.7	5.25	5.49	6.66	6.8	6.7
AST/ALT (U/L)	34/32	38/82	19/9	27/16	24/18	25/18
GGT U/L	212	302	33	35	30	33
Serum total bilirubin (mg/dL)	0.48	0.64	0.59	0.4	0.6	0.5
Serum cholinesterase (U/L)	4500	3015	3500	3900	3900	3800
Glycemia (mg/dL)	119	104	100	112	110	107
Viral load (ARN VHC) (UI/mL)	10 mil	16 mil	6 mil	-	-	UN DETECTABLE

Table 1: Parameters evolution before, during and after treatment.

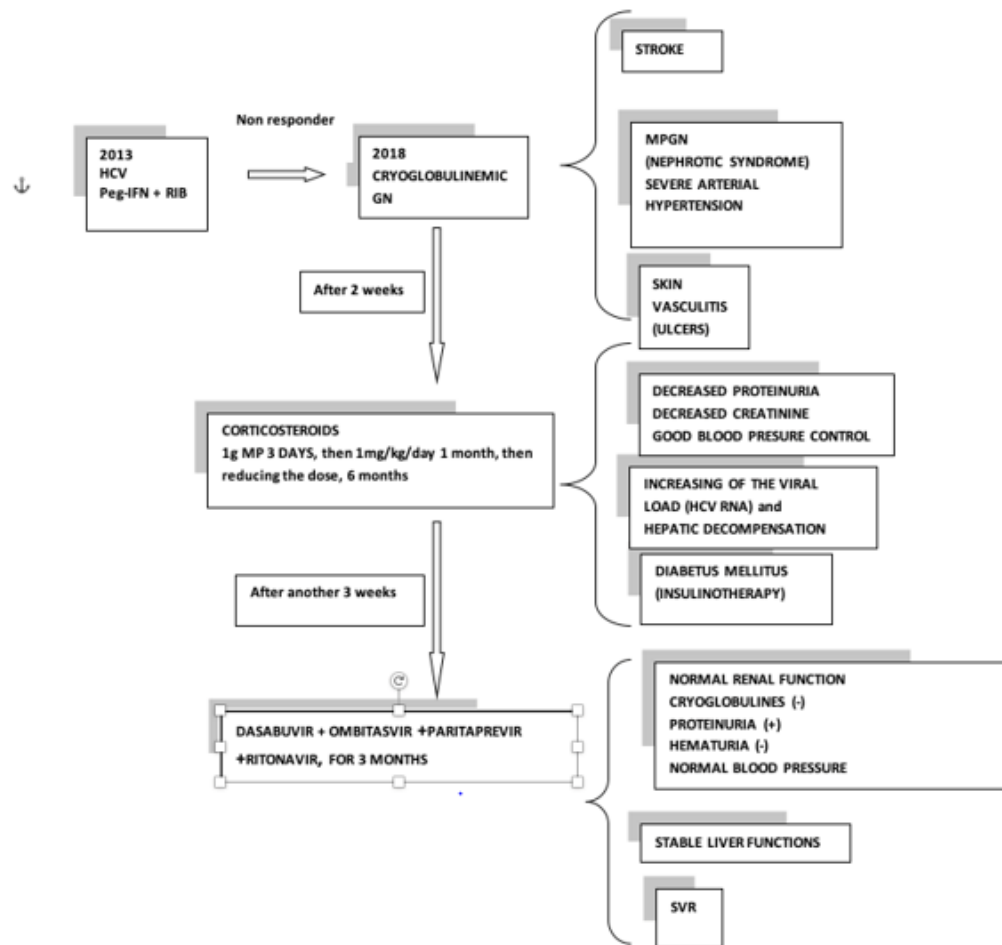


Figure 2: Comprehensive algorithm of the treatment and evolution.

Discussions

From our knowledge, this is the first case reported in our country of cryoglobulinemic glomerulonephritis treated with corticosteroids in association with direct-acting antivirals (OBV+RITV+PTV+DSV) that were initiated pluckily for a patient with decompensated cirrhosis and a recent stroke; this drug combination demonstrated the benefits for the renal pathology, and for the liver function as well. According to the published data, the “classical” treatment with peginterferon and ribavirin failed to show an efficient effect on proteinuria and renal function even when the virological response was sustained [12]. RTX in association with IFN+RBV was used in refractory or severe mixed cryoglobulinemia [13-15]. The violent and aggressive onset of this vasculitis at 5 years after the IFN + RBV therapy, which was at that time poorly tolerated and without SVR, imposed an emergency decision. The difficulty to maintain a normal blood pressure value despite the use of five different classes of antihypertensive drugs in maximal dose, with a consecutive stroke and all the clinical and

biological context (sufficient for the diagnosis), led to the decision of not to perform renal biopsy.

Furthermore, the bureaucratic difficulties to acquire the antiviral treatment imposed the initiation of corticosteroids alone in order to control the nephrotic syndrome, despite the fact that there are insufficient evidence to confirm their harm or benefit [16]. This was a healing measure, reflected by the decrease of the proteinuria and hematuria, the improvement of the renal function, and the control of the blood pressure. Unfortunately, due to the use of prednisone, we later detected an increase of the viral load, a worsening of the hepatic function, development of ascites and also the appearance of thrombocytopenia and anemia. Rituximab, with all the bureaucratic difficulties, it could have improved the renal prognosis, but with a transient effect, and therefore we would have had to continue the corticosteroids at that time. The use of the cyclophosphamide was contraindicated because of the thrombocytopenia and plasmapheresis was not available at that moment.

In this context, the dasabuvir + ombitasvir + paritaprevir + ritonavir combination completed the therapeutic regimen and we succeeded in 4 weeks to reduce the viral load despite the use of corticosteroids; additionally, we were able to compensate the liver and kidney functions, to increase the eGFR with the corticosteroid treatment and then, to control proteinuria and hematuria. The only side effects of the dasabuvir + ombitasvir + paritaprevir + ritonavir use were mild general symptoms like: fatigue (merely in the second month of treatment), insomnia, dizziness, and headache. The RUBY-1 study, but also C-SURFER study showed the effectiveness and the low rate of adverse effects in patients with chronic kidney disease [8,17]. Up to this moment, there are no large studies performed on patients with HCV related cryoglobulinemic glomerulonephritis that were treated with direct-acting antivirals. Consequently, a long-term follow-up will be necessary for a thorough assessment of the liver function, hepatocarcinoma screening and recurrences of glomerulonephritis in this patient.

Conclusions

The treatment with DAA drugs associated with corticosteroids has a favorable effect on the eGFR in patients with membranoproliferative glomerulonephritis secondary to HCV. When the treatment starts early, DAA therapy shows a good effect on proteinuria. In order to better comprehend the magnitude of this problem, a long-term follow-up of these patients and further extended clinical studies should be performed. For the moment, we emphasize the necessity to extent the use of this type of treatment also in all patients diagnosed with HCV-related cryoglobulinemic glomerulonephritis, regardless of the liver fibrosis level.

Acknowledgement

This work did not receive any specific funding or grant in any form.

Conflict of Interest

All authors have no conflict of interest to declare.

References

1. Fabrizi F, Plaisier E, Saadoun D, Martin P, Messa P, et al. (2013) Hepatitis C virus infection, mixed cryoglobulinemia, and kidney disease. *Am Journal Kidney Disease* 62: 623-637.
2. Dammacco F and Sansonno D (2013) Therapy for Hepatitis C virus-related cryoglobulinemic vasculitis. *N Engl J Med* 369: 1013-1045.
3. Radulescu D, Peride I, Petcu LC, Niculae A, Checherita IA (2018) Supersonic Shear Wave Ultrasonography for Assessing Tissue Stiffness in Native Kidney. *Ultrasound Med Biol* 44: 2556-2568.
4. Peride I, Rădulescu D, Niculae A, Ene V, Bratu OG, et al. (2016) Value of ultrasound elastography in the diagnosis of native kidney fibrosis. *Med Ultrason* 18: 362-369.
5. Mughtar E, Magen H, Gertz MA (2017) How I treat cryoglobulinemia. *Blood* 129: 289-298.
6. Palombo SB, Wendel EC, Kidd LR, Yazdi F, Naljayam MV (2017) MPGN and mixed cryoglobulinemia in a patient with hepatitis C - new treatment implications and renal outcomes. *Clin Nephrol Case Stud* 5: 66-69.
7. Goglin S and Chung SA (2016) Current treatment of cryoglobulinemic vasculitis. *Curr Treat Options in Rheum* 2: 213-224.
8. Lawitz E, Gane E, Cohen E, Vierling J, Agarwal K, et al. (2018) Efficacy and Safety of Ombitasvir/Paritaprevir/Ritonavir in Patients With Hepatitis C Virus Genotype 1 or 4 Infection and Advanced Kidney Disease. *Kidney Int Rep* 4: 257-266.
9. Saadoun D, Landau DA, Calabrese LH, Cacoub PP (2007) Hepatitis C-associated mixed cryoglobulinemia: a crossroad between autoimmunity and lymphoproliferation. *Rheumatology (Oxford)* 46: 1234-1242.
10. Polo ML and Laufer N (2017) Extrahepatic manifestations of HCV: the role of direct acting antivirals. *Expert Rev Anti Infect Ther* 15: 737-746.
11. Örmeci N (2018) Treatment of Patients with Hepatitis C Virus and Kidney Diseases. *Int J Gastroenterol Disord Ther* 5: 138.
12. European Association for the Study of the Liver (2018) EASL Recommendations on Treatment of Hepatitis C 2018. *J Hepatol*.
13. Saadoun D, Resche-Rigon M, Sene D, Perard L, Karras A, et al. (2008) Rituximab combined with Peg-interferon-ribavirin in refractory hepatitis C virus-associated cryoglobulinemia vasculitis. *Ann Rheum Dis* 67: 1431-1436.
14. Terrier B, Saadoun D, Sène D, Sellam J, Pérard L, et al. (2009) Efficacy and tolerability of rituximab with or without PEGylated interferon alfa-2b plus ribavirin in severe hepatitis C virus-related vasculitis: a long-term follow-up study of thirty-two patients. *Arthritis Rheum* 60: 2531-2540.
15. Ignatova T, Chernova O, Novikov P, Moiseev S (2014) HCV-associated cryoglobulinemic vasculitis: triple/dual antiviral treatment and/or rituximab? *Ann Rheum Dis* 73: e58.
16. Brok J, Møllerup MT, Krogsgaard K, Gluud C (2004) Glucocorticosteroids for viral C hepatitis C. *Cochrane Database of Systematic Reviews* 2: CD002904.
17. Roth D, Nelson DR, Bruchfeld A, Liapakis A, Silva M, et al. (2015) Grazoprevir plus elbasvir in treatment-naive and treatment-experienced patients with hepatitis C virus genotype 1 infection and stage 4-5 chronic kidney disease (the C-SURFER study): a combination phase 3 study. *Lancet* 386: 1537-1545.