



Review Article

Physical Examination as a Tool for Hemodialysis Vascular Access Surveillance

Khalil Essa SE^{1*}, Sharaf M²

¹Regional Renal Coordinator, Abu Dhabi-Madinat Zayed Hospital, Emirate of Abu Dhabi, United Arab Emirates

²Internal Medicine Specialist-AIDhafra Hospital, Emirate of Abu Dhabi, United Arab Emirates

***Corresponding author:** Khalil Essa SE, Specialist Nephrology, P.O.Box: 58341, Madinat Zayed Hospital, Emirate of Abu Dhabi, United Arab Emirates. Email: issa5463@hotmail.com

Citation: Khalil Essa SE, Sharaf M (2023) Physical Examination as a Tool for Hemodialysis Vascular Access Surveillance. Rep Glob Health Res 6: 162. DOI: 10.29011/2690-9480.100162.

Received Date: 19 June, 2023; **Accepted Date:** 27 June, 2023; **Published Date:** 30 June, 2023

Abstract

Introduction: Physical Examination (PE) of the arteriovenous (AV) access is of established clinical importance.

The National Kidney Foundation Kidney Disease Outcomes Quality Initiative (KDOQI) guidelines recommend that PE of the AV access should be performed by a qualified individual on regular basis (at least monthly) when used for surveillance. The primary purpose of this examination is to detect vascular stenosis or other abnormalities that might lead to access dysfunction. This can be done with levels of accuracy that are quite acceptable. In contrast to other approaches to AV access surveillance, it is simple to perform and does not require additional machines, regular calibrations, additional cost, or additional staff. In addition PE can also detect other problems that can adversely affect the AV access. For these reasons, plus the fact that it is easily learned, PE should be taught to all hemodialysis caregivers and should be performed on a regular basis on all hemodialysis patients.

Purpose of this study:

- The purpose of this study was to evaluate the accuracy of physical examination in the detection and location of AV access stenosis when compared with angiography.
- To reflect the importance of PE in prevention of vascular access dysfunction.

Results:

- There was strong agreement between physical examination and angiography in the diagnosis and localization of outflow and inflow stenosis.
- In addition to the detection of stenosis, pinpointing the location of stenosis on physical examination has important procedural implications.

Keywords: Physical Examination (PE); Vascular Access Surveillance; Vascular Stenosis; Venous Stenosis; Access Dysfunction

Introduction

Physical examination (PE) of the arteriovenous (AV) access is of established clinical importance. The National Kidney Foundation Kidney Disease Outcomes Quality Initiative (KDOQI) guidelines recommend that PE of the AV access should

be performed by a qualified individual on regular basis (at least monthly) when used for surveillance.

NKF-K/DOQI Clinical Practice Guideline

Physical Examination (Monitoring)

Physical examination should be used to detect dysfunction in fistulae and grafts at least monthly by a qualified individual. The primary purpose of this examination is to detect vascular stenosis or other abnormalities that might lead to access dysfunction.

This can be done with levels of accuracy that are quite acceptable. In contrast to other approaches to AV access surveillance, it is simple to perform and does not require additional machines, regular calibrations, additional cost, or additional staff.

In addition PE can also detect other problems that can adversely affect the AV access.

For these reasons, plus the fact that it is easily learned, PE should be taught to all hemodialysis care givers and should be performed on a regular basis on all hemodialysis patients.

Purpose of this Study:

The Main Goal!

1. “Prospective Diagnosis of Venous Stenosis”

It is important that all hemodialysis facilities have in place a system designed to detect venous stenosis so that it can be diagnosed and treated prospectively.

2. The purpose of this study was to evaluate the accuracy of physical examination in the detection and location of AV access stenosis when compared with standard angiography.
3. To reflect the importance of PE in prevention of vascular access dysfunction.

Methods:

A. Thirty six patients with end stage renal disease (ESRD) on regular hemodialysis in Madinat Zayed hospital were included in the study.

Each patient underwent vascular access physical examination.

❖ The elements of the **physical examination** used in this study were based on recent information by Beathard and colleagues.

Inspection (arm, shoulder, breast, neck, and face edema and presence of collaterals), **palpation**, and **auscultation** were performed in a systematic manner.

Pulse (hyper pulsatile, normal, weak) and **thrill/bruit** (continuous, discontinuous) characteristics were ascertained.

• **Pulse augmentation:** to evaluate the inflow segment it was performed by complete occlusion of the access several centimeters beyond the arterial anastomosis and evaluation of the strength of the pulse, the test was considered normal when the portion of fistula upstream from the occluding finger demonstrated augmentation of pulse.

❖ **Arm elevation:** to evaluate the outflow tract test was performed by elevation of the extremity with the fistula and examination of the normal collapse of the access

The test was considered abnormal when the fistula remained plump after arm elevation.

❖ The physical examination findings and the diagnosis were recorded.

B. All patients with abnormal findings in PE underwent both retrograde and ante grade angiography by interventional radiology (IR) and intervention done accordingly.

Physical Examination:

1. Pulse.
2. Thrill and bruit.
3. Augmentation test.
4. Arm elevation test.
5. Clinical features.

1-Pulse

• Pulse. Normally, the AV access is easily compressible with very little pulse.

In general, a pulsatile AV access is an adverse finding, and it is indicative of a downstream lesion.

• The degree of hyperpulsatility that is present is proportional to the severity of the stenosis.

• An unusually weak pulse (hypo pulsatile access) or “flat access” suggests the presence of a stenotic lesion in the inflow side of the access.

The pulse may be best appreciated using the fingertips (Figure 1).

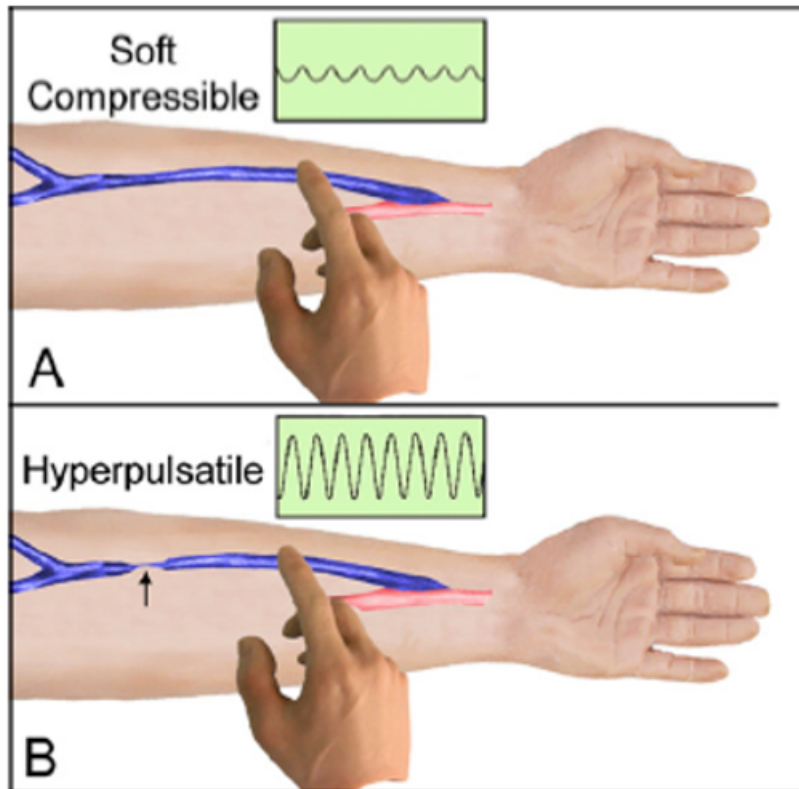


Figure 1: Pulse Examination.

2-Thrill and bruit (Flow):

- **1-Thrill:** - is felt by palpation. Figure 2
- **2-Bruit:** - is heard by auscultation. (Figure 3).

Thrill. A thrill is a **palpable vibration (“buzz”)**.

It is related to flow; when present, it indicates that there is flow within the access. The examination of an access can reveal two different types of thrill—a diffuse background thrill and a localized accentuated thrill.

The presence of a soft, **continuous (systolic and diastolic)**, diffuse background thrill palpable over the course of the access, either an AVF or an AVG, **is normal.** (Figure 2-A).

A stenotic lesion creates a localized area of turbulent flow within the vessel.

As the lesion develops with progressively increasing resistance to flow, the thrill becomes shortened and **eventually loses its diastolic component.** (Figure 2-B).

The absence of a thrill indicates a lack of flow. This finding, along with the absence of any pulse, is characteristic of a thrombosed or “clotted” access.

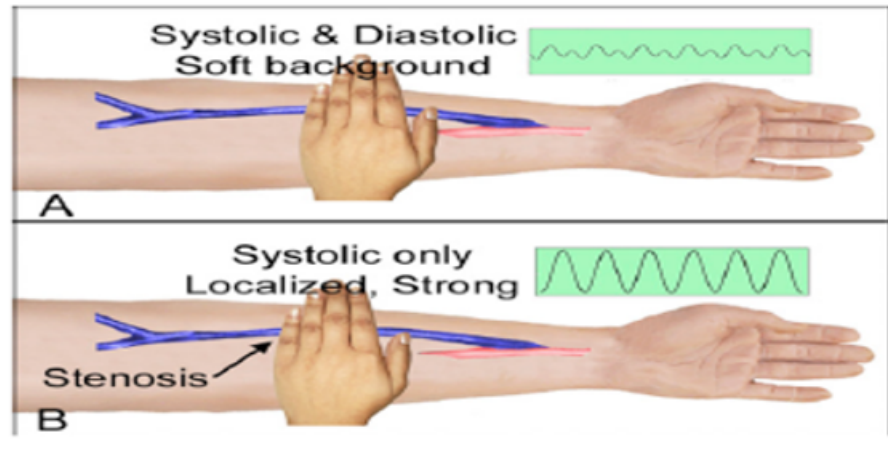


Figure 2: Thrill

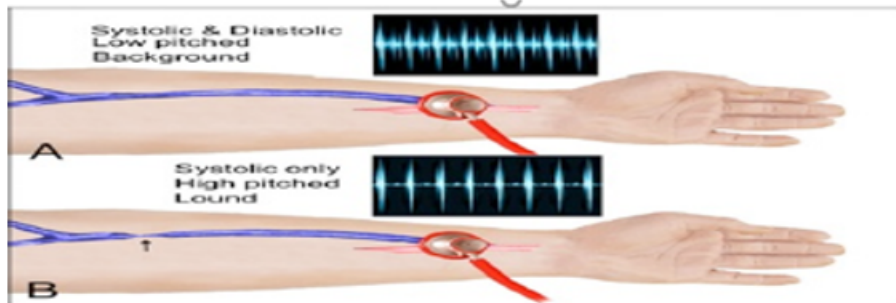


Figure 3: Bruit

3-Testing for pulse augmentation (evaluates the inflow portion of the AV access). (Figure 4)

- This test is performed by occluding the access several centimeters above the arterial anastomosis with one hand while evaluating the intensity of the pulse with the other.
 - This test is based upon the fact that if the access is completely occluded some distance from the arterial anastomosis, the **normally soft pulse will become augmented**.
 - The degree of this increase in pulse intensity is directly proportional to the quality of the access inflow.
 - If there are problems anywhere within the arterial system from the anastomosis upward, it will affect the degree to which the pulse is augmented.
 - An unusually **weak pulse (hypo pulsatile access) or “flat access”** suggests the presence of a **stenotic lesion in the inflow side of the access**
 - Strength of pulse without occlusion – outflow
 - Strength of pulse with occlusion - inflow
 - If pulse is normal Augmentation is indicative of inflow
 - If pulse is hypo-pulsatile (indicative of stenosis) Degree of augmentation can be used to gauge degree of stenosis
- No augmentation - indicates very severe stenosis
- Moderate augmentation - moderate stenosis

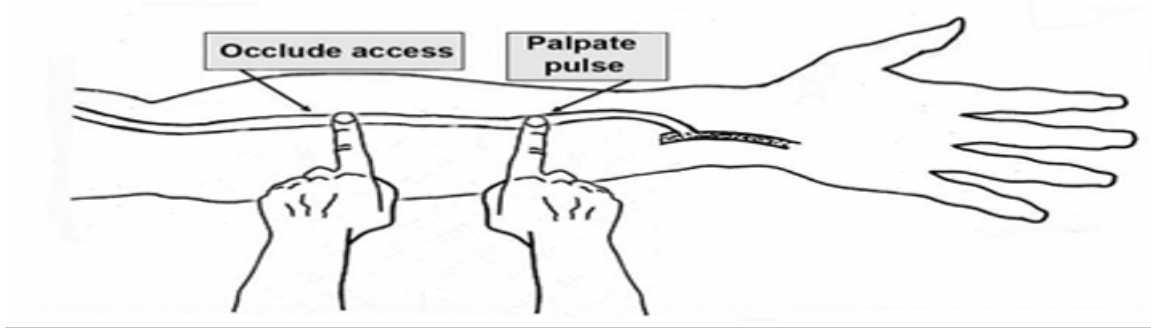


Figure 4: Pulse Augmentation Test.

4- Arm Elevation Test (evaluates the outflow portion of the AV access).

- Unfortunately, this maneuver does not work with an AVG because of the higher level of pressure that characterizes this type of access. In the patient with an AVF,
- The access is generally distended when the arm is dependent due to the effects of gravity. (Figure 5-A)
- If the arm is then elevated to a level above that of the heart, the AVF should collapse. Even if the patient has a large dilated AVF, it should become flaccid. Forearm AVF (complete collapse) Figure 5-B.
- Upper arm AVF (partial collapse)
- However, **if a venous stenosis is present**, only the portion of the AVF proximal to the lesion will collapse while that **portion distal to the site will remain distended**.
- One can conclude with a reasonable degree of confidence that the outflow of the access is normal if the patient's AVF collapses when the arm is elevated.

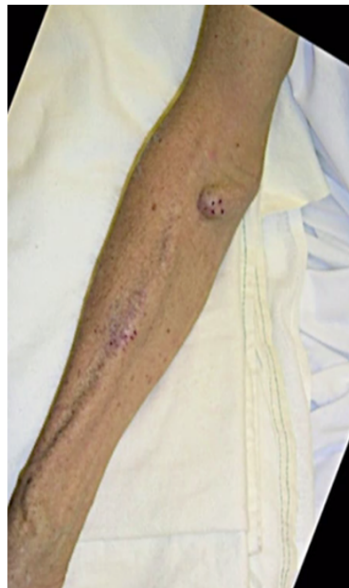

Figure 5-A: Arm Elevation Test

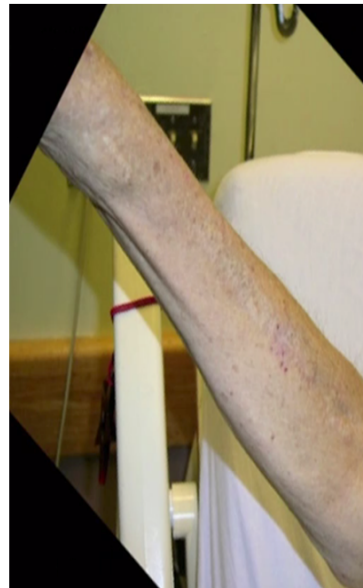

Figure 5-B: Arm Elevation Test

5-Clinical Features (Significance of Clinical Indicators)

1. The extent of the edema can help in predicting the location of the central venous stenosis. Figure 6.

- If the edema involves only the arm, this suggests that the stenosis is at the level of the subclavian vein.
- If the edema includes the ipsilateral chest, breast, and/or face, the stenosis is most likely at the level of the brachiocephalic vein.
- Edema that includes both sides (chest, breasts, shoulders, face) is suggestive of superior vena cava stenosis.

2. **Prolonged bleeding post- dialysis indicates** high venous pressure (outflow stenosis).

3. Difficulty with needle placement indicates intra-access stenosis (inflow stenosis).

4. Pain in access arm or hand indicates high venous pressure (outflow stenosis).

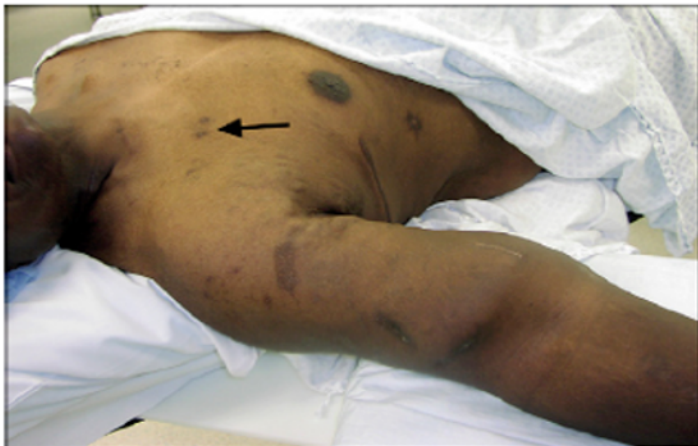

Figure 6: Right arm swelling and arrow indicates old catheter sites.

Access Normal Examination

- Thrill:-continuous.
- Pulse:-soft and easily compressible.
- Augmentation test:-Augment well-thrill will disappear.
- Arm elevation test: -collapses.
- Edema:-absent.

Access Thrombosis

- Pulse:-absent.
- Thrill:-absent.
- Augmentation test:-should not be done
- Arm elevation:-irrelevant.
- Edema: -absent.

Stenosis

A-Outflow:

- Hyper pulsatile (angry pulse).
- Systolic thrill

B-Inflow:

- Hypo pulsatile (feeble pulse).
- Systolic thrill

Results:

Among **36** hemodialysis patients **14** of them had physical examination abnormalities which represent around 39% of immature access, those patients underwent retrograde and ante grade angiography by interventional radiology (IR). Figure 7

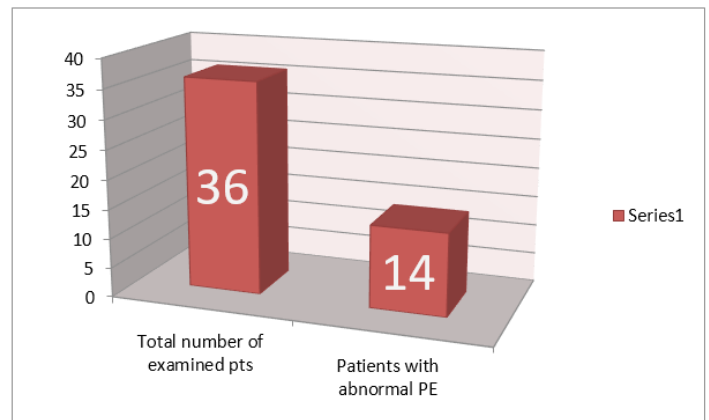


Figure 7: Number of patients involved in the study and with abnormal PE.

There was strong agreement between physical examination and angiography in the diagnosis and localization of outflow and inflow stenosis. Figure 8.




Figure 8: Number of patients with abnormal PE finding and who need Angioplasty.

Among the 14 patients who underwent angioplasty; 11 patients the access became mature and 3 patients did surgical revision. (2 patients had transposition of the veins and 1 patient need AV Graft removal and AV fistula creation).

After 2 years of this project, number of immature vascular access decreased from 14/36 (39%) to 2/36 (6%).Figure 9.

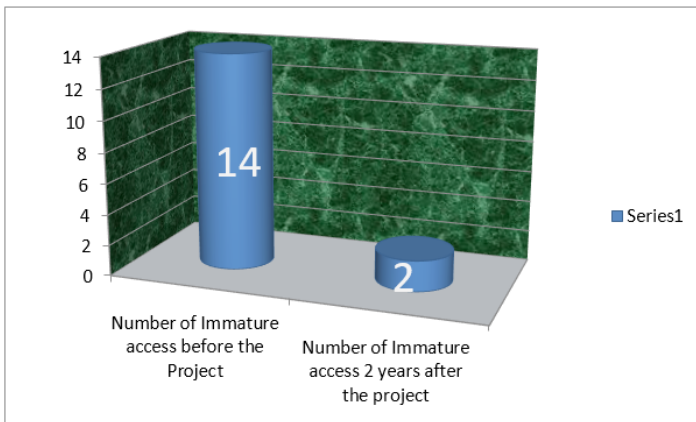


Figure 9: Number of Immature access before the project and after 2 years the project.

Conclusions:

The findings of this study demonstrate that physical examination can accurately detect and localize Stenosis in a great majority of hemodialysis arterio venous access.

This will lead to early intervention and prevention of access dysfunction.

Physical examination PE should be taught to all hemodialysis care givers and should be performed on a regular basis on all hemodialysis patients.

References

1. NKF-KDOQI (2006) Clinical Practice Guidelines for Vascular Access. AJKD 2006 Jul 48 Suppl 1:S176-247.
2. Eknoyan G, Levin NW (2002) Impact of the new KDOQI guidelines. Blood Purif 20: 103-108.
3. Baltimore M (2004) 2004 Annual Report ESRD Clinical Performance Measures Project. Department of Health and Human Services, Centers for Medicare & Medicaid Services, Center for Beneficiary Choices.
4. Ronald LP, Young EW, Dykstra DM, Greenwood RN, Hecking E, et al.(2002)Vascular access use in Europe and the United States: results from the DOPPS. Kidney Int 61:305-316.
5. Kaufman JL (1995) The decline of the autogenous hemodialysis access site. Semin Dial 8:59-61.
6. Bethesda MD (1995) The Cost Effectiveness of Alternative Types of Vascular access and the Economic Cost of ESRD. National Institute of Diabetes and Digestive and Kidney Diseases 139-157.
7. Feldman HI, Kobrin S, Wasserstein A (1996) Hemodialysis vascular access morbidity. J Am Soc Nephrol 7: 523-535.