



Research Article

Good Survivorship of Small Femoral Corail® Stems in Asian Population using Direct Anterior Approach

WAN jon yin joseph, YUEN jin Chuan, PANG hee nee

Department of Orthopaedic Surgery, Singapore General Hospital, Outram Road, Singapore, 169608, Singapore

*Corresponding author: Wan Joseph Jon Yin, Department of Orthopaedic Surgery, Singapore General Hospital, Outram Road, Singapore, 169608, Singapore

Citation: Wan JYJ, Yuen JC, Pang HN. (2024) Good Survivorship of Small Femoral Corail® Stems in Asian Population using Direct Anterior Approach. J Surg 9: 1982 DOI: 10.29011/2575-9760.001982

Received Date: 13 January, 2024; Accepted Date: 18 January, 2024; Published Date: 20 January, 2024

Abstract

Introduction: Corail® Femoral stems is commonly used cementless Total Hip Arthroplasties (THA) with good long-term patient outcomes. Multiple Caucasian Joint Registries studies from found higher rates of revision in smaller femoral stem sizes compared with the larger sizes, commonly due to loosening.

Method: Single-surgeon, single centre retrospective cohort study of 164 Asian patients with primary THA via the direct anterior approach using Corail® cementless stems. Propensity matching was performed for body mass index, age, gender, Dorr's classification. Complications, rate of revision and patient-reported outcomes were compared between the small-stem group (size 8 to 10; n= 94) and large-stem group (size 11 and above; n= 70).

Results: No difference in stem-related complication rates (hazards ratio 1.49; p = 0.637) was found in between the small and large stem groups at mean follow-up of 4.5 years. No stem loosening was measured in either groups; 1 case of stem subsidence was reported in the small stem group, due to a conservatively managed of peri-prosthetic fracture. BMI is found to be independent predictors of stem complications, whereas no difference in complications are calculated between the different age groups and Dorr types.

Conclusion: Our study is the first demonstrating comparable survivorship between small and larger size cementless femoral stems Corail® for primary THAs. This is likely due to smaller stature and femoral canal dimensional differences in Asian population. Adequate distal reaming, use of fluoroscopy during the direct anterior approach will assist the surgeon in appropriately sizing and positioning the implant to enhance survivorship.

Introduction

Corail® Femoral stems (Depuy Synthes Ltd) is a commonly used in cementless total hip arthroplasty with extensive hydroxyapatite (HA) coating. Options are available for two different offsets, two different neck-shaft angles and neck lengths, collared or collarless stems [1]. Good results have been reported over long-term studies since its introduction 25 years ago [2,3]. Recent arthroplasty registry data in Caucasian populations have suggested poorer survivorship with smaller Corail® stem sizes, resulting in higher rates of complication and revision [4-6]. This is likely due to undersizing or sub-optimal positioning of the femoral stem, leading to increased osteolysis and thus loosening. The Dorr

Classification is commonly used to describe bone quality of the proximal femur, classifying into 3 categories (A, B, C) based on the ratio of the inner diameter of the metaphysis at the level of lesser trochanter and the inner diameter 10 cm distally [7]. Asian femoral geometry have been reported to differ from that of Caucasians [8], with lesser femoral head offset and significantly narrower coronal and sagittal inner diameter at the isthmus [9]. This results in a larger proportion of “trumpet-shaped” endosteal cavity (Dorr Type A) rather than the “stovepipe” morphology (Dorr Type C) seen in Caucasians. The aim of this study is to investigate the survivorship and outcomes of small Corail® stems in Asian patients, given the rapidly increasing hip pathologies facing us with an ageing population.

Methods

A single-surgeon, single centre retrospective cohort study was performed on 141 included Asian patients from Singapore General Hospital yielding 164 THAs performed via the direct anterior approach with Corail® cementless femoral stems between 2014-2019. Patients with insufficient follow-up of less than 2 years were pre-excluded. Pre- and post-operative pelvis radiographs were extracted from Singhealth's Picture Archiving and Communications System (PACS) and measurements made for femoral canal diameter (Dorr Classification), neck-shaft angle and stem subsidence. Demographic details including patient age, gender, Body Mass Index (BMI), indication for THA and complications were obtained from their medical records. Stem subsidence is measured on the anteroposterior pelvis plain radiograph by measuring the difference in distance from the trochanter major's peak to the stem shoulder perpendicular to the axis of the femur stem. The threshold of subsidence >3 mm was considered as a clinically significant migration. 2-year post-operative patient-reported outcome measures were also collected, including Oxford Hip Score and Western Ontario and McMaster Universities Osteoarthritis Index (WOMAC). Patients were grouped into either the small stem group (Corail® sizes 8 to 10; n= 94) or the large stem group (sizes 11 and above; n= 70). All statistics were analysed using SPSS Statistics Package Version 26 (IBM, Armonk, New York, USA). In the analysis of nominal or ordinal data, chi-squared test and Fisher's exact test were used, whereas student's t test and Spearman's ranking was used for parametric and non-parametric continuous data respectively. Threshold for statistical significance was set at p-value ≤ 0.05.

Direct Anterior Approach Technique (Figure 1)

The hip Direct Anterior Approach (DAA) is chosen as it is the most practised approach by the senior surgeon in this study, and positioning the patient in supine position allows the use of intra-operative fluoroscopy. After intra-operative prophylactic intravenous antibiotic administration, DAA is performed through Smith-Peterson incision extending over the tensor fascia lata from the anterior superior iliac spine towards the lateral epicondyle. Care is taken to protect the lateral femoral cutaneous nerve of the thigh when dissecting the internervous plane between tensor fascia lata and sartorius, the rectus femoris is then retracted to expose the anterior hip joint capsule. Capsulectomy is performed with cauterisation of lateral femoral circumflex artery and femoral neck cut is made with oscillating saw. The femoral head is removed, exposing the acetabulum. The acetabular labrum is excised, followed by sequential reaming to femoral head size, with medialization to true acetabular floor. Acetabular cup then inserted at 40° inclination with 20° anteversion, acetabular cup is considered press-fit if the final-implanted cup is able to move pelvis without changing position.

Femoral canal is delivered out of the wound in the figure-of-4 position, with the help of Hohmann retractors posterior to the greater trochanter and medially above the lesser trochanter. The assistant adducts the leg to improve the exposure of the femoral canal, which is broached sequentially to good press-fit. Stem is considered well-fixed if there is axial and rotational stability, and fluoroscopy is used to check position and sizing of stem. Trial reduction is performed to confirm stability prior to insertion of actual implants, with subsequent fluoroscopic checks for stem sizing and positioning.

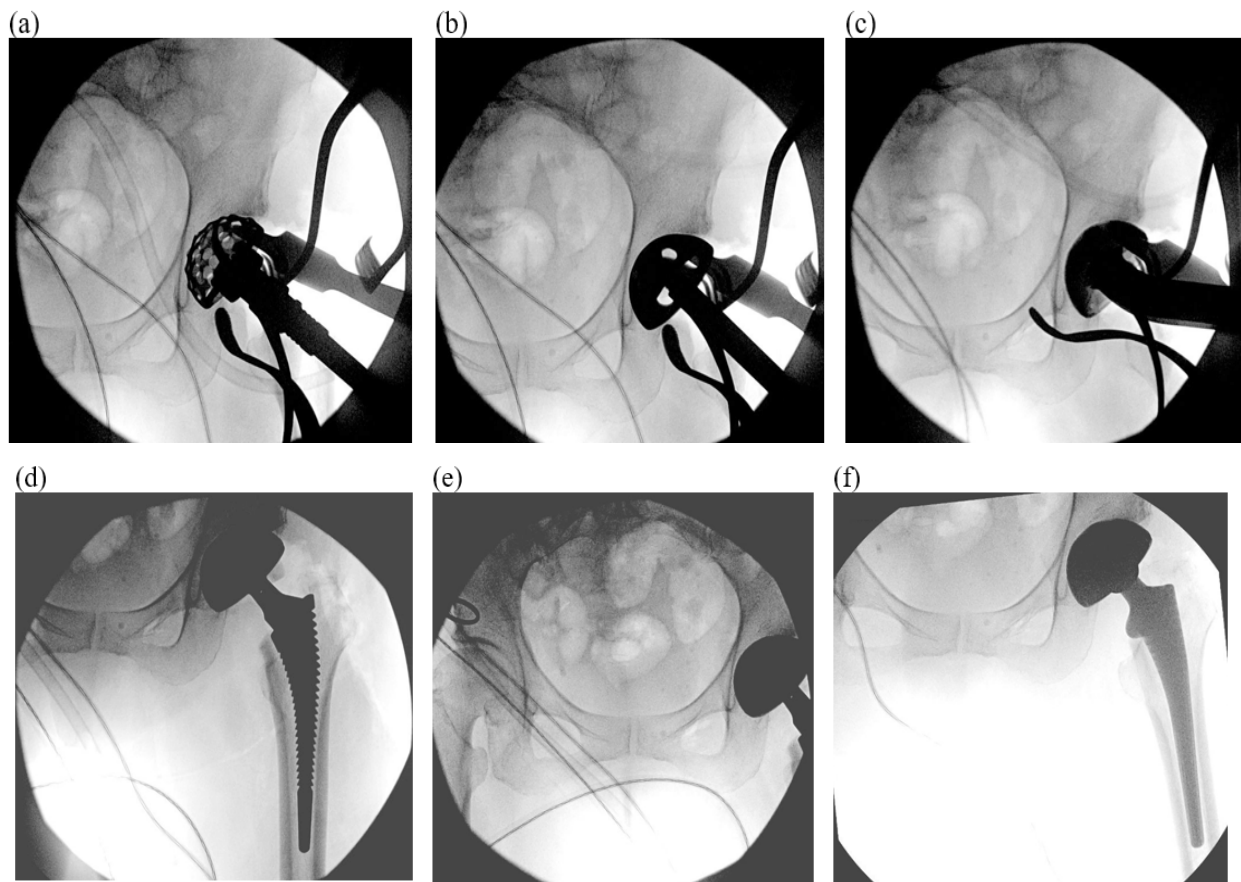


Figure 1: Direct anterior Approach (a) reaming acetabular cup to femoral head size; (b) trialing and (c) press-fit implantation of acetabular cup. (d) Trial reduction performed with broach stem and (e) limb length comparison with contralateral hip. (f) Implantation and reduction of final uncemented femoral stem.

Results

Age and weight distribution are similar in both small and large stem groups; whereas the small stem group (n= 94) has a significantly larger proportion of female patients (77.4% vs 37.1%, $p < 0.001$). The small stem group also had a higher proportion of innate Dorr's A femur (75.3% vs 60.0%), although distribution of Dorr's types were not statistically significant (Table 1).

Average follow-up was 4.5 year and mean inpatient length of stay is similar in both groups. The small stem group (n= 94) had 8 overall complications (8.5%) with 2 requiring re-operation; whereas the large stem group (n= 70) had 6 overall complications (8.6%) and 4 requiring reoperations (Table 2). 1 patient in the

large stem group died 5 years post-operation of pancreatic adenocarcinoma, and is not recorded as a complication. Rate of overall complications and stem-related complications are not statistically significant between the 2 groups. No stem subsidence, loosening or peri-operative mortality is reported in this study (Table 3). Improvement in Oxford Hip Score and WOMAC Scores for hip pain, stiffness and functional outcomes on 2-year follow-up was not statistically different between the small and large stem groups. death 5 years post-operatively from pancreatic adenocarcinoma.

Further subgroup multi-variate analysis demonstrated BMI as an independent risk factor for stem complications ($p < 0.001$), whereas age and Dorr's type had no impact on complications, length of inpatient stay and patient follow-up outcomes (Table 4).

Demographics			Small Stem (n= 94)		Large Stem (n= 70)		p-value
			Freq	%	Freq	%	
Age	≤ 55		15	16.0%	14	20.0%	0.446
	56-65		37	39.4%	26	37.1%	
	66-75		26	27.7%	22	31.4%	
	>75		16	17.0%	8	11.4%	
	Mean Age (std dev)		63.83	(12.56)	62.31	(11.07)	
BMI	Underweight	< 18.5	4	4.3%	0	0.0%	0.1133
	Normal	18.5-24.9	43	46.7%	21	31.3%	
	Pre-Obesity	25.0-29.9	23	25.0%	37	55.2%	
	Obesity I	30.0-34.9	18	19.6%	6	9.0%	
	Obesity II	35.0-39.9	3	3.3%	0	0.0%	
	Obesity III	≥ 40	1	1.1%	3	4.5%	
Gender	Female		72	77.4%	26	37.1%	<0.001
	Male		21	22.6%	44	62.9%	
Dorr Type	A		71	75.5%	42	60.0%	0.082
	B		19	20.2%	25	35.7%	
	C		4	4.3%	3	4.3%	

Table 1: Distribution of patient demographic data (age, BMI, gender) and pre-op radiographic measurement (Dorr Type) in the small and large stem groups.

	Small Stem (n= 94)		Large Stem (n= 70)	
	Complication	Management	Complication	Management
Acetabular Component	- 1 aseptic loosening	Revision surgery	-	
	- 1 recurrent dislocation	Revision surgery	-	
Femoral Component	- 3 intra-operative calcar fractures	Intra-operative cerclage wiring, no further complications	- 1 Recurrent dislocation	femoral revision with extended trochanteric osteotomy
	- 1 post-operative femoral peri-prosthetic fracture	Patient declined further operation	- 1 post-operative femoral peri-prosthetic fracture	Long stem revision
Wound complications	- 1 hypersensitivity reaction to dressing	Intravenous antibiotics	- 1 wound dehiscence	Wound debridement and closure
			- 1 wound seroma	Oral antibiotics
Others	- 1 peroneal nerve palsy likely traction-related	-	- 1 Early prosthetic joint infection	Debridement and exchange of acetabular polyethylene liner

Table 2: Summary of complications in the small and large stem groups.

Descriptive		Small Stem (n= 94)		Large Stem (n= 70)	p-value		
		Freq	%	Freq	%		
Length of stay	≤ 2 days	50	53.2%	37	52.9%	0.966	
	> 2 days	44	46.8%	33	47.1%		
Overall Complication	No	86	91.5%	65	92.9%	0.748	
	Yes	8	8.5%	5	7.1%		
Stem Complication	No	90	95.7%	68	97.1%	0.637	
	Yes	4	4.3%	2	2.9%		
Subsidence	No	94	100.0%	70	100.0%	-	
	Yes	0	0.0%	0	0.0%		
Loosening	No	93	100.0%	70	100.0%	-	
	Yes	0	0.0%	0	0.0%		
Descriptive		Small Stem (n= 67)		Large Stem (n= 51)		z-value	p-value
		Mean	SD	Mean	SD		
Oxford Hip Score	Pre-operative	38.99	10.85	35.12	7.90		
	Post-operative	16.15	5.98	13.33	2.56		
	Improvement	22.84	11.41	21.37	8.37	-1.263	0.207
WOMAC (Pain)	Pre-operative	54.33	25.48	62.86	21.29		
	Post-operative	97.46	6.60	99.61	1.79		
	Improvement	43.13	24.64	36.49	21.49	-1.359	0.174
WOMAC (Stiffness)	Pre-operative	59.93	33.26	67.65	26.75		
	Post-operative	93.66	18.08	95.78	10.65		
	Improvement	33.73	36.87	27.60	29.20	-1.008	0.314
WOMAC (Function)	Pre-operative	46.02	23.62	56.41	23.00		
	Post-operative	89.28	15.81	95.42	8.13		
	Improvement	43.27	21.55	38.27	22.88	-1.417	0.156

Table 3: 2-year complications and patient-reported outcomes (Oxford Hip Score and WOMAC) in the small and large stem groups.

Demo graphics	Overall Complication	Stem Complication	Length of Stay ≤2 days	>2 days	Oxford Hip Score	WOMAC Pain	Stiffness	Function	
	Freq (%)	Freq (%)	Freq	Freq	Mean (SD)	Mean (SD)	Mean (SD)	Mean (SD)	
Age	≤ 55	2 (6.90)	0 (0)	16	13	21.6 (10.59)	39.0 (26.75)	34.7 (38.17)	38.0 (25.31)
	56-65	5 (7.94)	2 (3.17)	32	31	23.8 (8.64)	42.3 (22.89)	31.7 (35.47)	45.0 (23.47)
	66-75	4 (8.33)	3 (6.25)	28	20	22.8 (9.57)	38.9 (23.37)	26.7 (30.57)	40.8 (21.32)
	>75	2 (8.33)	1 (4.17)	11	13	18.2 (13.34)	37.9 (23.35)	34.25 (32.70)	35.6 (17.14)
	p-value	0.834	0.263	0.799		0.595	0.732	0.728	0.415
BMI	Underweight (< 18.5)	1 (25.0)	1 (25.0)	1	3	32 (2.83)	10 (14.14)	80.0 (0)	63 (5.66)
	Normal (18.5-24.9)	2 (3.08)	1 (1.54)	36	29	20.5 (12.04)	41.8 (20.98)	26.6 (35.43)	37.1 (21.63)
	Pre-Obesity (25.0-29.9)	6 (10.0)	2 (3.33)	30	30	20.9 (8.51)	35.8 (24.96)	29.1 (31.18)	38.1 (22.15)
	Obesity I (30.0-34.9)	2 (8.33)	0 (0)	15	9	25.1 (7.90)	44.7 (24.43)	35.5 (34.90)	48.5 (17.56)
	Obesity II (35.0-39.9)	0 (0)	0 (0)	1	2	21.7 (8.14)	38.0 (21.17)	41.7 (27.54)	38.4 (23.99)
	Obesity III (≥ 40)	2 (50.0)	2 (50.0)	1	3	26.2 (10.70)	45.3 (21.89)	41.9 (27.43)	50.6 (27.39)
p-value	0.49	<0.001	0.981		0.224	0.485	0.547	0.07	
Dorr	A (113)	10 (8.85)	4 (3.54)	68	45	22.2 (10.86)	41.8 (24.52)	31.5 (35.06)	41.3 (23.16)
	B (44)	3 (6.82)	2 (4.55)	17	27	22.0 (9.21)	36.9 (22.15)	32.7 (31.80)	42.0 (21.01)
	C (7)	0 (0)	0 (0)	2	5	23.0 (5.66)	33.3 (13.95)	15.8 (24.98)	32.83 (14.48)
	p-value	0.667	0.832	0.022		0.976	0.481	0.523	0.643

Table 4: 2-year complications and patient-reported outcomes (Oxford Hip Score and WOMAC) across demographic factors.

Discussion

Cementless femoral stems work by achieving a wide, stable implant-bone interface that encourages bone ingrowth, thus stable and close geometric fit proximally is essential towards initial and long-term stem fixation [8]. The Corail® stem is double-tapered and fully coated hydroxyapatite to achieve proximal medial-lateral cancellous bone press-fit, while the grooves are horizontally oriented proximally to convert shear forces into compressive forces. Distally, the tapered stem has vertical grooves to increase contact surface area [1]. Radio-stereometric analysis by Campbell et al [10] showed Corail® stem mean subsidence (distal migration) of 0.58mm at 2 years, and was largely confined to the first 6 months of implantation with negligible subsidence occurring in the subsequent 18 months. Poorer survivorship has been reported with smaller Corail® stem sizes in Western Caucasian, with significantly increased rates of subsidence and up to 4 times rate of revision surgery reported in the United Kingdom [4], Australian [5] and Norwegian [6] Joint Arthroplasty Registers. The authors report aseptic loosening as the most common cause of small stem failure, hypothesising it as the result of inadequate press-fit and poor bone quality [11]. No difference in survivorship was reported between collared and collarless implants [12].

No data exist in literature for Asian population studying survivorship and outcomes of small Corail® stems. The canal-flare index (CFI) was described by Noble et al [13] to characterise the shape of the medullary canal in the proximal femur, which is a ratio of the intra-cortical widths of the femur at 20mm proximal to the centre of the lesser trochanter and at the canal isthmus. CT 3D modelling studies [8,9] demonstrated significant differences in femoral canal geometry between Caucasian and Asian populations. Asian populations tend to have wider proximal femur medial-lateral widths with a higher CFI [14], which is also reflected in the high proportion of Dorr Type A femurs in our study population. Implant fit analysis on Corail® stems showed a higher proportion of distal stem diaphyseal fitting in Asians as compared to Caucasian [8], which can perhaps account for the lower rates of subsidence in our study. However, femoral stem undersizing has been a concern raised with high CFI femurs due to potting of the tapered wedge stem distally in the narrow canal, with insufficient proximal metaphyseal cortical contact [15]. This can then lead to reduced bony ingrowth and thus rotational instability and increased wear and loosening.

Despite being technically demanding on the surgeon, the direct anterior approach is known for its muscle-sparing advantage, with reducing dislocation risks and eliminating need for post-operative hip precautions [15]. There has been debate in literature regarding the reduced visual field during surgery, giving rise to concerns of neurovascular injury, excessive anteversion

and femoral stem undersizing. Stem under-sizing, in both post-op radiological analysis of canal-fill index and against pre-operative templating, has been reported to be more prevalent in DAA than in the more commonly used posterior approach [16]. A cohort study by Watanabe et al. [15] analysing post-operative CT scans demonstrated higher risks of cup and stem anteversion in younger patients. Acetabular exposure is never an issue in both approaches the DAA suffers inherently insufficient femoral exposure due to limited hip extension. This difficulty can be increased in cases of short varus neck, or excessive surrounding soft tissue in muscular obese patients, posing challenges to obtain adequate broach alignment and optimal press-fit sizing [16]. Supine positioning in DAA will allow the use of fluoroscopy to assess stem sizing and alignment, allowing the surgeon to make corrections intra-operatively whilst trialling implants.

Study Design

Our study cohort size is relatively small with relatively short follow-up observation to study long-term survivorship and loosening of implants. The study is of retrospective design, which subjects to bias and confounding that can influence the result. Measurement errors have also been reported in neck-shaft angle, which can be skewed by the rotation of the lower limb in the antero-posterior pelvic radiographs. The strengths of this study lies in it being in single-centre and single senior surgeon, who is well-versed in the DAA technique, granting replicable surgical technique and gauge for implant sizing and alignment. Use intra-operative fluoroscopy has also allowed intra-operative checks and correction of stem alignment and fitting. More post-operative implant-fit analysis will be required to assess adequate sizing of the femoral stems.

Conclusion

Survivorship of cementless femoral stem is comparable between small and large Corail® stems in Asian patients, with no incidence of stem subsidence or loosening recorded in our study. Improvement in post-operative patient reported outcome measures and functionality (OHS and WOMAC) are also similar between both groups. This is likely to be due to the smaller isthmus diameter in Asians with a higher CFI, which confers stronger axial stability, but might predispose to rotational instability. Optimal femoral exposure is crucial whilst performing a minimally invasive and tissue-sparing approach like the DAA, to ensure optimal broach alignment and sizing during reaming. Intra-operative fluoroscopy, or the use of computer or robotic-assisted navigation, is also recommended to check and correct stem alignment and sizing during trial reduction. Further stem-fit analysis will be required to study optimal sizing in Asian femoral canals; as well as longer-term follow-up studies to investigate complications, as well as to study complications such as peri-prosthetic fractures.

References

1. Corail® (2013) Primary Femoral Prosthesis. DePuy Synthes Hip Specifications 2013: 20.
2. Vidalain JP (2011) Twenty-year results of the cementless Corail stem. *International orthopaedics* 35: 189-194.
3. Xu J, Xie Z, Zhao J, Gao Y, Zhao H, et al. (2016) Results of a hydroxyapatite-coated femoral stem (Corail) in Chinese: a minimum 10-year follow-up. *Springerplus* 5: 1-5.
4. Jameson SS, Baker PN, Mason J, Rymaszewska M, Gregg PJ, et al. (2013) Independent predictors of failure up to 7.5 years after 35 386 single-brand cementless total hip replacements: a retrospective cohort study using National Joint Registry data. *The bone & joint journal* 95: 747-757.
5. Hoskins WT, Bingham RJ, Lorimer M, de Steiger RN (2020) The effect of size for a hydroxyapatite-coated cementless implant on component revision in total hip arthroplasty: an analysis of 41,265 stems. *The Journal of Arthroplasty* 35: 1074-1078.
6. Melbye SM, Haug SC, Fenstad AM, Furnes O, Gjertsen JE, et al. (2021) How does implant survivorship vary with different Corail femoral stem variants? Results of 51,212 cases with up to 30 years of follow-up from the Norwegian Arthroplasty Register. *Clinical Orthopaedics and Related Research* 479: 2169-2180.
7. Dorr LD, Faugere MC, Mackel AM, Gruen TA, Bogner B, et al. (1993) Structural and cellular assessment of bone quality of proximal femur. *Bone* 14: 231-242.
8. Wuestemann T, Hoare SG, Petersik A, Hofstaetter B, Fehily M, et al. (2021) Bone morphology of the proximal femoral canal: ethnicity related differences and the influence on cementless tapered wedge stem designs. *HIP International* 31: 482-491.
9. Chiu KY, Fang D (1997) Endosteal shape of the proximal femur in Chinese. *Journal of Orthopaedic Surgery* 5: 21.
10. Campbell D, Mercer G, Nilsson KG, Wells V, Field JR, et al. (2011) Early migration characteristics of a hydroxyapatite-coated femoral stem: an RSA study. *International orthopaedics* 35: 483-488.
11. Gema A, Irianto KA, Setiawati R (2021) Femoral Stem Subsidence and its Associated Factors after Cementless Bipolar Hemiarthroplasty in Geriatric Patients. *Malaysian orthopaedic journal* 15: 63.
12. Song JH, Jo WL, Lee KH, Cho YJ, Park J, et al. (2019) Subsidence and perioperative periprosthetic fractures using collarless hydroxyapatite-coated stem for displaced femoral neck fractures according to Dorr type. *Journal of Orthopaedic Surgery* 27: 2309499019877530.
13. Noble PC, Box GG, Kamaric E, Fink MJ, Alexander JW, et al. (1995) The effect of aging on the shape of the proximal femur. *Clinical orthopaedics and related research* 1995: 31-44.
14. Fang C, Chiu KY, Tang WM, Fang D (2010) Cementless total hip arthroplasty specifically designed for Asians: clinical and radiologic results at a mean of 10 years. *The Journal of arthroplasty* 25: 873-879.
15. Watanabe K, Mitsui K, Usuda Y, Nemoto K (2019) An increase in the risk of excessive femoral anteversion for relatively younger age and types of femoral morphology in total hip arthroplasty with direct anterior approach. *Journal of Orthopaedic Surgery* 27: 2309499019836816.
16. Rivera F, Leonardi F, Evangelista A, Pierannunzi L (2016) Risk of stem undersizing with direct anterior approach for total hip arthroplasty. *Hip International* 26: 249-253.