



Case Report

A Large Ruptured Dissecting Internal Carotid Artery Aneurysm Treated by Flow Diverter and Coil Embolization: A Case Report and Literature Review

Kazumoto Suzuki¹, Yumiko Mitome-Mishima^{1*}, Kohsuke Teranishi¹, Akihide Kondo¹, Hidenori Oishi^{1,2}

¹Department of Neurosurgery, Juntendo University Faculty of Medicine, Tokyo, Japan

²Department of Neuroendovascular Therapy, Juntendo University Faculty of Medicine, Tokyo, Japan

*Corresponding author: Yumiko Mitome-Mishima, Department of Neurosurgery, Juntendo University Faculty of Medicine, 2-1-1 Hongo, Bunkyo-ku, Tokyo 113-8421, Japan

Citation: Suzuki K, Mitome-Mishima Y, Teranishi K, Kondo A, Oishi H (2023) A large ruptured dissecting internal carotid artery aneurysm treated by flow diverter and coil embolization: a case report and literature review. Int J Cerebrovasc Dis Stroke 6: 146. DOI: <https://doi.org/10.29011/2688-8734.1000146>

Received Date: 24 March, 2023; **Accepted Date:** 04 April, 2023; **Published Date:** 07 April, 2023

Abstract

Objective: We herein report a rare case of a ruptured internal carotid dissecting aneurysm treated with a flow diverter. **Case Presentation:** A 32-year-old man presented with a subarachnoid hemorrhage secondary to a ruptured internal carotid dissecting aneurysm. The aneurysm was treated by flow diverter (Pipeline embolization device) and coil embolization in the chronic phase. Rerupture occurred prior to the procedure, and a small amount of subarachnoid hemorrhage was observed after the procedure, but the modified Rankin scale score was unchanged from the onset of subarachnoid hemorrhage (modified Rankin scale score: 1). Eight-month follow-up digital subtraction angiography indicated O'Kelly–Marotta grade D and showed that the aneurysm was completely occluded. Four years have passed without recurrence. This management resulted in minimum hemorrhagic complications and no ischemic complications. **Conclusion:** Pipeline embolization device treatment in the chronic phase is valid to obtain good vascular reconstruction.

Introduction

Cerebral dissecting aneurysm, which may be asymptomatic, is a specific pathology that causes headache, cerebral infarction, and subarachnoid hemorrhage (SAH). SAH caused by dissecting aneurysms develops earlier than that caused by ruptured true saccular aneurysms and results in premature rebleeding, especially within 24 hours [1]. When SAH develops, radical surgery is generally required to prevent rebleeding, and treatments comprise open surgery and endovascular treatment. Both treatments require the selection of either vessel deconstruction or reconstruction. In

open surgery, proximal ligation and trapping are performed for vessel deconstruction, and internal carotid artery (ICA)–external carotid artery bypass and a clip-wrap technique are performed for vessel reconstruction; however, this is highly invasive. In endovascular treatment, parent artery occlusion is performed for vessel deconstruction along with aneurysmal occlusion and stent-assisted coil embolization. Flow diverters (FDs) have recently been used in vessel reconstruction. Together with a discussion of the literature, we herein report a case of Pipeline embolization device (PED) deployment for a ruptured ICA dissecting aneurysm treated in the chronic phase of SAH.

Case Presentation

A 32-year-old man experienced a sudden-onset headache. Four days after onset, he was admitted to a neighboring hospital with a diagnosis of SAH with right frontal lobe hemorrhage (Hunt & Kosnik classification grade 2, Fisher grade 4) (Figure 1A). The patient had no remarkable medical history, family history, or history of trauma. Digital subtraction angiography (DSA) showed irregular vascular dilatation and stenosis, predominantly in the anterior wall of the ICA, exhibiting the string-of-pearls sign from the paraclinoid portion of ICA to middle cerebral artery (M1 portion) (dilated part of C1–2 portion; longest diameter: 10.0 mm; shortest diameter: 7.6 mm) (Figure 1B–D). Based on these angiographic findings, rapid growth in a short period of time, young age, no risk factors for atherosclerosis, and no family history, the probability of a ruptured dissecting ICA aneurysm was considered. Because an occlusion test of the right ICA contraindicated therapeutic sacrifice of the parent artery, an alternative strategy

using endovascular reconstruction with a PED was proposed in the chronic phase of SAH. Coil embolization was added to prevent delayed aneurysmal rupture. The patient was transferred to our institution for endovascular management. He presented with mild disturbance of consciousness (Glasgow coma scale score: E3V4M6), hand motion visual acuity, and incomplete oculomotor nerve palsy due to compression by the aneurysm. Because the risk of rerupture while waiting was judged to be high, antiplatelet therapy was scheduled to be performed immediately before the procedure. As expected, rerupture occurred prior to the procedure without neurological deterioration (Figure 1E). Therefore, the patient was treated with antiplatelet therapy (clopidogrel: 75 mg, followed by aspirin: 200 mg and clopidogrel: 150 mg). Platelet aggregation activity was assessed before the procedure using the VerifyNow test (Accumetrics, San Diego, CA, USA), with values of 200 P2Y12 reaction units (PRU) (inhibition 8%) [Prior to dual antiplatelet therapy (DAPT)] and 385 aspirin reaction units (ARU) 48 hours after starting DAPT.

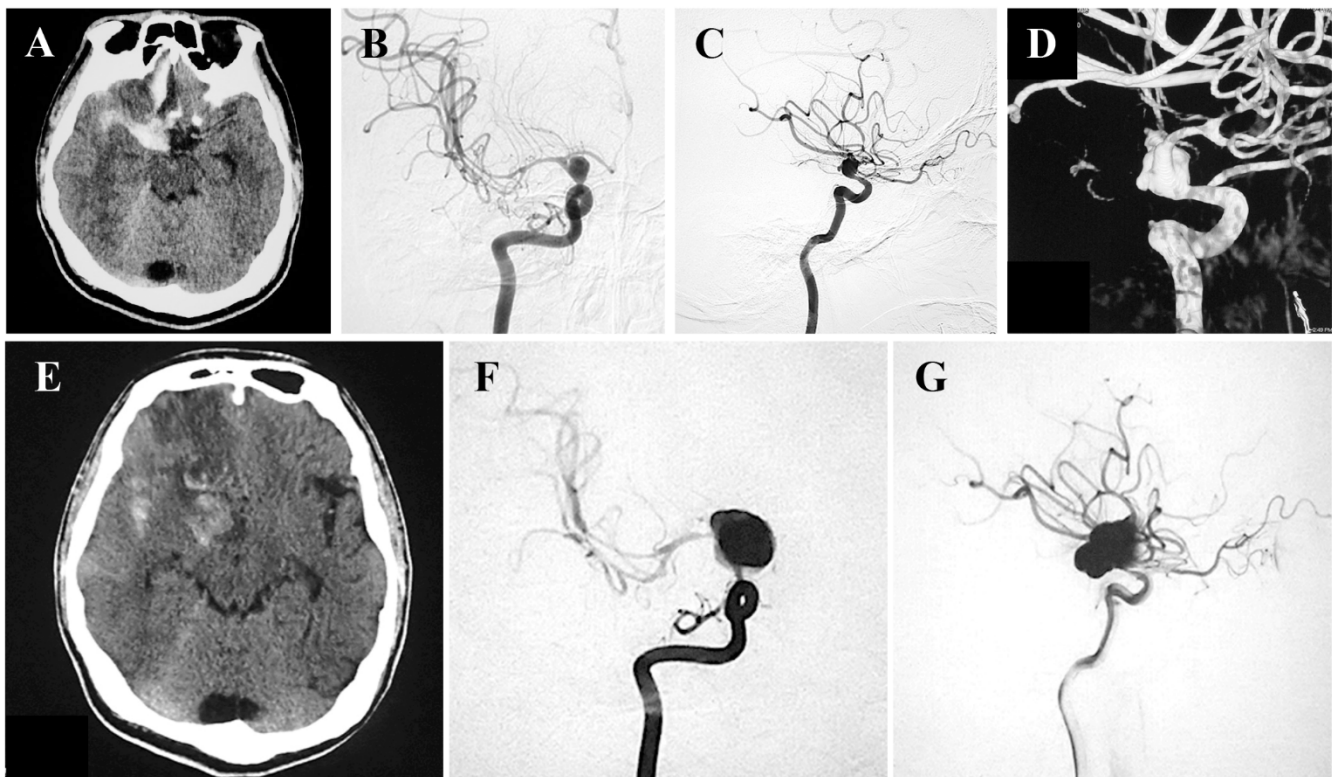


Figure 1: Unenhanced axial CT scan and DSA (A–D) at onset in the previous hospital and (E–G) at the time of rerupture at our institution. (A) CT showed subarachnoid hemorrhage and intracranial hemorrhage in the right frontal lobe. A bleeding source was identified in the right ICA dissecting aneurysm on (B, C) DSA and (D) three-dimensional DSA. Three-dimensional DSA showed irregular vessel dilatation exhibiting the string-of-pearls sign from the ICA (C2 portion) to the middle cerebral artery (M1 portion). (E–G) On DSA, the ruptured dissecting ICA aneurysm appeared larger. CT, computed tomography; DSA, digital subtraction angiography; ICA, internal carotid artery.

Twenty-nine days after onset, aneurysmal treatment was performed under general anesthesia (without systematic heparinization) to prevent rebleeding. The ruptured dissecting ICA aneurysm had become larger (longest diameter: 26.1 mm; shortest diameter: 17.1 mm) (Figure 1F and G). A 6-Fr guiding sheath (Axelguide STA, 6-Fr, 85 cm; Medikit, Tokyo, Japan) was inserted for PED placement via the right femoral artery approach, and a 5-Fr femoral artery long sheath and 5-Fr guiding catheter (5-Fr Envoy MPC, 90 cm; Cerenovus Spectra, Tokyo, Japan) were placed for coil embolization via the left femoral artery. First, an Excelsior SL-10 microcatheter (Stryker Neurovascular, Fremont, CA, USA) was coaxially inserted with the 6-Fr guiding sheath to guide the distal part of the PED to the aneurysm. The guidewire was extended using a Chikai extension wire (Asahi Intecc, Aichi, Japan), and the SL-10 was removed by the over-the-wire method. This was followed by insertion of a 5-Fr distal support catheter (Navien, 115 cm; Medtronic, Tokyo, Japan) and a microcatheter (Marksman, 150 cm; Medtronic), which were guided to the M1 segment for PED placement. An Excelsior SL-10 microcatheter

was inserted into the aneurysm coaxially with an Envoy guide catheter (Codman Neurovascular, Wokingham, UK). A Pipeline Flex embolization device (3.5 × 35 mm) (Medtronic) was deployed from M1 to C4, and percutaneous angioplasty was performed with a TransForm SC 4.0- × 7.0-mm occlusion balloon catheter (Stryker Neurovascular) because of stent non-apposition. Finally, we added coiling via the SL-10 microcatheter to prevent delayed aneurysm rupture (Figure 2A–C). Immediately after the procedure, minor SAH was detected by flat-panel detector computed tomography; therefore, strict blood pressure control was performed for 2 days under sedation. After extubation, the patient was drowsy, but he improved rapidly. The 8-month follow-up DSA showed O’Kelly–Marotta grade D, and wall apposition with the PED was verified (Figure 2D, E). The irregular caliber of the parent vessel had been smoothly repaired, and four years have passed without recurrence. The modified Rankin scale score was unchanged compared with the preoperative score for hand motion visual acuity and incomplete oculomotor palsy. Clopidogrel was suspended 15 months after the procedure, while aspirin was continued.

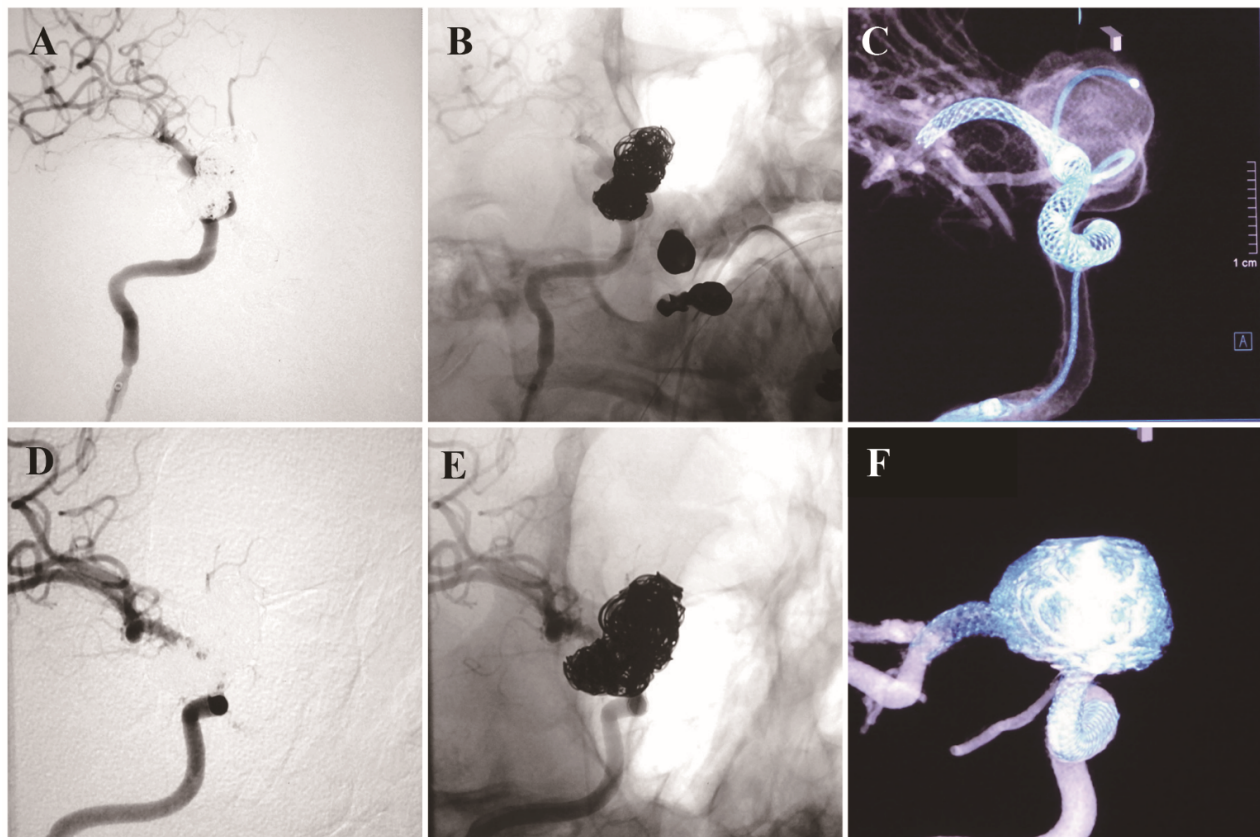


Figure 2: (A, B) Unsubtracted and subtracted angiograms showed additional coils in the aneurysm. (C) Cone-beam computed tomography after Pipeline embolization device deployment in the right internal carotid artery showed that the device was in the correct position. (D–F) Eight-month digital subtraction angiography follow-up images showed complete exclusion of the aneurysm and reconstruction of the dissecting vessel.

Discussion

We have herein reported our experience treating a ruptured ICA dissecting aneurysm with a PED in the chronic phase. This case suggests that PED treatment in the chronic phase of SAH may be used to obtain good vascular reconstruction without neurological deterioration.

The literature review was initially performed via a search of PubMed using the terms “dissecting aneurysm,” “intracranial ICA,” “flow diverter,” or “stent-assisted coil embolization.” We found few reports limited to dissecting intracranial ICA aneurysm (Tables 1,2) [1-5]. The time to treatment ranged from within 0 days to about 2 weeks after onset; no patients underwent treatment after 4 weeks, as in the present case. Rerupture occurred within 24 hours of onset in only one patient undergoing FD placement [1]. Stent-assisted coil embolization had a good outcome with few ischemic complications [3-5]. A high mortality rate was associated

with early perioperative rerupture and hemorrhagic complications in patients who had undergone FD treatment [1, 2]. DAPT loading was performed from 1 to 2 days prior to treatment and immediately before treatment. In our case, the diagnosis was made on day 4 after onset, delayed spasm was a concern, and the patient had no ischemic tolerance. In the previous reports, rerupture was common early after onset [1]. If rerupture does not occur early after onset, however, treatment in the chronic phase may be considered. Therefore, we suggest that FD placement in the chronic phase more effectively prevents rerupture than does FD placement in the acute phase. In our patient, although treatment was performed after 4 weeks, rerupture occurred immediately before treatment; therefore, we consider that it is better to perform treatment as early as possible to prevent rerupture. DAPT loading immediately before surgery seems to be the optimal strategy based on previous reports [6].

Table 1: Summary of reported cases of flow diverter treatment for internal carotid artery dissecting aneurysm

Authors (year)	Number of aneurysms	Rerupture	Days to treatment	Preoperative antiplatelet therapy	Complete occlusion (%)	Ischemic complications (n)	Mortality rate (n)
Lozupone et al. ¹ (2018)	5	1	0–1	Abciximab immediately following treatment	100%	0	40% (2)
Nerva et al. ² (2015)	4	0	4–15	DAPT (ASA 325 mg, CLO 75 mg) 1 day prior to treatment	75%	0	50% (2)
Zhang et al. ³ (2021)	19	0	4–15	ASA 300 mg, CLO 300 mg 3 hours before treatment	100%	1	5% (1)

DAPT: dual antiplatelet therapy, **ASA:** aspirin, **CLO:** clopidogrel

Table 2: Summary of reported cases of stent-assisted coil embolization for internal carotid artery dissecting aneurysm

Authors (year)	Number of aneurysms	Rerupture	Days to treatment	Preoperative antiplatelet therapy	Complete occlusion (%)	Ischemic complications (n)	Mortality rate
Zhang et al. ³ (2021)	8	0	4–15	DAPT (ASA 300 mg, CLO 300 mg) 3 hours before treatment	87.5%	0	0% (0)
Aihara et al. ⁴ (2021)	12	0	0–3	DAPT (ASA 300 mg, CLO 300 mg or prasugrel) 1–2 days prior to treatment	92%	4	0% (0)
Irie et al. ⁵ (2003)	1	0	>14	DAPT (ASA 300 mg, ticlopidine 250 mg)	N/A	0	0% (0)

DAPT: dual antiplatelet therapy, **ASA:** aspirin, **CLO:** clopidogrel, **N/A:** not available

Several reports have described FD treatment for ruptured intracranial aneurysms [1,2,6-9]. PED deployment for large and giant ICA aneurysms is widely accepted. This technique has gained popularity for many off-label neurovascular procedures during the last few years. It has been proven safe and efficacious for many of these off-label uses, whereas its use in some procedures may still require larger, more extensive studies to draw definitive conclusions. Parent artery reconstruction with FD devices in ruptured aneurysms appears to be safe and can be a valid alternative treatment when conventional surgical and endovascular techniques are challenging. The use of FDs is also an appropriate treatment method for iatrogenic carotid artery dissection, blood blister type aneurysms, and pseudoaneurysms because an intra-aneurysmal operation is less invasive than conventional intravascular surgery [2,8].

A dissecting cerebral aneurysm is not just a pseudoaneurysm abnormality; damage to the intima of the surrounding parent vessel is the main pathological condition. Therefore, endothelial formation must be induced in the parent vessel around the aneurysm as a whole. Although conventional stent-assisted coil embolization involves local treatment, FD deployment can result in remodeling and reconstruction of a wide range of tissues, including the parent vessel. PED placement has a good vascular reconstruction effect and cannot be performed with other treatments. A long FD may be difficult to deploy in areas with strong tortuosity and may increase the risk of thromboembolism because of increased metal coverage. However, a long FD was required in the present case because of the long lesion from the ICA C2 portion to M1.

Whether PED deployment alone is effective enough to prevent rebleeding of a ruptured ICA dissecting aneurysm is unclear; we herein proposed a treatment strategy to avoid delayed rupture by using coils. The necessity of coils should be considered as in cases of PED deployment for unruptured aneurysms [10]. Kulcsár et al. [10] identified four features that may be associated with an increased risk of delayed rupture: 1) large and giant aneurysms, which are potentially able to contain large, rapidly accumulated thrombi; 2) symptomatic aneurysms, which suggest recent growth and wall instability; 3) saccular aneurysms with an aspect ratio of >1.6 ; and 4) morphologic characteristics predisposing to an inertia-driven inflow that are not necessarily addressed by an FD device. Use of an FD and adjunctive coiling was effective in mitigating the small risk of delayed rupture in the present case.

This case report has two main limitations. First, there is possibility of deterioration associated with a delayed operation. Second, FD deployment in the acute phase of SAH is classified as off-label use in Japan and is a controversial treatment, although it has been previously reported. One of the reasons for this classification of off-label use involves the aneurysm occlusion process after FD deployment. In conventional coil embolization, intra-aneurysmal blood flow is initially blocked after the procedure. FDs are stent-like devices with a mesh structure constructed of braided metal wire,

and they can occlude the aneurysmal sac and cause thrombosis because of flow alternation when placed to cover the aneurysmal neck. However, this process takes weeks or months and cannot completely prevent rebleeding immediately after the procedure. In addition, there are risks of thromboembolic complications following FD deployment and hemorrhagic complications due to the use of antiplatelet drugs. Therefore, the indications for FD treatment for ruptured aneurysms must be considered carefully.

Conclusion

We have herein reported our experience with PED placement to treat a ruptured ICA dissecting aneurysm in the chronic phase. Our findings suggest that PED treatment in the chronic phase is valid to obtain good vascular reconstruction.

Acknowledgments

This study was supported in part by JSPS KAKENHI Grant Number 21K16641. We thank Jane Charbonneau, DVM and Angela Morben, DVM, ELS, from Edanz (<https://jp.edanz.com/ac>), for editing a draft of this manuscript.

Disclosure Statement

The authors declare that they have no conflict of interest. No presentation in whole or in part at any meeting occurred regarding the submitted manuscript.

References

1. Lozupone E, Piano M, Valvassori L, et al. (2018). Flow diverter devices in ruptured intracranial aneurysms: A single-center experience. *J Neurosurg*. 128: 1037-1043.
2. Nerva JD, Morton RP, Levitt MR, et al. (2015). Pipeline embolization device as primary treatment for blister aneurysms and iatrogenic pseudoaneurysms of the internal carotid artery. *J Neurointerv Surg*. 7:210-216.
3. Zhang J, Yu M, Lv X (2021). Endovascular treatment of blood blister-like aneurysms of internal carotid artery: Stent-assisted coiling and pipeline flow diversion. *J Clin Neurosci*. 90:8-13.
4. Aihara M, Shimizu T, Naito I, et al. (2021). Endovascular treatment strategy and clinical outcomes for ruptured blood blister-like aneurysms of the internal carotid artery using low-profile visualized intraluminal support stent. *World Neurosurg* 149: e146-e153.
5. Irie K, Negoro M, Hayakawa M, et al. (2003). Stent assisted coil embolization: The treatment of wide-necked, dissecting, and fusiform aneurysms. *Interv Neuroradiol* 9:255-261.
6. Patel PD, Chalouhi N, Atallah E, et al. (2017). Off-label uses of the pipeline embolization device: A review of the literature. *Neurosurg Focus*. 42:E4.
7. Chalouhi N, Zanaty M, Whiting A, et al. (2015). Treatment of ruptured intracranial aneurysms with the pipeline embolization device. *Neurosurgery*. 76:165-172; discussion 172.
8. Kan P, Sweid A, Srivatsan A, et al. (2020). Expanding indications for flow diverters: Ruptured aneurysms, blister aneurysms, and dissecting aneurysms. *Neurosurgery*. 86:S96-S103.

Citation: Suzuki K, Mitome-Mishima Y, Teranishi K, Kondo A, Oishi H (2023) A large ruptured dissecting internal carotid artery aneurysm treated by flow diverter and coil embolization: a case report and literature review. *Int J Cerebrovasc Dis Stroke* 6: 146. DOI: <https://doi.org/10.29011/2688-8734.1000146>

9. Hilditch CA, Brinjikji W, Schaafsma J, et al. (2019). Flow-diverter stents for internal carotid artery reconstruction following spontaneous dissection: A technical report. *Clin Neuroradiol.* 29:707-715.
10. Kulcsár Z, Houdart E, Bonafé A, et al. (2011). Intra-aneurysmal thrombosis as a possible cause of delayed aneurysm rupture after flow-diversion treatment. *AJNR Am J Neuroradiol.* 32:20-25.