



Research Article

Cement Lumbar Interbody Fusion (CLIF) for Low-grade Degenerative Spondylolisthesis with Minimum 10-year Follow-up

Kung-Chia Li*, Ching-Hsiang Hsieh, Ting-Hua Liao

Yang Ming Hospital, Chiayi, Taiwan

*Corresponding author: Kung-Chia Li, Yang Ming Hospital, No. 252 Wu-Fung North Road, Chiayi 60045, Taiwan

Citation: Li KC, Hsieh CH, Liao TH (2022) Cement Lumbar Interbody Fusion (CLIF) for Low-grade Degenerative Spondylolisthesis with Minimum 10-year Follow-up. J Surg 7: 1691. DOI: 10.29011/2575-9760.001691

Received Date: 23 December, 2022; Accepted Date: 27 December, 2022; Published Date: 30 December, 2022

Abstract

Objective: To evaluate the efficacy of mini-open cement lumbar interbody fusion without screws (CLIF) for patients with low-grade Degenerative Lumbar Spondylolisthesis (DLS) with a minimum 10-year follow-up.

Method: Between 2011 and 2012, patients with single - level low-grade DLS were treated with traditional posterior lumbar interbody fusion with cages and bilateral pedicle screws (PLIF, 35 cases, 23 females, 12 males, mean age 62.6 years, mean follow-up 131.2±5.1 months) or CLIF, fixed by interbody cementation and cages without screws (34 cases, 23 females, 11 males, mean age 63.5 years, mean follow-up 129.5±4.5 months) were enrolled. The clinical and radiological outcomes were recorded. The minimum follow-up was 10 years.

Result: There were no significant intergroup differences in demographic and preoperative parameters. There was significantly less blood loss, operative time, and hospitalization in CLIF group. The VAS and ODI in both groups were significantly improved after operation, but there was no significant intergroup difference at sequential follow-ups. The Disc height was similar in the two groups at initial follow-up, but significantly higher in CLIF group at the final visit. There was no significant cage subsidence in CLIF group. The incidence of reoperation due to adjacent segment pathology was higher in PLIF (25.7%) than in CLIF (5.9%) ($p = 0.045$).

Conclusion: CLIF with less blood loss, operative time, and hospitalization led to similar clinical outcomes of PLIF in the long-term follow-up. Additionally, CLIF can reliably maintain the disc height and lessen the reoperation rate due to adjacent segment pathology.

Keywords: Cement lumbar interbody fusion (CLIF); Degenerative spondylolisthesis; Interbody cementation; Manual reduction; Posterior lumbar interbody fusion.

Introduction

When the conservative treatment for degenerative lumbar spondylolisthesis (DLS) is unsuccessful, surgical decompression and fixation may be the next step. Modern surgical methods such as minimally invasive transforaminal lumbar interbody fusion provide additional options to decrease post-operative morbidities compared with traditional open surgery [1-5]. However, one of the biggest obstacles to minimally invasive spinal surgery is how to ensure pedicle screw accuracy. The misplacement rate of minimally invasive pedicle screws reported by Schwender et al. is up to 4.1%

[6,7]. Screw misplacement may lead to not only instability but also neurological, vascular, or visceral injuries. Obviously, the minimally invasive technique necessitates more radiation exposure to the patient and surgeons. Even though Robots can raise precision [8-10] but yet do not exempt from complications despite the fairly high medical cost. Therefore, a reliable and satisfying surgical method to treat DLS without screws is expected.

Stand-alone cages for posterior lumbar interbody fusion had been tried and decreased its popularity due to implant-related complications. With a 20-year follow-up after stand-alone cages, there was 11.1% pseudoarthrosis and a 6.6% re-operation rate [11]. The disc space decreased from 13.3 mm at the initial follow-up to 10.0 mm at the final visit and was weak in improving sagittal balance [11]. The results of adjacent segment degeneration with

stenosis treated with stand-alone posterior expandable cages showed high rates of subsidence (21.05%) and retropulsion (15.79%) [1]. These reports suggest the posterior cage-alone technique is not clinically perfect.

Percutaneous cement discoplasty (PCD) without posterior instrumentation has been developed to improve low back pain [12-16]. In patients with concomitant spinal stenosis, decompression surgery with discoplasty also lead to satisfactory improvement [12]. However, PCD is weak in correcting spinal deformities [12]. Therefore, mini-open Cement Lumbar Interbody Fusion (CLIF) without screws has been developed and applied to treat low-grade degenerative spondylolisthesis (DLS). The specific aim of this study is to evaluate its long-term clinical and radiographic effects.

Materials and Methods

General Information

This retrospective single-institute study was approved by the St Martin De Porres Hospital, Chia-Yi, Taiwan ethics review board

(IRB 20C-006).

Patient Information

A total of 84 patients with single-level DLS were treated between Jan 2011 and Dec 2012. The inclusion criteria were: (1) single-level grade 1 or 2 degenerative DLS; (2) presentation with low back and radicular leg pain for more than 6 months; (3) minimum 10-year follow-up. The exclusion criteria were: (1) revision surgery; (2) tumor; (3) infection; (4) cauda equina syndrome; (5) compression fracture at the index level. During the follow-up interval, 6 patients die of medical diseases and 9 patients lost follow-up; finally, 69 patients (follow-up rate: 82.1%) were enrolled. Thirty-five patients were treated with traditional open posterior lumbar interbody fusion with cages and bilateral pedicle screws (PLIF) and 34 cases with CLIF, fixed with interbody cementation and cages. There was no intergroup difference in the demographic data (Table 1).

	CLIF	PLIF	Statistics ^a
Case and item	34	35	NS
Age at operation	63.5 ± 7.8	62.6 ± 8.2	NS
Female : male	23:11	23:12	NS
BMI	23.5 ± 3.1	23.2 ± 2.9	NS
BMD (T-score)	2.3 ± 0.4	2.1 ± 0.5	NS
Diabetes	12	11	NS
Hypertension	18	17	NS
Mean Follow-up (M)	129.5 ± 4.5	131.2 ± 5.1	NS
VAS pre-op.	7.9 ± 2.1	7.8 ± 2.2	NS
ODI pre-op.	58.8 ± 19.3	56.7 ± 18.2	NS
Operation time (min)	56 ± 17	82 ± 23	P < 0.01
Blood loss (cc)	79 ± 61	150 ± 42	P = 0.01
Hospitalization (D)	2.3 ± 1.0	3.4 ± 1.4	P < 0.01

^aPresented data are mean of the variables with standard deviation and continuous variables were evaluated by student t-test. The categorical variables were performed by Fisher's exact test at P < 0.05. NS: nonsignificant.

Table 1: Generalized background of the patients receiving CLIF or PLIF and respective clinical outcomes.

Operation Techniques of CLIF

The schematic flow chart of CLIF is shown in Figure 1 and also shown by a real case (Figure 2). Under general anesthesia, patients were changed from supine to prone position and C-arm fluoroscopy was used to locate the listhesis site and monitor the cementation. Then all patients received manual reduction first, which was done by five people [17,18]. One anesthesiologist held the patient's head, two assistants held the patient's shoulders, two assistants held the patient's legs, and the surgeon compressed the index level of spine

by two hands. Manual reduction began with gentle traction of the trunk by the leg assistants with greater force at the sciatica side and simultaneously, the surgeon gradually increased the pushing force on the spine to partially recover the lumbar lordosis and listhesis.

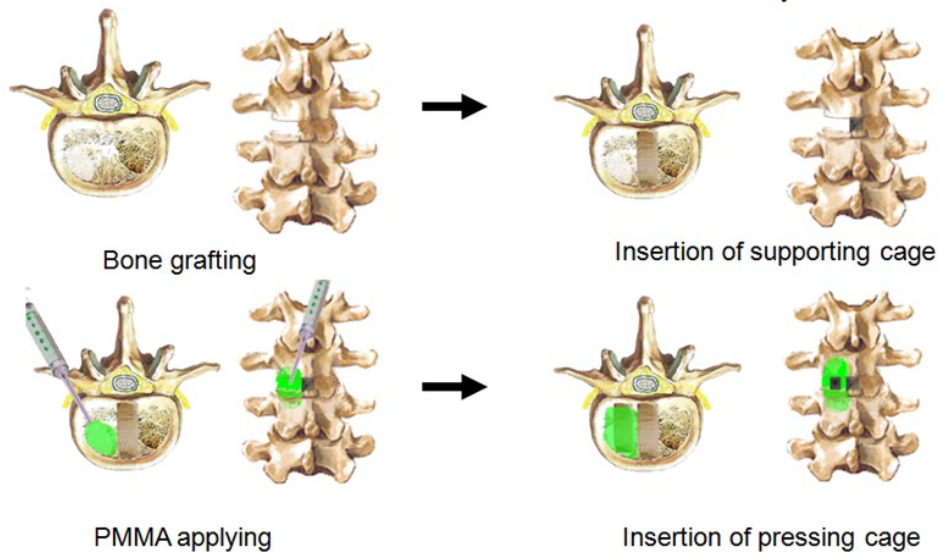


Figure 1: CLIF flow charts as shown in the transverse and anterior-posterior views. The first step is disectomy and bone grafting into the contralateral side; second, insertion of supporting cage pushing to contralateral paramedian location; third, injection of bone cement; fourth, placement of the pressing cage.

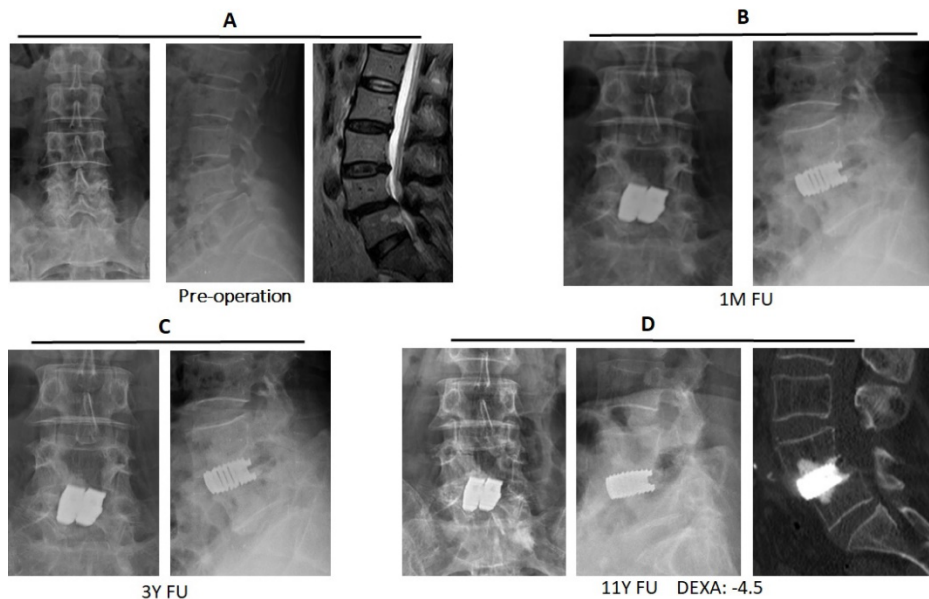


Figure 2: A 72-year-old female with L4/5 DLS and spinal stenosis (A) receiving CLIF; the initial post-operative (B), 3-year (C) and 11-year (D) follow-up.

After manual reduction, a midline incision was made. Then laminectomy and disectomy were followed. Bone graft harvested from lamina chips was applied into the contralateral disc space. One cage was implanted and pushed to the middle part of the disc space, functioning as the supporting cage. Then, one curette of 1-cm scoop was used to create the bony trough at both vertebrae adjacent to the index disc for interbody cementation. The width x length x height of the trough in each vertebra was about 10-15mmx15-

20mmx15-20mm. The tip of a 1 mL or 3 mL decapitated syringe filled with polymethylmethacrylate (cement, Surgical Simplex P, Howmedica Osteonics Corp. NJ, USA) was then injected into the disc space. About 6 - 12 mL of cement in the dough phase was pressed to both vertebral bodies from the disc. Before the cement becomes hardened, a second cage was slot into the disc space, further strengthening the cement-bone digital bonding. The C-arm fluoroscopy was used to check that cement was not leaked out into the spinal canal or neuro-foramen. In contrast to PLIF, CLIF patients need not wear a back brace.

Clinical and Radiological Evaluation

The pain was measured using a visual analog scale (VAS, score range 0 – 10) and function was assessed with the Oswestry Disability Index (ODI, score range 0 – 100) [19]. The clinical adjacent segment pathology was defined as 1) symptomatic spinal stenosis, 2) intractable back pain, or 3) subsequent sagittal or coronal imbalance [6]. All patients underwent preoperative dynamic standing plain radiography and MRI scanning. Radiographs were taken preoperatively, at 1 week, 3 months, 12 months, 5 years, and final visit postoperatively. Radiological measurements were performed by a well-trained graduate student. All digitization and measurements were performed using EBM-viewer software (EBM Technologies Inc., Taipei, Taiwan) with an accuracy of ± 0.1 mm. The assessment was done for observation of the index disc height (DH), cage subsidence (>3 mm), implant or cement stability. The DH was defined by (anterior DH + posterior DH)/2. The significant cage subsidence is defined by more than 3mm cage migration into vertebral body compared with the radiographs at initial follow-up.

Statistical Analysis

Quantitative variables were expressed as mean standard \pm deviation and qualitative variables were expressed in terms of number and ratio. Continuous variables were evaluated by student t - test. The categorical variables were performed by Fisher's exact test. P <0.05 difference was statistically significant. The statistical analysis was performed with Excel (Microsoft, Classic 2021 versions, USA).

Results

Operation Practice

There were significantly less blood loss, operative time, and hospitalization in CLIF group compared with PLIF group (Table 1). The postoperative VAS scores (Figure 3A) and ODI scores (Figure 3B) in both groups were significantly improved compared with preoperative data ($p <0.05$). There was no significant inter-group difference in the VAS and ODI improvement rates (Figure 3). The Disc height was similar in two groups at the first radiographs after operation (CLIF vs PLIF = 12.8 ± 0.8 mm vs 12.7 ± 0.9 mm, $p = 0.47$), but significantly higher in CLIF group than PLIF group at the final visit (12.2 ± 0.8 mm vs 11.0 ± 1.0 mm, $p <0.01$). There were 4 cases in PLIF and no case in CLIF with significant cage subsidence ($p = 0.11$). In the CLIF group, 5 cases with ossification of the anterior longitudinal ligament (Figure 4) and 3 cases with ankylosing bridging spurs (Figure. 5) were noted. There was no symptomatic cement loosening was noted in CLIF.

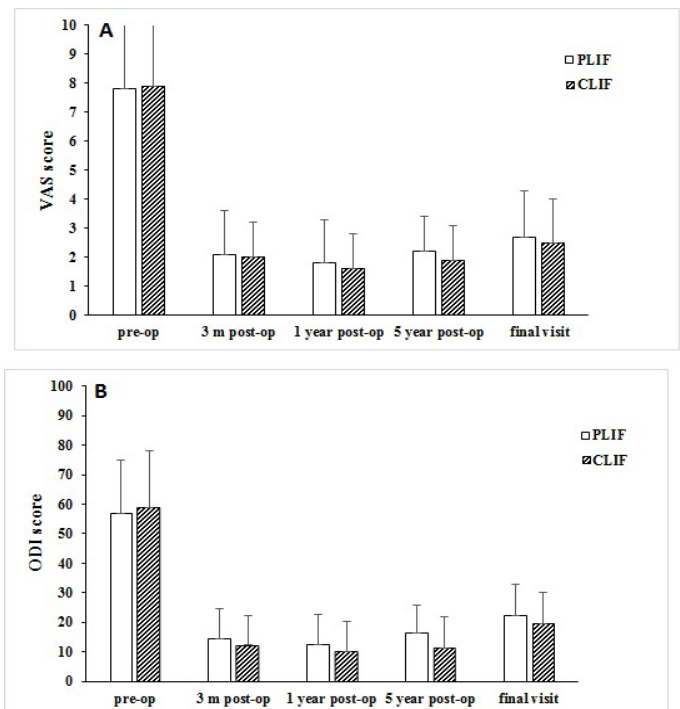


Figure 3: VAS (A) and ODI (B) scores of PLIF and CLIF groups and there was no significant inter-group difference.

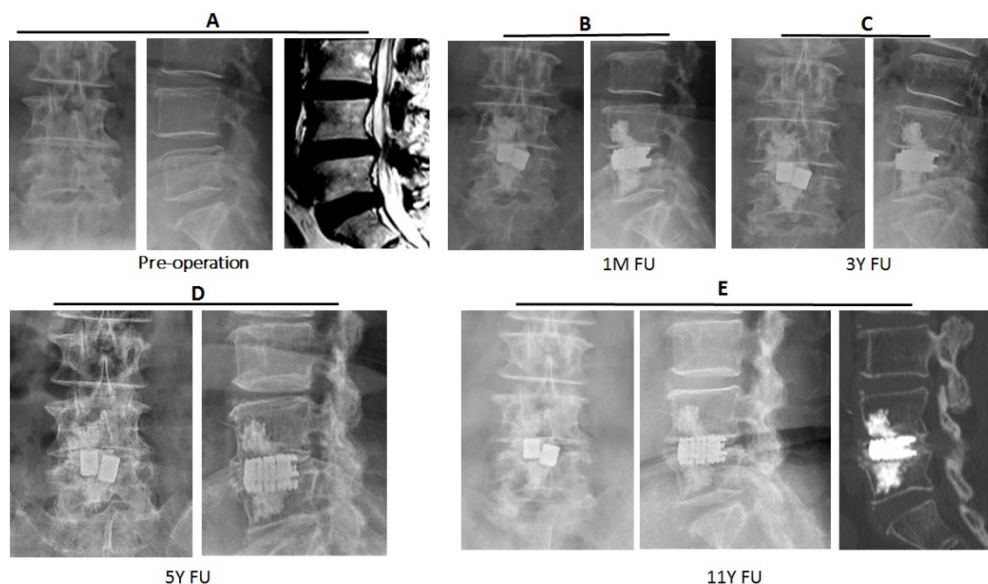


Figure 4: A 71-year-old female with L4/5 DLS and spinal stenosis (A) received CLIF. The radiographs illustrate the initial post-operative (B), 3-year (C), 5-year (D) and 11-year (E) follow-up. The ossification of anterior longitudinal ligament was noted.

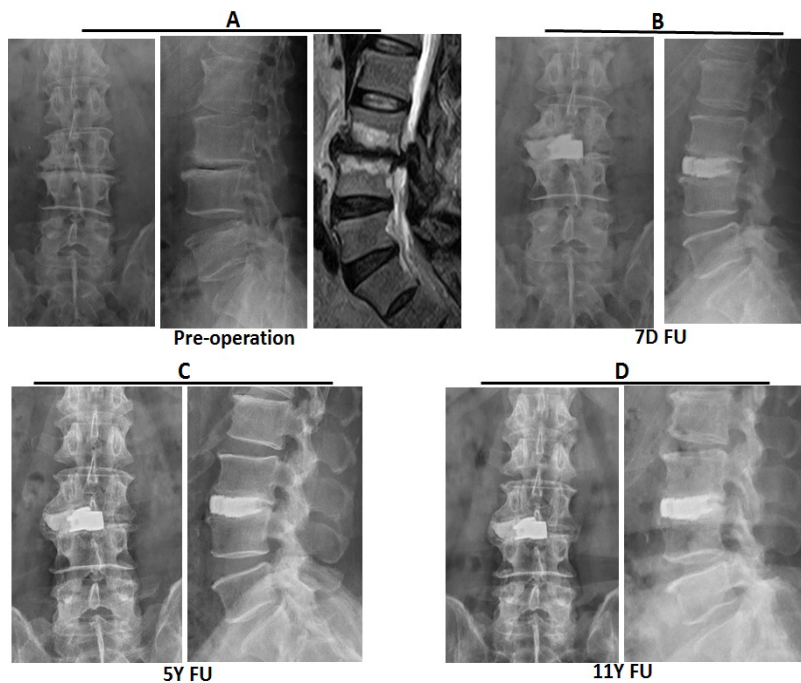


Figure 5: A 63-year-old male with L3/4 retrolisthesis and spinal stenosis (A) received CLIF. The radiographs document the initial post-operative (B), 3-year (C) and 11-year (D) follow-up. The ankylosing bridging spurs were noted.

Complications

In PLIF group, surgical complications included one deep vein thromboses, one superficial infection and one dura tear. All patients were treated by medical conservative treatment. There was one poor fusion (2.8%), who received revision surgery. In CLIF group,

surgical complications included two non-significant cement leakage through anterior disc defect into para-spinal space (Figures 6 and 7), one transient leg weakness due to L5 root overstretch, and one deep vein thrombosis. There was one symptomatic instability of the cage-cement complex after a motorcycle accident, who received posterior instrumentation. (Figure 8). During the long-term follow-up, clinical adjacent segment pathology developed in 13 PLIF and 6 CLIF patients ($p = 0.11$). Spinal stenosis symptoms were the most common clinical manifestations of clinical adjacent segment pathology. Most patients were treated with conservative modalities first. At the final visit, there were 9 of PLIF cases (25.7%) and 2 of CLIF cases (5.9%) subjecting to revision surgery due to adjacent segment pathology ($p = 0.045$).

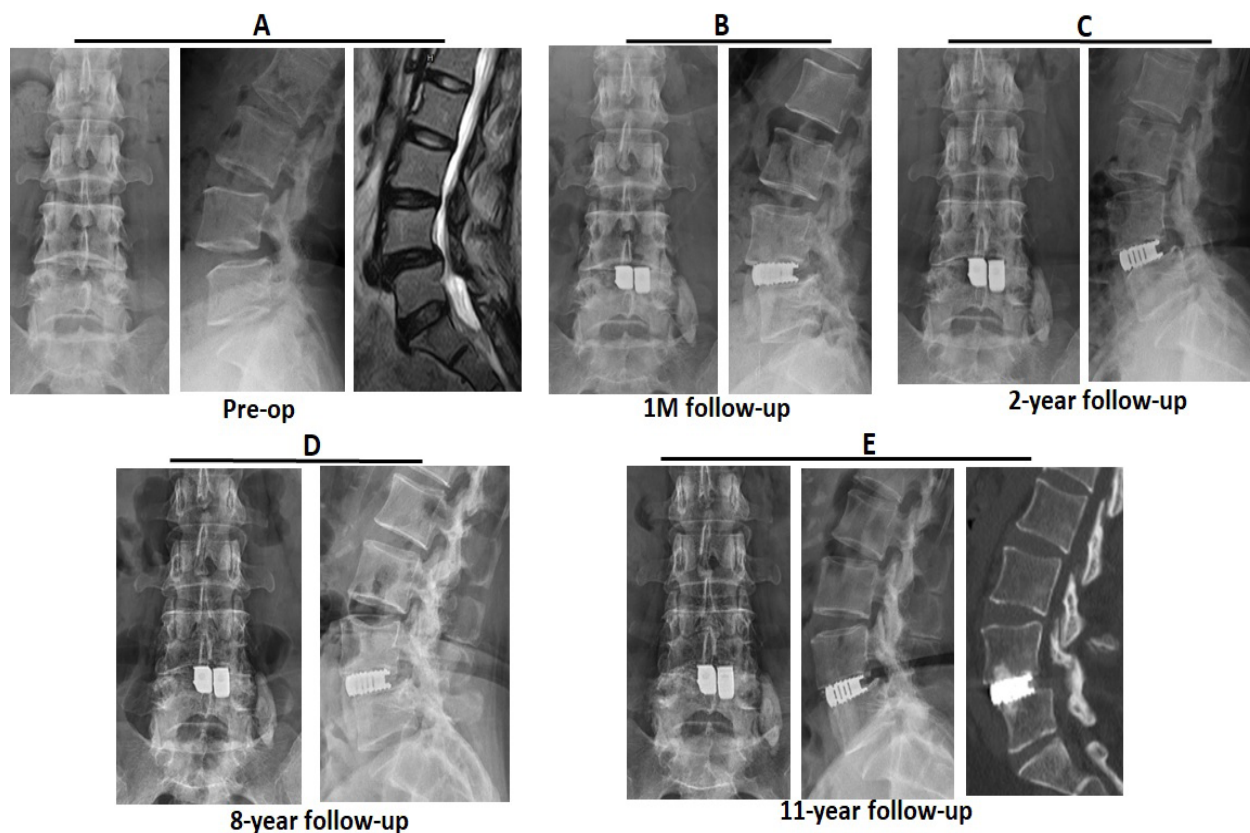


Figure 6: A 53-year-old female with L4/5 DLS and spinal stenosis (A) received CLIF with asymptomatic cement leakage into paraspinal space. The radiographs demonstrate the initial post-operative (B), 2-year (C), 8-year (D) and 11-year (E) follow-up.

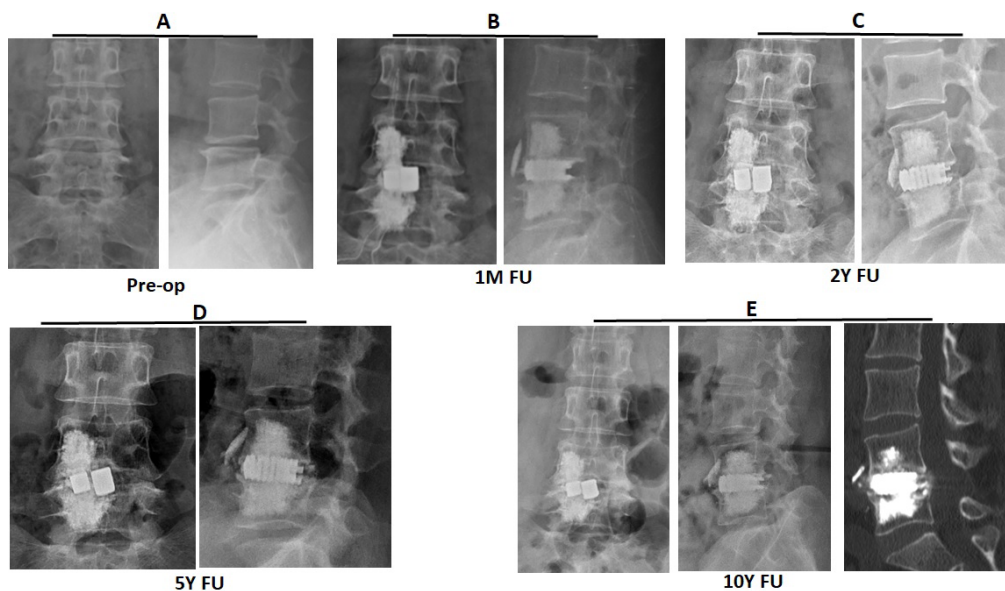


Figure 7: A 60-year-old female with L4/5 listhesis and spinal stenosis (A) received CLIF with asymptomatic cement leakage via L4 anterior cortex defect. The radiographs reveal the initial post-operative (B), 2-year (C), 8-year (D) and 10-year (E) follow-up.

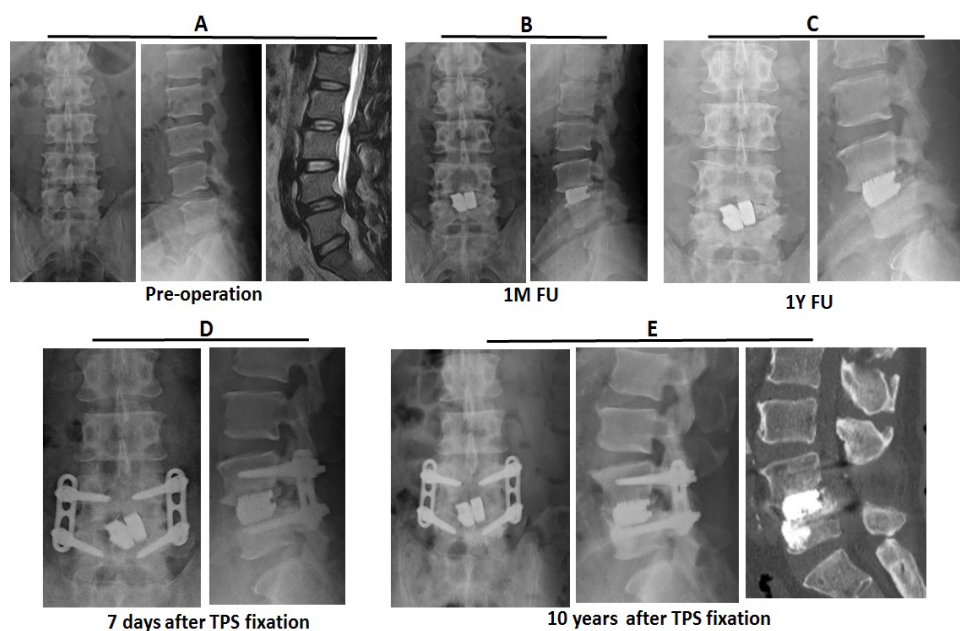


Figure 8: A 54-year-old male with L4/5 DLS and spinal stenosis (A) received CLIF (B). The cement-loosening with instability of cage-cement complex (C) was noted after a severe traffic accident. He received posterior instrumentation one year post-operatively. The radiographs showed 7-days (D) and 10-year (E) follow-up after trans-pedicle screw fixation.

Discussion

Surgical decompression and screw fixation are the standard operations when treating symptomatic DLS. But even with modern technology, the severe misplacement rate of the minimally invasive pedicle screws is up to 4.1% [7]. The Robots can increase accuracy [18,20,21], but yet do not exempt from complications in spite of the high medical cost. Stand-alone cage had been tried and lost its popularity owing to implant-related complications and pseudoarthrosis [1,11]. Percutaneous cement discoplasty (PCD) was used to treat low back pain [12-16], but weak to correct the spinal deformity [12]. Therefore, the mini-open CLIF without screws has been developed and applied to treat DLS. The long-term clinical and radiological results showed that CLIF can subside the symptoms as PLIF, and further prevent cage subsidence, decrease the re-operation rate due to clinical adjacent segment pathology, and avoid screw-related problems and cost.

No clinically significant cement leakage was noted in our series. In the present study, there were only two cement leakages through the anterior annular fibrosa or cortical defect into paraspinal space. Learning from cement vertebroplasty, the risk factors of cement extravasation included injection pressure, fracture characteristics, and the viscosity of the cement [22,23]. In 2017, Tsai et al. [24] classified the leaks of cement into three types: via the basivertebral vein, via the segmental vein, and through a cortical defect [21,25-28]. Our leakage mechanism is similar to the cortical defect; no leakage is via the basivertebral or segmental vein. By our method, the cement in the late dough phase of higher viscosity is injected into vertebral bone trough-disc space with lower resistance compared with higher pressure cement in the liquid or softer dough phase of less viscosity for the percutaneous vertebroplasty. Because the key factor of leakage is low cement viscosity while injecting [20,29], which was avoided in our method and thus there was no major complication caused by intra-disc injection for interbody cementation in this study.

After interbody bone fusion is achieved, interbody cement will be theoretically less stressed and may hopefully long survive. Total hip arthroplasty using the interface bioactive bone cement can last more than 30 years [30]. The 15-year accumulated revision rate for the primary cemented total knee was less than 7% and “cement disease” has been discarded [31]. Learning from the experiences of cemented joint replacement, the long-term cement fixation should not be a problem especially when the interbody fusion will be expectedly achieved and interbody cement is less strained. That’s why no symptomatic cement loosening was noted. The cage subsidence is affected by several factors [32], but cemented cage is nowhere to go whenever the cement fixation is well maintained. That may be the reason there was no significant cage subsidence after interbody cementation in CLIF.

Adjacent segment disease is a result of multi-factorial interaction, but mainly due to hypermobility of adjacent segment following spinal fusion [33-35]. The rate of adjacent segment disease was higher in patients with transpedicular instrumentation compared with patients fused with other forms of instrumentation or without instrumentation (5.2 - 5.6%) [34]. Anterior approach with cage alone or with anterior plating preserved more motion at the index segment compared with bilateral pedicle screw fixation [36]. The CLIF, as in anterior interbody fusion, also left the facet joints unfixed, which theoretically allowed the facet joint motion in some range. That may be the reason why the reoperation rate due to adjacent segment pathology is decreased in CLIF. The interbody cementation can well fix the motion segment from immediately after surgery to the final visit; therefore, it is not necessary to worry the problem of poor-fusion and implant failure. Based on this study, the long-term clinical outcomes of CLIF are not second to PLIF. The cage subsidence and reoperation rate of CLIF is even superior to the PLIF. In addition, cement is much cheaper than the screw system. Therefore, CLIF may be considered an alternative option in some situations e.g. severe osteoporosis not good for screw fixation, adjacent segment disease to avoid removal of previous screws, fragile medical condition, or dementia with poor compliance in wearing a brace.

Some limitations should be considered when interpreting our report. First, the retrospective design might lead to selection bias and the single-institute study with small sample size might reduce the strength of our data. Second, the clinical outcomes were determined by the surgeons treating the patients, which could introduce bias in the interpretation of findings. Further prospective, long-term studies involving multi-center with a large sample size are required to confirm our findings.

Conclusion

In conclusion, this study showed that CLIF and PLIF both have similar long-term clinical outcomes. CLIF has the additional benefits of less operation time, less blood loss, less hospitalization, better disc height preservation, and less revision surgery due to adjacent segment pathology.

References

1. Choi W-J, Kim S-K, Alaraj M (2021) Stand-alone posterior expandable cage technique for adjacent segment degeneration with lumbar spinal canal stenosis: A retrospective case series. *Medicina* 57: 237.
2. Du X, She Y, Ou Y (2021) Oblique lateral interbody fusion versus transforaminal lumbar interbody fusion in degenerative lumbar spondylolisthesis: a single-center retrospective comparative study. *BioMed research international* 2021: 6693446.
3. Jain D, Ray WZ, Vaccaro AR (2020) Advances in techniques and technology in minimally invasive lumbar interbody spinal fusion. *JBJS reviews* 8: e0171.

4. Kim CH, Easley K, Lee J-S (2020) Comparison of minimally invasive versus open transforaminal interbody lumbar fusion. *Global Spine Journal* 10: 143S-150S.
5. Xu DS, Walker CT, Godzik J (2018) Minimally invasive anterior, lateral, and oblique lumbar interbody fusion: a literature review. *Annals of translational medicine* 6: 104.
6. Cheh G, Bridwell KH, Lenke LG (2007) Adjacent segment disease following lumbar/thoracolumbar fusion with pedicle screw instrumentation: a minimum 5-year follow-up. *Spine* 32: 2253-2257.
7. Schwender JD, Holly LT, Rouben DP (2005) Minimally invasive transforaminal lumbar interbody fusion (TLIF): technical feasibility and initial results. *Clinical Spine Surgery* 18: S1-S6.
8. Han X, Tian W, Liu Y (2019) Safety and accuracy of robot-assisted versus fluoroscopy-assisted pedicle screw insertion in thoracolumbar spinal surgery: a prospective randomized controlled trial. *Journal of Neurosurgery: Spine* 30: 615-622.
9. Staub BN, Sadrameli SS (2019) The use of robotics in minimally invasive spine surgery. *Journal of Spine Surgery* 5: S31.
10. Zhang Q, Han X-G, Xu Y-F (2020) Robotic navigation during spine surgery. *Expert review of medical devices* 17: 27-32.
11. Baeesa SS, Medrano BG, Noriega DC (2016) Long-term outcomes of posterior lumbar interbody fusion using stand-alone ray threaded cage for degenerative disk disease: a 20-year follow-up. *Asian Spine Journal* 10: 1100.
12. Camino-Willhuber G, Norotte G, Bronsard N (2021) Percutaneous cement discoplasty for degenerative low back pain with vacuum phenomenon: a multicentric study with a minimum of 2 years of follow-up. *World Neurosurgery* 155: e210-e217.
13. Camino Willhuber G, Kido G, Pereira Duarte M (2020) Percutaneous cement discoplasty for the treatment of advanced degenerative disc conditions: a case series analysis. *Global Spine Journal* 10: 729-734.
14. Kiss L, Varga PP, Szoverfi Z (2019) Indirect foraminal decompression and improvement in the lumbar alignment after percutaneous cement discoplasty. *European Spine Journal* 28: 1441-1447.
15. Sola C, Camino Willhuber G, Kido G (2021) Percutaneous cement discoplasty for the treatment of advanced degenerative disk disease in elderly patients. *European Spine Journal* 30: 2200-2208.
16. Yamada K, Nakamae T, Nakanishi K (2021) Long-term outcome of targeted therapy for low back pain in elderly degenerative lumbar scoliosis. *European Spine Journal* 30: 2020-2032.
17. Li K-C, Li AF-Y, Hsieh C-H (2007) Transpedicle body augments in painful osteoporotic compression fractures. *European Spine Journal* 16: 589-598.
18. Li K-C, Yu S-W, Li A (2014) Subpedicle decompression and vertebral reconstruction for thoracolumbar Magerl incomplete burst fractures via a minimally invasive method. *Spine* 39: 433-442.
19. Fairbank JC, Pynsent PB (2000) The Oswestry disability index. *Spine* 25: 2940-2953.
20. Loeffel M, Ferguson SJ, Nolte L-P (2008) Vertebroplasty: experimental characterization of polymethylmethacrylate bone cement spreading as a function of viscosity, bone porosity, and flow rate. *Spine* 33: 1352-1359.
21. Nieuwenhuijse MJ, Van Erkel AR, Dijkstra PS (2011) Cement leakage in percutaneous vertebroplasty for osteoporotic vertebral compression fractures: identification of risk factors. *The Spine Journal* 11: 839-848.
22. Li K-C, Hsieh C-H, Liao T-H (2022) A novel classification of cement distribution patterns based on plain radiographs associated with cement filling rate and relevance to the clinical results of unipedicle vertebroplasty. *European Spine Journal* 2022: 1-9.
23. Zhan Y, Jiang J, Liao H (2017) Risk factors for cement leakage after vertebroplasty or kyphoplasty: a meta-analysis of published evidence. *World neurosurgery* 101: 633-642.
24. Tsai P-J, Hsieh M-K, Fan K-F (2017) Is additional balloon Kyphoplasty safe and effective for acute thoracolumbar burst fracture? *BMC Musculoskeletal Disorders* 18: 1-9.
25. Ding J, Zhang Q, Zhu J (2016) Risk factors for predicting cement leakage following percutaneous vertebroplasty for osteoporotic vertebral compression fractures. *European Spine Journal* 25: 3411-3417.
26. Hong S-J, Lee S, Yoon JS (2014) Analysis of intradiscal cement leakage during percutaneous vertebroplasty: multivariate study of risk factors emphasizing preoperative MR findings. *Journal of Neuroradiology* 41: 195-201.
27. Tomé-Bermejo F, Piñera AR, Duran-Álvarez C, et al. (2014) Identification of risk factors for the occurrence of cement leakage during percutaneous vertebroplasty for painful osteoporotic or malignant vertebral fracture. *Spine* 39: E693-E700.
28. Zhang K, She J, Zhu Y (2021) Risk factors of postoperative bone cement leakage on osteoporotic vertebral compression fracture: a retrospective study. *Journal of Orthopaedic Surgery and Research* 2021; 16: 1-7.
29. Gisep A, Boger A (2009) Injection biomechanics of in vitro simulated vertebroplasty—correlation of injection force and cement viscosity. *Bio-medical materials and engineering* 19: 415-420.
30. Oonishi H, Ohashi H, Kawahara I (2016) Total hip arthroplasty around the inception of the interface bioactive bone cement technique. *Clinics in Orthopaedic Surgery* 8: 237-242.
31. Vertullo CJ, Graves SE, Peng Y, et al. (2018) The effect of surgeon's preference for hybrid or cemented fixation on the long-term survivorship of total knee replacement: An analysis of 39,623 prostheses from the Australian Orthopaedic Association National Joint Replacement Registry. *Acta orthopaedica* 89: 329-335.
32. Oh KW, Lee JH, Lee J-H (2017) The correlation between cage subsidence, bone mineral density, and clinical results in posterior lumbar interbody fusion. *Clinical spine surgery* 30: E683-E689.
33. Etebar S, Cahill DW (1999) Risk factors for adjacent-segment failure following lumbar fixation with rigid instrumentation for degenerative instability. *Journal of Neurosurgery: Spine* 90: 163-169.
34. Park P, Garton HJ, Gala VC (2004) Adjacent segment disease after lumbar or lumbosacral fusion: review of the literature. *Spine* 29: 1938-1944.
35. Toivonen LA, Mäntymäki H, Häkkinen A (2022) Postoperative Sagittal Balance Has Only a Limited Role in the Development of Adjacent Segment Disease After Lumbar Spine Fusion for Degenerative Lumbar Spine Disorders: A Subanalysis of the 10-year Follow-up Study. *Spine* 47: 1357-1361.
36. Shen H, Chen Y, Liao Z (2021) Biomechanical evaluation of anterior lumbar interbody fusion with various fixation options: Finite element analysis of static and vibration conditions. *Clinical Biomechanics* 84: 105339.