

**Case Report**

# Downstaging of ALK Rearranged Inflammatory Myofibroblastic Tumor of the Lung Using Alectinib Before Surgery: Case Report

**Iosè Di Stefano<sup>1</sup>, Iacopo Petrini<sup>2</sup>, Federica Pezzuto<sup>3</sup>, Elisabetta Macerola<sup>4</sup>, Olivia Fanucchi<sup>5</sup>, Giorgio Cannone<sup>3</sup>, Fiorella Calabrese<sup>3</sup>, Greta Ali<sup>1\*</sup>**

<sup>1</sup>Department of Surgical, Medical and Molecular Pathology and Critical Care Medicine, University of Pisa, Pisa, Italy

<sup>2</sup>Department of Translational Research and New Surgical and Medical Technologies, University of Pisa, Pisa, Italy

<sup>3</sup>Department of Cardiac, Thoracic, Vascular Sciences, and Public Health, University of Padova, Padova, Italy

<sup>4</sup>Unit of Pathological Anatomy, University Hospital of Pisa, Pisa, Italy

<sup>5</sup>Thoracic Endoscopy Unit, Thoracic and Vascular Department, University Hospital of Pisa, Pisa, Italy.

\***Corresponding author:** Greta Ali, Department of Surgical, Medical and Molecular Pathology and Critical Care Medicine, University of Pisa, Pisa, Italy

**Citation:** Di Stefano I, Petrini I, Pezzuto F, Macerola E, Fanucchi O, et al (2024) Downstaging of ALK Rearranged Inflammatory Myofibroblastic Tumor of the Lung Using Alectinib Before Surgery: Case Report. Ann Case Report 9: 1779. DOI: 10.29011/2574-7754.101779

**Received:** 22 April 2024; **Accepted:** 26 April 2024; **Published:** 29 April 2024

## Abstract

Tracheobronchial inflammatory myofibroblastic tumor (IMT) is a rare neoplasm with a pediatric prevalence. Due to its early symptoms and limited size at diagnosis, the treatment of choice is generally surgical with eventual airway reconstruction. We present the case of an 18-year-old patient with ALK-positive IMT involving left lung hilum and infiltrating the left upper lobe. The clinical, radiological, and histopathological findings are described, highlighting the diagnostic challenges of cytological samples. After surgical evaluation, to minimize the extent of resection, given the patient's young age, an approach with alectinib was attempted with a rapid favorable response and no significant side effects. Upon achieving maximum response, a subsequent segmentectomy of the left upper lobe was performed, ensuring complete excision of the lesion. This case underlines the significance of accurate diagnosis and the effectiveness of preoperative therapy with alectinib in ALK-positive IMT for parenchyma-sparing surgery.

**Keywords:** Downstaging; Inflammatory Myofibroblastic Tumor; ALK rearrangement; Alectinib

## Introduction

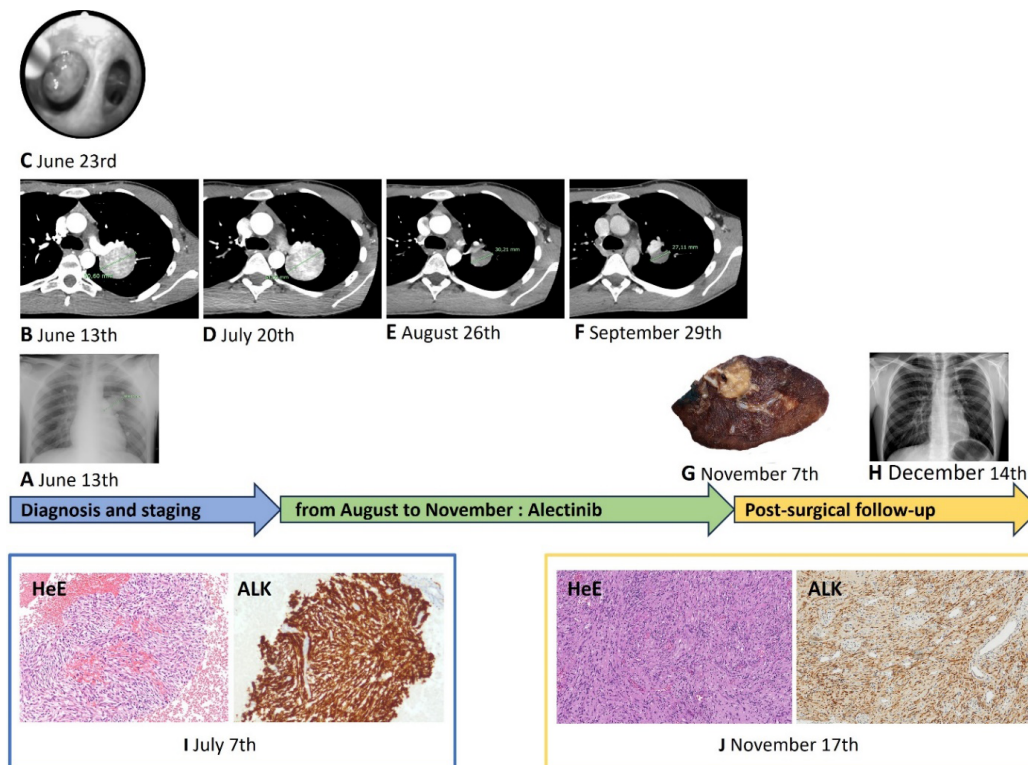
Lung Inflammatory Myofibroblastic Tumors (IMTs) are rare mesenchymal neoplasms, accounting for 0.04–1% of tumors in this site [1]. Especially in the tracheobronchial tract they often

represent a therapeutic challenge, being uncommon and observed in young patients [1]. Half of IMTs harbor ALK rearrangement and can benefit of tyrosine kinase inhibitors (TKI). Surgery is the mainstay of treatment for resectable IMTs whereas radiotherapy and systemic therapies remain options for unresectable cases [2-3]. Here, we report the case of a lung IMT with ALK rearrangement that was treated with alectinib before surgery.

## Case Presentation

In July 2023, an 18-year-old male with spontaneous pneumothorax underwent a computed tomography (CT). The images revealed a 5 cm para-hilar mass of the left upper lobe, adherent to the left pulmonary artery and infiltrating bronchial structures with endoluminal growth (Figure 1A-B). The patient never smoked and had no familiar history of cancer neither comorbidity. The bronchial endoscopy confirmed the endoluminal growth in the left apico-posterior segmental bronchus (Figure 1C). A fine needle aspiration for cytological smears and a paraffin-embedded cell block was performed. Hematoxylin and eosin sections revealed a background of red blood cells, inflammatory cells, and fragments of mesenchymal tissue (Figure 1I). The neoplastic proliferation showed compact fascicular spindle cell growth with a poor myxoid stroma, no evident cytological atypia or mitosis. Neoplastic cells exhibited diffuse cytoplasmic staining for Vimentin and ALK (Figure 1I; monoclonal D5F3, Ventana/Roche, Tuscon, AZ, USA), weak and diffuse expression of SMA, and negativity for desmin, ERG, S100, SOX10, CD34, STAT6, PanCK, TTF-1, NTRK, CD56, and Chromogranin. Mitoses were

not observed, and the proliferation index was 1% according to Mib-1. Next-Generation Sequencing performed using the Myriapod® NGS Cancer panel RNA version 2022/02 from Diatech Pharmacogenetics, revealed a EML4::ALK fusion transcript with a breakpoint between exon 2 of the EML4 gene and exon 20 of the ALK gene. To minimize the extent of resection and preserve as much parenchyma as possible, given the patient's young age, an attempt was made to downsize the tumor before surgery using a TKI. In August 2023, the patient started alectinib at 1200mg daily dosage obtaining a partial response after 4 weeks of treatment (Figure D-E; from 51x35mm to 31x27mm), further confirmed after 4 additional weeks (Figure 1F). Adverse events have been not described. In November 2023, the patient underwent the resection of culmen of the left lung (Figure 1G) with sampling of 6 lymph nodes in the 10L, 11L, 5, 7 and 9 stations. Histopathological analysis confirmed the previous diagnosis and the absence of nodal involvement. The tumor displayed 70% neoplastic residue with sclerohyaline stroma, along with several histiocytes and foamy macrophages in the inflammatory component (Figure 1J).



**Figure 1:** Clinicopathological timeline. Diagnostic assessments: radiography (A), computed tomography (B) and endoscopy (C) with needle aspiration and subsequent cell block (I; 100x magnification). Computed tomography scans at baseline (D) and during treatment with alectinib (E-F). Surgical specimen (G), histology and immunohistochemistry (J; 100x magnification) of inflammatory myofibroblastic tumor. Post-surgical radiography (H). HeE: Hematoxylin and eosin.

## Discussion

IMT is a rare mesenchymal neoplasm with intermediate malignant potential. Recurrences occur in about 20% of cases and metastatic spread has been only occasionally observed [1]. The rarity of these tumors, coupled with different clinical presentations and histopathological variants increase the risk of misdiagnosis or delayed diagnosis. The definitive diagnosis is one of exclusion, upon the histopathological examination. The identification of IMT is even more challenging using cytological samples [4]. In our cytological smears, neoplastic cells were scarce, lacking many features of the three recognized IMT histological patterns [1]. Cell block can increase the chances of diagnosis and immunohistochemistry is necessary to establish the myofibroblastic nature of the neoplasm with the exclusion of other spindle cell lung neoplasms including solitary fibrous tumor, congenital peribronchial myofibroblastic tumor, sarcomas, and carcinomas [3-4]. ALK rearrangement identification, combined with cell morphology, absence of mitosis, and positivity only for Vimentin and SMA, support a conclusive diagnosis [1].

Only a complete surgical resection gives the chance of a curative treatment [2]. Non-surgical options can include radiotherapy, chemotherapy, and corticosteroids, but there are no large cohort studies supporting these treatments [3]. Advances in molecular profiling of IMT have revealed ALK gene rearrangements in more than 50% of cases, with a predilection for the young population [5]. In this context, the use of ALK inhibitors has shown efficacy in anecdotal case reports. Recently, Wang and colleagues reviewed the results of TKIs for the treatment of IMT with ALK rearrangement. In 2022, US Food and Drug Administration approved crizotinib for the treatment of inoperable IMT upon results of a phase II trial evaluating 14 pediatric patients that has shown an objective response rate of 86%. Alectinib and ceritinib, second-generation TKIs, are mainly administered as the second and third line after crizotinib in small case series and case reports (compassionate use or enrolment in studies). For both TKIs, more than 50% of patients achieved a partial response (8/15 for alectinib and 9/16 for ceritinib) and more than 20% achieved a complete response (3/15 for alectinib and 4/16 for ceritinib). Data on the use of brigatinib and lorlatinib are limited. The former is reported in only one patient achieving a significant partial response with more than 50% reduction of lesions. Lorlatinib, on the other hand, is used in five patients, all in the fourth line after three other TKIs. The downstaging of locally advanced IMT using TKIs before surgery has been occasionally reported [5]. Two pediatric patients with bladder IMT have been treated with ceritinib and alectinib respectively. Both achieved a partial response that allowed a complete surgical resection. In our case, alectinib has been chosen because of the favorable toxicity profile and the high chance of

response. The tumor regression obtained allowed a complete surgical resection with the spare of a substantial amount of lung parenchyma.

## Conclusion

Our experience remarks the importance of fully characterizing IMTs through immunohistochemical and molecular analyses. Additionally, it suggests considering the use of TKI in patients with locally advanced IMT prior to pursuing complete surgical resection, aiming to spare as much parenchyma as possible.

## Clinical Practice Points

- Tracheobronchial inflammatory myofibroblastic tumors (IMTs) are rare, predominantly affecting pediatric patients, often associated with ALK rearrangement. They pose both diagnostic and therapeutic challenges as the histological diagnosis is one of exclusion and there are no established guidelines for managing advanced disease.
- When a cytological specimen suggests IMT, it is advisable to test for ALK rearrangement to confirm the diagnosis and assess potential therapeutic options.
- While curative surgery remains the preferred treatment modality, it may not be optimal for locally advanced disease in consideration of the patients' young age. Pre-surgical administration of tyrosine kinase inhibitors (TKIs) facilitates complete tumor resection while preserving lung parenchyma to a greater extent.

**Acknowledgments:** This research did not receive any specific grant from funding agencies in the public, commercial, or not-for-profit sectors.

**Declarations of Interest:** none.

## References

1. Sauter JBR, Dacic S, Gill RR (2021) In Thoracic Tumours, 5th ed.; Board, T.W.C.o.T.E., Ed.; International Agency for Research on Cancer (IARC): Lyon, France 5: 204-219.
2. Dong J, Gonzalez-Rivas D, Lv P, Wang Z, He J, et al. (2022) Limited airway resection and reconstruction for paediatric tracheobronchial inflammatory myofibroblastic tumour. *Interact Cardiovasc Thorac Surg.* 35(3): ivac117.
3. Gros L, Dei Tos AP, Jones RL, Digkila A (2022) Inflammatory Myofibroblastic Tumour: State of the Art. *Cancers (Basel)* 14(15):3662.
4. Grosse A, Grosse C (2020) Unexpected finding of inflammatory myofibroblastic tumour in two cytological specimens. *Cytopathology* 31(4):333-337.
5. Wang QA, Chen HW, Wu RC, Wu CE (2023) Update of Diagnosis and Targeted Therapy for ALK+ Inflammation Myofibroblastic Tumor. *Curr Treat Options Oncol* 24(12):1683-1702.