



Case Series

# Evaluation of the Management of Hypospadias at Albert Royer Children's Hospital in Dakar

NDOYE Ndèye Aby<sup>1\*</sup>, SANGARE Mory<sup>2</sup>, GUEYE Doudou<sup>2</sup>, ZENG Florent<sup>2</sup>, WELLE Ibrahima Bocar<sup>2</sup>, MBAYE Papa Alassane<sup>1</sup>, TRAORE Mamadou Mour<sup>1</sup>, CISSE Lissoune<sup>2</sup>, SAGNA Aloise<sup>1</sup>, NGOM Gabriel<sup>1</sup>

<sup>1</sup>Department of Pediatric Surgery, Albert Royer children's hospital, University Cheikh Anta DIOP, Dakar, Senegal

<sup>2</sup>Department of Anesthesia pediatric, Albert Royer children's hospital, University Cheikh Anta DIOP, Dakar, Senegal

**\*Corresponding author:** Ndèye Aby NDOYE, Department of pediatric Surgery, Albert Royer children's hospital, University Cheikh Anta DIOP, Dakar, Senegal

**Citation:** NDOYE NA, Mory S, Doudou G, Florent Z, Ibrahima B W, et al. (2023) Evaluation of the Management of Hypospadias at Albert Royer Children's Hospital in Dakar. J Surg 8: 1821 DOI: 10.29011/2575-9760.001821

**Received Date:** 30 May, 2023; **Accepted Date:** 02 June, 2023; **Published Date:** 05 June, 2023

## Abstract

**Purpose:** To describe the management of hypospadias and to evaluate its results in our practice.

**Methods:** We carried out a retrospective, descriptive study during the period from April 1<sup>st</sup> 2016 to March 31<sup>st</sup>, 2021. Were included, all the children who had a urethroplasty for hypospadias. There were 58 files. We studied the epidemiological aspects, the surgical techniques as well as the short-, mid- and long-term complications.

**Results:** The hypospadias was anterior in 28 cases (48.28%), mid in 18 cases (31.03%), and posterior in 12 cases (20.69%). The mean age of our patients at the time of surgery was 3 years, ranging from 14 months to 8 years.

The surgical techniques of Duplay (36%), Onlay (13.8%) and Mathieu (17%) were the most used. A two-stage surgery was performed in 3 patients. In all our patients, a trans-urethral stent catheter was placed. The mean duration of urine drainage was 4 days with extremes of 2 days and 10 days. Revision surgery was necessary in 26 patients, i.e. 54.16%. After a mean follow-up of 10 months, 27% of patients presented a complication, half of which was a urethro-cutaneous fistula. The results were considered good in 59% of cases.

**Conclusion:** The results of hypospadias treatment have improved in recent years despite still significant morbidity.

**Keywords:** Children’s, Evolution; Hypospadias; Morbidity; Surgery

## Introduction

Hypospadias is defined as a congenital anomaly of the penis where the urethral meatus opens ectopically on the ventral side of the penis. Associated with this ectopic urethral meatus, a ventral curvature of the penis and an anomaly of the preputial skin can be found [1]. The position of the meatus on the ventral side of the penis defines the type of hypospadias encountered. The prevalence of hypospadias would be approximately 1 in 300 male births,

and 1 in 80 to 1 in 100 in families where there is already a child diagnosed with the anomaly [2]. The surgical techniques available can be synthesized into 4 large groups depending on the urethroplasty: urethral advancement techniques (MAGPI, Koff), urethral plate tubulization techniques (Thiersch, Duplay), vascularized flap techniques (Mathieu, Onlay, Duckett) and finally techniques using free flap grafts (buccal, bladder or skin mucosa). Our study aimed to evaluate the results of management of hypospadias in the pediatric surgery department of the Albert Royer National Children’s Hospital Center (ARNCHC).

## Patients and Methods

This is a monocentric descriptive, retrospective study over a period of 5 years, from April 1<sup>st</sup>, 2016 to March 31<sup>st</sup>, 2021 at the pediatric surgery department of the Albert Royer National Children’s Hospital Center in Dakar. Were included all the children received for hypospadias and who had a urethroplasty, and a postoperative follow-up with a minimum follow-up of one year. The studied parameters were anatomical type, age at the time of surgery, type of instruments used, surgical techniques, type and duration of drainage, complications with respect to anatomical type and surgical technique and evaluation of long-term therapeutic results.

## Results

There were 58 files. The hypospadias was anterior in 28 cases (48.28%), mid in 18 cases (31.03%), and posterior in 12 cases (20.69%). The mean age of our patients at the time of surgery was 3 years with extremes of 14 months and 8 years. Thirty-six children (62%) were at least 4 years old at the time of surgery. The use of adapted instruments (magnifying glass and microsurgical

instruments) was effective in 31 of our patients, ie 53.44%. The surgical techniques of Duplay (36%), Onlay (17%) and Mathieu (13.8%) were the most used. A two-stage surgery was performed in 3 patients. The surgical techniques used are shown in Table 1.

Surgical technique	Number	Percentage (%)
Bracka	8	13.79
Duplay	21	36.2
Koff	5	8.62
Koyanagi	3	5.17
MAGPI	1	1.72
Mathieu	8	13.79
Onlay	10	17.24
Snodgrass Artifice	2	3.44
Total	58	100

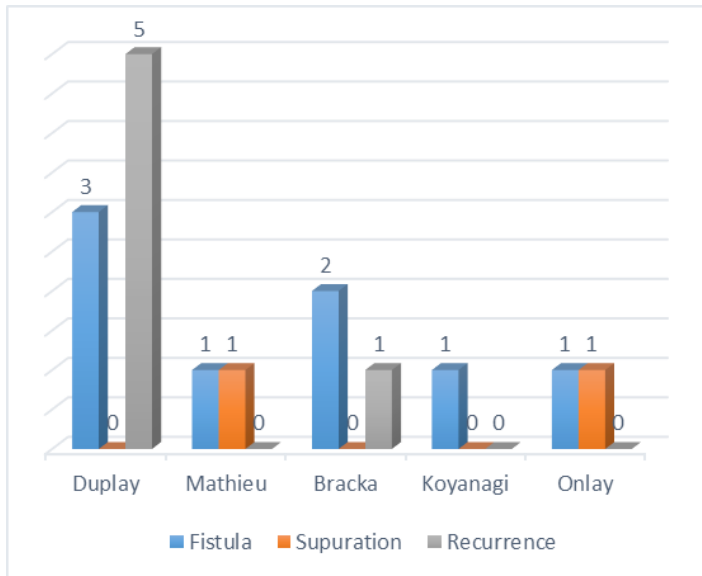
**Table 1:** Distribution according to the used surgical technique.

In all our patients, a trans-urethral stent was placed. The average duration of urine drainage was 4 days with extremes of 2 days and 10 days. Revision surgery was necessary in 18 patients, i.e. 31%. The results were considered good in 35 cases (69%). Re-surgery was effective in 23 patients (39.65%). Table 2 illustrates the results according to the severity of the hypospadias.

Results Type	Anterior	Mid	Posterior	Total
Good	17	14	4	35
Medium	7	2	7	16
Bad	4	2	1	7
TOTAL	28	18	12	58

**Table 2:** Distribution of therapeutic results according to anatomical types.

14 patients presented complications at the time of the evaluation, that is 27%. The most frequent was the urethro-cutaneous fistula with 7 cases, representing 50%. Urethroplasty using the Duplay technique presented more recurrence-type complications (Figure 1). After a mean follow-up of 23 months (extreme 12 and 60 months), 16 (27%, 58%) children presented a complication, half of which was a urethro-cutaneous fistula.



**Figure 1:** Distribution of patients by type of complication.

## Discussion

There is no consensus on the minimum age for surgery. Most authors plan the operation between 12 months and 18 months, waiting for the first phase of penis growth to be completed. On the other hand, it would be preferable not to operate on children between 2 and 4 years old, the postoperative course is often less simple in continent children [3]. The mean age at the intervention in our study was 3 years. Age at first consultation in developing countries is higher than in the Western part of the world because of insufficient means, the lack of specialists, which means that patients can be operated on after the age of 4 [4]. The anterior forms are the most frequent and several surgical techniques have been described [5]. In our study, the most used techniques are those of Duplay, Onlay and Mathieu. This is explained by the habits of the department and also by the anatomical type. In the posterior hypospadias, the flap of the preputial mucosa clearly imposes itself, most often in Onlay. In our series, a little more than 15% of the patients benefited from a urethroplasty according to the Onlay technique. The use of free flaps from the buccal or bladder mucosa is only done exceptionally in very posterior forms, or when there is no longer any foreskin. In our series, these flaps were rare and used the oral mucosa in one or two stages according to the technique described by Bracka. It is essential to use fine instruments allowing precise work. Magnifying glasses with a magnification of 3 to 4 times seem to be easier to use than the microscope [6]. The composition of the suture material and the suture placement technique can contribute significantly to the outcome of hypospadias repair. A significantly low fistula rate (4.95% versus 16.6%) was noted by Ulman and colleagues [7].

in subcutaneous repair compared to full-thickness repair. Usually, sutures with absorbable polyglactin are useful for closure of the innermost layer with epithelial inversion, while polyglyconate sutures are used for the other layers [8]. In our series, polyglactin and polydioxanone were the most used suture materials, with no notion of choice but depending on availability. The drainage of urine is more often provided by a transurethral catheter. For posterior hypospadias and revisions, almost all teams are in favor of drainage. The duration of drainage depends on the urethroplasty technique [9]. This probe, when indicated, was left in place 48 hours after Mathieu’s intervention, and several days after urethroplasty using a pedicle flap [10]. The repair of the hypospadias aims to obtain a good urinary flow in the axis of the penis, an apical meatus with a well-reconstituted glans, and normal erections. It is always possible to obtain such a result. However, a certain number of complications persist, between 5 and 15% depending on the importance of the anomaly and the complexity of the technique to be used. These complications often require delicate and sometimes random reoperation [6].

The superimposition of a preputial flap associated with the Duplay technique by an experienced pediatric urologist makes it possible to obtain a very low rate of surgical revision while giving a good functional but also aesthetic result [11]. The poor cosmetic result is one of the most frequent complications. It should be noted that the assessment of the cosmetic result made by the patients is often divergent from that of the surgeon [12]. Fistulas represent the second complication in frequency and vary according to the technique used [13,14]. In our study, half of the complications were fistulas. Urethral strictures are less common today because circular anastomoses are less used. Proximal strictures are always serious and only respond to urethral dilatation, so urethroplasty often has to be performed to treat the stricture [12]. Duplay’s intervention was the most frequently performed in our series. In the literature, the results are good, with a very low complication rate [15,16]. Performing a midline incision according to Snodgrass does not seem to reduce the risk of complications, but does provide a very satisfactory appearance of the urethral meatus, provided the tubing has not been carried out very distally [17]. In the series of Buisson [18], 52 patients were operated on using this technique. The minimum follow-up was 6 months after urethroplasty. Through these various publications, the intervention of Snodgrass arouses enthusiasm due to its excellent results both functionally and aesthetically. The Onlay technique is currently considered the most reliable in posterior hypospadias with a lower complication rate. Other techniques can be used, such as that of Koyanagi, but with a higher rate of complications [19]. Even the use of estrogen preoperatively does not significantly reduce complications after treatment for hypospadias.

## Conclusion

The Duplay and Onlay surgical techniques were the most frequently used in the treatment of hypospadias in our practice. The results of hypospadias treatment have improved in recent years despite still significant morbidity.

## References

1. Baskin LS, Ebbers MB (2006) Hypospadias: anatomy, etiology, and technique. *J Pediatr Surg* 41: 463-472.
2. Albers N, Ulrichs C, Gluer S, Hiort O, Sinnecker FHG, et al. (1997) Etiologic classification of severe hypospadias: implications for prognosis and management. *J Pediatr Surg* 131: 386-392.
3. Moscovici J, Galinier P, Le Mandat A (2009) Hypospadias: prise en charge chirurgicale. *Arch Pédiatr* 16: 954-955.
4. Bhat AL (2007) Extended urethral mobilization to correct chordee in severe hypospadias: A variation of technique. *J Urol* 178: 1031-1035.
5. Appeadu-Mensah W, Hesse AAJ, Glover-Addy H, Osei-Nketiah S, Etwire V, et al. (2015) Complications of hypospadias surgery: Experience in a tertiary hospital of a developing country. *Afr J Paediatr Surg* 12: 211-2166.
6. Mollard P, Mouriquand P, Felfela T (1990) Traitement des hypospades. EMC (Elsevier Masson SAS), Techniques chirurgicales – Urologie 1990: 41-340.
7. Ulman I, Ericki V, Avanoğlu A, Gökdemir A (1997) The effect of technique and suturing material on complication rate in hypospadias repair. *Eur J Pediatr Surg* 7: 156-157.
8. Tittley OG, Bracka A (1998) 5 year audit of trainees experience and outcomes with two stage surgery. *Br J Plast Surg* 51: 370-375.
9. Dominique S, Louvain-La-Neuve (2003) Recherche théorique sur les implications psychologiques de l'hypospadias. Disponible à partir de.
10. Mathieu P (1932) Traitement en un temps de l'hypospade balanique et juxta balanique. *J Chir* 39: 481.
11. Le Mandat, A. Paye Jaouen, M. Jallouli, A. El Ghoneimi (2008) Hypospadias antérieur: « mieux vaut couvrir qu'y revenir ». *Archives de Pédiatrie* 15: 887-922.
12. Mureau MA, Slijper FM, Slob AK, Verhulst FC, Nijman RJ (1996) Satisfaction with penile appearance after hypospadias surgery: the patient and the surgeon view. *J Urol* 155: 703-706.
13. Mouriquand P, Mure PY (2003) Chirurgie des hypospades. *Encycl. Méd.Chir. (Elsevier SAS, PARIS). Techniques chirurgicales. Urologie* 13: 477-485.
14. Retik AB, Keating M, Mandell J (1988) Complications of hypospadias repair. *Urol Clin North Am* 15: 223-236.
15. Mérrot T, Teklali Y, Dodat H, Alessandrini P (2003) Traitement de l'hypospadias antérieur : comparaison de la technique modifiée de Mathieu au Duplay (à propos de 849 enfants). *Ann Urol* 37: 207-209.
16. Ravasse Philippe, Petit T, Delmas P (2000) Hypospadias antérieur: Duplay ou Mathieu? *Prog Urol* 10: 653-656.
17. Snodgrass WT (1999) Tubularized incised plate hypospadias repair: indications, technique; and complications. *Urol* 54: 6-11.
18. Buisson Ph, Ricard J, Hamzy M, Pouzac M, Caarelli JP (2004) Evaluation des résultats du procédé de Snodgrass dans la chirurgie de l'hypospade. *Progrès en Urologie* 14: 385-389.
19. Ben Fredj M, Messaoud R, Laamiri S, Belhassen S, Mosbahi B, et al. (2018) Nourri Intérêt de la technique de Koyanagi dans le traitement de l'hypospadias postérieur chez l'enfant. *24: 331-335.*