



Case Report

Gasless Laparoscopic Removal of 430-Gram Symptomatic Fibroid at 15 weeks of Pregnancy: Case Report

Elvin Piriyev^{1*}, Sven Schiermeier², Thomas Römer³

¹Department of Obstetrics and Gynecology, Academic Hospital Cologne Weyertal University of Cologne, University Witten-Herdecke, Germany

²Department of Obstetrics and Gynecology, University Witten-Herdecke, Marien-Hospital, Witten Marienplatz, 258452, Witten, Germany

³Department of Obstetrics and Gynecology, Academic Hospital Cologne Weyertal University of Cologne, Germany

*Corresponding author: Elvin Piriyev, Department of Obstetrics and Gynecology, Academic Hospital Cologne Weyertal University of Cologne, University Witten-Herdecke, Germany

Citation: Piriyev E, Schiermeier S, Römer T (2022) Gasless Laparoscopic Removal of 430-Gram Symptomatic Fibroid at 15 weeks of Pregnancy: Case Report. J Surg 7: 1599. DOI: 10.29011/2575-9760.001599

Received Date: 08 October, 2022; Accepted Date: 20 October, 2022; Published Date: 24 October, 2022

Abstract

In 5-8% of cases fibroids can cause severe abdominal pain during pregnancy due torsion, red degeneration or necrosis. Fibroidectomy is generally avoided during pregnancy because of high risk of hemorrhagic complications, but in case of severe abdominal pain fibroidectomy can be required. We present the case of a 35-year-old Gravida II/ Parity I (first birth per caesarean section) woman attended in the emergency department at 15 weeks of pregnancy for severe abdominal pain and fever of 38 °C. A fibroid was found, which had grown significantly during the pregnancy. The pregnancy was intact with timely development of the child. The fibroid was in the fundus of the uterus. The distance between the fibroid and the placenta was 1 cm. At this time the fibroid was 10 cm in diameter. Because of the severe symptoms, which could not be remedied with medical therapy, a surgical therapy was planned. A gasless laparoscopy was performed. Since gas insufflation was not required, the camera could be inserted without a trocar, which on the one hand avoided injury risk of the uterus and unnecessary reposition of the trocar and on the other hand achieved a better view. Intraoperatively, a large fundus fibroid with a wide connection to the uterus was found. Part of the fibroid was inflamed and necrotic. Then using ultracision harmonic scalpel the fibroid was removed completely from the uterus. The incision was then sutured in two layers. The caesarean section was performed at 38+0 weeks of pregnancy. The newborn was healthy and normally developed: height 50cm weight 3060 gram, APGAR 9/10/10.

Keywords: Abdominal pain; Fibroid, Fibroid necrosis; Gasless Laparoscopy; Pregnancy

Introduction

Fibroids are the most common benign uterine tumors and occur in 50-60% of women [1]. The prevalence of uterine fibroids during pregnancy is 1,6-4% [2]. Usually, uterine fibroids remain asymptomatic during pregnancy. However, they may complicate pregnancy's course due increased risk of abortion, premature

rupture of membranes, preterm labour, bleeding and placental abruption [3]. In 5-8% of cases fibroids can cause severe abdominal pain during pregnancy due torsion, red degeneration or necrosis [3]. Fibroidectomy is generally avoided during pregnancy because of high risk of hemorrhagic complications, but in case of severe abdominal pain, which cannot be remedied with medical therapy, fibroidectomy can be required [4]. There are some reports about laparoscopic fibroidectomy, that shows the possibility of using this method in certain cases [2,5-8]. Many authors reported gasless laparoscopy for laparoscopic procedure during pregnancy, which

avoids the effects of carbon dioxide and high intraabdominal pressure [9-12].

Case Presentation

A 35-year-old GII/ PI (first birth per caesarean section) woman attended in the emergency department in at 15 weeks of pregnancy for severe abdominal pain and fever of 38 °C. Before the pregnancy, a fibroid was found, which had grown significantly during the pregnancy. An ultrasound examination was carried out. The pregnancy was intact with timely development of the child. The fibroid was in the fundus of the uterus. The distance between the fibroid and the placenta was 1 cm (Figure 1). At this time the fibroid was 10 cm in diameter.

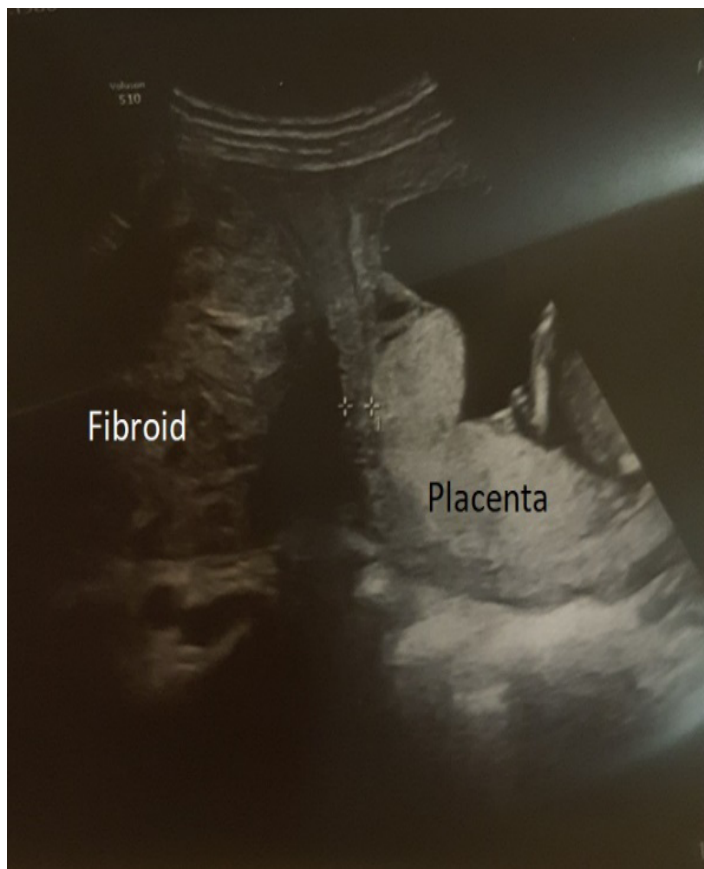


Figure 1: Ultrasonography image: Distance between fibroid and placenta.

Incipient necrosis was suspected. Laboratory results showed increased inflammatory parameters (CRP: 9,9 mg/dl (norm 0,5 mg/dl), leukocytes: 17800). Because of the severe symptoms, which

could not be remedied with medical therapy, a surgical therapy was planned. A gasless laparoscopy was performed. First, the system for gasless laparoscopy was set up. An incision of 2-3 cm in the umbilicus was made. The hooks were put in place and the abdominal wall was lifted (Figure 2). Since gas insufflation was not required, the camera could be inserted without a trocar, which on the one hand avoided injury risk of the uterus and unnecessary reposition of the trocar and on the other hand achieved a better view (Figure 2).

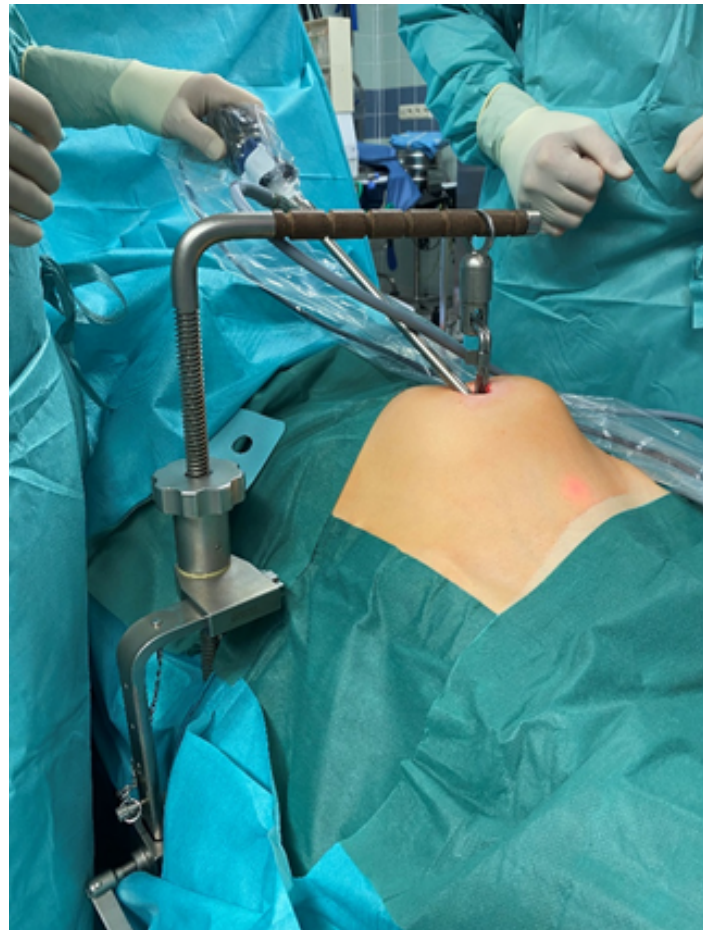


Figure 2: Gasless laparoscopy.

Two 10 mm trocars were inserted into the lower abdomen. Intraoperatively, a large fundus fibroid with a wide connection to the uterus was found (Figure 3). Part of the fibroid was inflamed and necrotic. The major omentum was adherent to this part. First, this adhesion was removed. Then using ultracision harmonic scalpel the fibroid was removed completely from the uterus (Figure 4). The incision was then sutured in two layers (Figure 5).

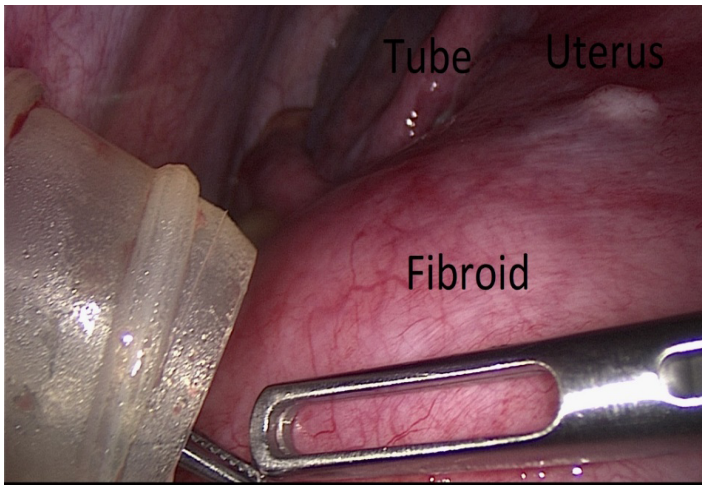


Figure 3: Laparoscopic image: connection between uterus and fibroid.

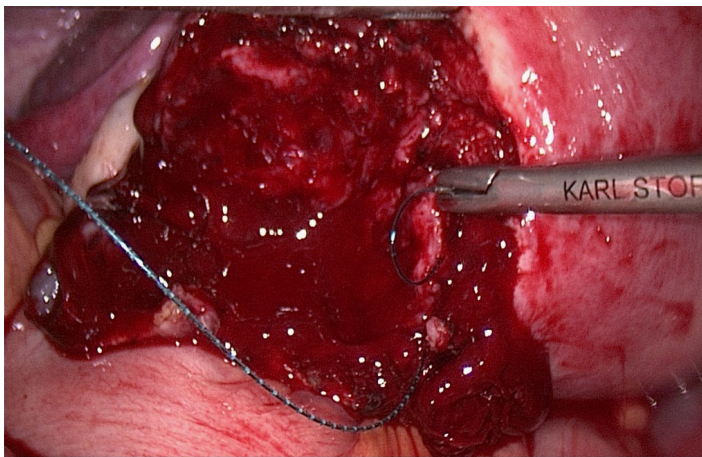


Figure 4: Removal of fibroid.

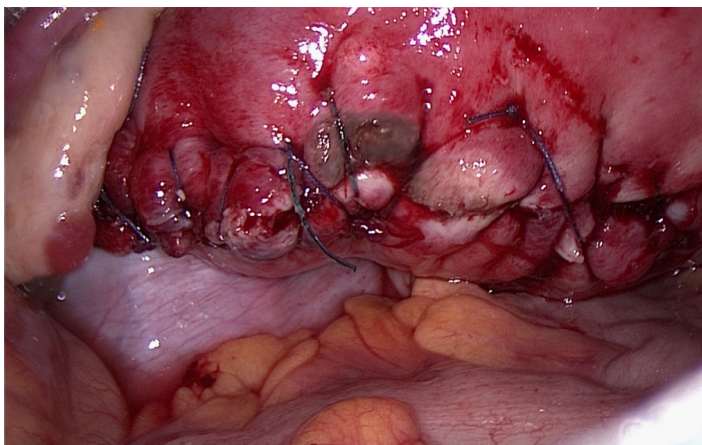


Figure 5: Suture.

The fibroid was removed through the umbilical incision due to cord morcellation with a scalpel. It weighed 430 grams. Because the fibroid was detected before pregnancy and there were no concerns due to sonography and because of patient's age the risk of malignancy in this case was very low [13]. An ultrasound check was carried out intraoperatively and postoperatively, which showed an intact pregnancy. After two days, the patient was discharged in good health condition. Histological examination confirmed inflammatory and necrosis of fibroid. A primary caesarean section at 38+0 weeks of pregnancy was planned with the patient. The caesarean section was performed as planned. The newborn was healthy and normally developed: height 50cm weight 3060 gram, APGAR 9/10/10. The resection site was visible on the uterus, the wall was of normal thickness (Figure 6).

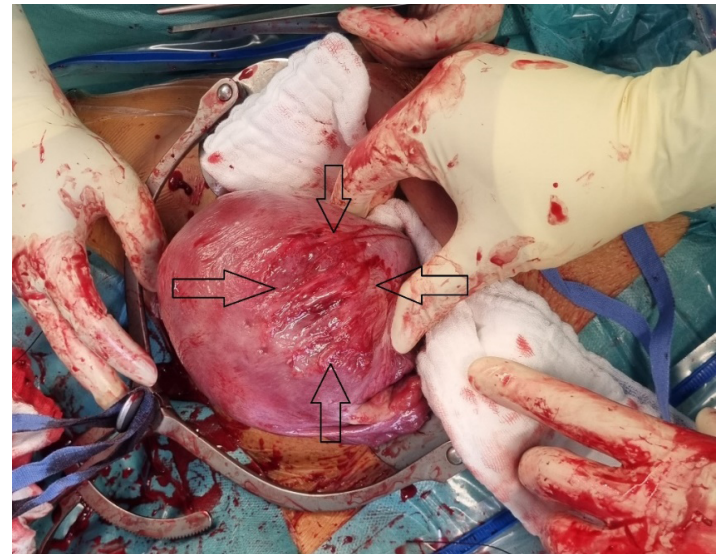


Figure 6: Caesarean section.

Discussion

Although, surgical treatment is challenging during pregnancy sometimes it is required. The most common operations are cholecystectomy, adnexal surgery and appendectomy [8]. The surgery for fibroids is rarer. Usually fibroids remain asymptomatic during pregnancy, so the surgical treatment is usually not required. Severe abdominal pain due to torsion, red degeneration or necrosis of fibroids is the most common indication for an emergency surgical treatment during pregnancy, however the majority of such complications can be managed successfully without surgery [3]. In the most reported cases the surgical treatment for abdominal pain was required in the second trimester [2,5-8]. This can be explained due to the fast growing of fibroids in the second trimester. Both laparoscopy and laparotomy can be performed. It was reported, that the second trimester is the safest time for surgery for some reasons the uterus is still of such a size that it does not block the

operative field compared with the uterus in the third trimester, the theoretical risk of teratogenesis in the second trimester is very low [14].

Laparoscopy is technically more challenging because of the enlarged uterus [14]. However, laparoscopy during pregnancy, especially in the second trimester, is established as a safe and effective method [1-12,14,15]. Compared with laparotomy, the gasless laparoscopy has some advantages. On the one hand it is associated with less fetal depression due to reduced narcotic use in the postoperative period. On the other hand, the advantage of gasless laparoscopic surgery minimal manipulation of the uterus is required, while obtaining adequate exposure, which leads to less uterine irritation, spontaneous abortion, preterm labor, and premature delivery [14].

For laparoscopy during pregnancy some points should be taken into account: in the second half of pregnancy patients should be positioned slight left lateral, in order to alleviate impaired venous return; no instruments should be inserted in the cervix; the secondary trocars should be placed higher than in nonpregnant patients; in order to minimize the risk of maternal hypercarbia and fetal acidosis the intraabdominal pressure should be less than 12 mmHg in case of carbon dioxide laparoscopy [14]. Some authors reported advantages of gasless laparoscopy during pregnancy [5,10,11,14,15]. During gasless laparoscopy maternal and fetal acidosis as well as high intrabdominal pressure can be avoided, which can happen in gas laparoscopy [14,15]. Additionally, a standard closed laparoscopy can lead to uterus injury with the Veress needle and optic trocar [14]. There is a case of fetal loss in 21 weeks of pregnancy because of carbon dioxide insufflation into the amniotic cavity due the uterus injury with Veress needle [16]. In additional, a further advantage is ability to use conventional instruments in gasless laparoscopy [15].

Conclusion

Surgery during pregnancy should be avoided. However, in certain situations an emergency surgery can be required, which should be carried out by an experienced surgeon. Laparoscopy should be preferred, if it is possible. In order to be able to avoid the risks of maternal and fetal acidosis, high intraabdominal pressure as well as risk of uterus injury with a Veress needle or optic trocar, gasless laparoscopy can be a preferred option.

References

1. Donnez J, Dolmans M-M (2016) "Uterine fibroid management: from the present to the future". *Hum Reprod Update* 22: 665-686.
2. Ardovino M, Ardovino I, Castaldi MA, Monteverde A, Colacurci N, et al. (2011) "Laparoscopic myomectomy of a subserous pedunculated fibroid at 14 weeks of pregnancy: a case report". *J Med Case Rep* 5: 545.
3. Phelan JP (1995) "Myomas and pregnancy". *Obstet. Gynecol. Clin. North Am* 22: 801-805.
4. Guidelines Committee of the Society of American Gastrointestinal and Endoscopic Surgeons, Yumi H (2008) "Guidelines for diagnosis, treatment, and use of laparoscopy for surgical problems during pregnancy". *Surg Endosc* 22: 849-861.
5. Melgrati L, Damiani A, Franzoni G, Marziali M, Sesti F (2005) Isobaric (gasless) laparoscopic myomectomy during pregnancy. *J Minim Invasive Gynecol* 12: 379-381.
6. Pelosi MA, Pelosi MA, Giblin S (1995) Laparoscopic removal of a 1500g symptomatic myoma during the second trimester of pregnancy. *J Am Assoc Gynecol Laparosc* 2: 457-462.
7. Sentilhes L, Sergent F, Verspyck E, Gravier A, Roman H, et al. (2003) Laparoscopic myomectomy during pregnancy resulting in septic necrosis of the myometrium. *BJOG* 110: 876-878.
8. Lolis DE, Kalantaridou SN, Makrydimas G, Sotiriadis A, Navrozoglou I, et al. (2003) "Successful myomectomy during pregnancy". *Hum Reprod* 18 :1699-702.
9. Shay DC, Bhavani-Shankar K, Datta S (2001) "Anesthesia for minimally invasive surgery: laparoscopy, thoracoscopy, hysteroscopy. Laparoscopic surgery during pregnancy". *Anesthesiol Clin North Am* 19: 1-7.
10. Schmidt T, Nawroth F, Foth D, et al. (2001) Gasless laparoscopy as an option for conservative therapy of adnexal pedicle torsion with twin pregnancy. *J Am Assoc Gynecol Laparosc* 8: 621-622.
11. Akira S, Yamanaka A, Ishihara T, et al. (1999) "Gasless laparoscopic ovarian cystectomy during pregnancy: comparison with laparotomy". *Am J Obstet Gynecol* 180: 554-557.
12. Curet MJ (2000) "Special problems in laparoscopic surgery". *Surg Clin North Am* 80: 1-14.
13. Piriye E, Schiermeier S, Bends R, Römer T (2022) Reply to "Concerns about transcervical radiofrequency ablation of uterine fibroids". *J Gynecol Obstet Hum Reprod* 51: 102331.
14. Al-Fozan H, Tulandi T (2002) "Safety and risks of laparoscopy in pregnancy". *Curr Opin Obstet Gynecol* 14: 375-379.
15. Römer T, Bojahr B, Schwesinger G (2002) Treatment of a torqued hematosalpinx in the thirteenth week of pregnancy using gasless laparoscopy. *J Am Assoc Gynecol Laparosc* 9: 89-92.
16. Friedman JD, Ramsey PS, Ramin KD, Berry C (2002) "Pneumoamnion and pregnancy loss after second trimester laparoscopic surgery". *Obstet Gynecol* 99: 512-513.