



Research Article

High Viscosity Cement Decreased Adjacent Fracture in Vertebroplasty

Li-Kuei Yang, Zhi-Hong Zheng*, Leou-chyr Lin, Ru-Yu Pan, Kuo-hua Chao

Department of Orthopedic Surgery, Cardinal Tien Hospital, Hospital in New Taipei City, Taiwan

*Corresponding author: Zhi-Hong Zheng, Department of Orthopedic Surgery, Hualien Armed Forces General Hospital, Hospital in Hualien City, Taiwan

Citation: Li-Kuei Yang, Zhi-Hong Z, Lin LC, Pan RY, Chao KH (2022) High Viscosity Cement Decreased Adjacent Fracture in Vertebroplasty. J Orthop Res Ther 7: 1246 DOI: 10.29011/2575-8241.001246

Received Date: 17 August, 2022; Accepted Date: 22 August, 2022; Published Date: 25 August, 2022

Abstract

Vertebroplasty is the treatment for VCF, but complication like adjacent fracture which is still unclear the risk factor and prevention method. Thus, we assumed the higher density is one of the risk factors of the segment(vertebrobody/ intervertebral disc) which underwent vertebroplasty. In our study, high viscosity cement has lower cement leakage to disk level and also lower adjacent vertebral fracture than low viscosity cement.

Keywords: vertebroplasty, high viscosity cement, adjacent fracture, vertebral compression fracture, spine

Introduction

Low-energy trauma and osteoporotic fragility vertebrobody compression fracture lead to the surgical treatment, vertebroplasty or kyphoplasty, the different bony cement material during the operation leads to the different surgical outcome. High-viscosity cement significantly enhances cement infiltration into a porous cancellous bone [1]. Intra-discal cement leakage does not seem to be related to subsequent adjacent vertebral compression fracture [2]; Leakage of cement into the disk during vertebroplasty increases the risk of a new fracture of adjacent vertebral bodies [3], Patients should be informed the possibility of new adjacent fractures and the higher risk if cement leaks into the disk [4]. Thus, we assumed the higher density is one of the risk factors of the segment (vertebrobody/ intervertebral disc) which underwent vertebroplasty caused adjacent fracture because cement leakage to

intervertebral disc area, we set these goals to be studied of the different characteristic bony cement.

Material and Methods

This is a retrospective case-series study, and it was approved by the institutional Review Board of Tri-service general hospital. We evaluated 2017/01-2019/12, total 366 patients (49 males, 317 females, average age 79.4, data at the list as Table 1) under diagnosis of VCF. 174 who underwent vertebroplasty with Depuy confidence (high-viscosity cement, HVC); 133 who received vertebroplasty with Johnson & Johnson cement (low-viscosity cement, LVC), follow up for 1-2 years. In our practice, the patient all underwent IVG and local anesthesia, and bony cement can be percutaneously introduced into the vertebral body through minimally invasive technique that are very similar to percutaneous pedicle screw technique [5]. we use of smaller volumes of cement (3.1-5.5ml), injection time 3-6 minutes in both group.

Compression fracture	T7	T8	T9	T10	T11	T12	L1	L2	L3	L4	L5	Total
HVC	1	2	1	5	15	37	53	27	21	7	5	174
LVC	0	0	1	5	19	24	32	27	10	8	7	133
Total	1	2	2	6	34	61	85	54	31	15	12	303
Percentage	T7	T8	T9	T10	T11	T12	L1	L2	L3	L4	L5	
HVC	0.50%	1.00%	0.50%	2.80%	7.50%	21.20%	30.40%	15.50%	12%	4.00%	2.80%	
LVC	0.70%	1.50%	1.50%	4.50%	25.50%	18%	24%	20.30%	7.50%	6.00%	5.26%	

Result

In our study, we collect the data of the distribution of vertebral compression fracture in each level of spine, and the numbers of treated of 2 types of HVC and LVC. For the adjacent vertebral fracture. For new-level vertebral fractures, our analysis found the result between the 2 methods (data list at Tables 2-4) (Figures 1-5).

Compression fracture	T7	T8	T9	T10	T11	T12	L1	L2	L3	L4	L5	Total
HVC	1	2	1	5	15	37	53	27	21	7	5	174
LVC	0	0	1	5	19	24	32	27	10	8	7	133
Total	1	2	2	6	34	61	85	54	31	15	12	303
Percentage	T7	T8	T9	T10	T11	T12	L1	L2	L3	L4	L5	
HVC	0.50%	1.00%	0.50%	2.80%	7.50%	21.20%	30.40%	15.50%	12%	4.00%	2.80%	
LVC	0.70%	1.50%	1.50%	4.50%	25.50%	18%	24%	20.30%	7.50%	6.00%	5.26%	

Adjacent fracture	T7	T8	T9	T10	T11	T12	L1	L2	L3	L4	L5	total
HVC	0	0	0	0	2	4	5	2	2	0	0	15
LVC	0	0	1	4	5	7	7	0	1	0	0	25
Total	0	0	1	4	7	11	12	2	3	0	0	40

Cement leakage	T7	T8	T9	T10	T11	T12	L1	L2	L3	L4	L5	total
HVC	0	0	0	0	0	2	2	1	0	0	0	5
LVC	0	0	0	1	2	3	5	1	0	0	0	12
Total	0	0	0	1	2	5	7	2	0	0	0	17

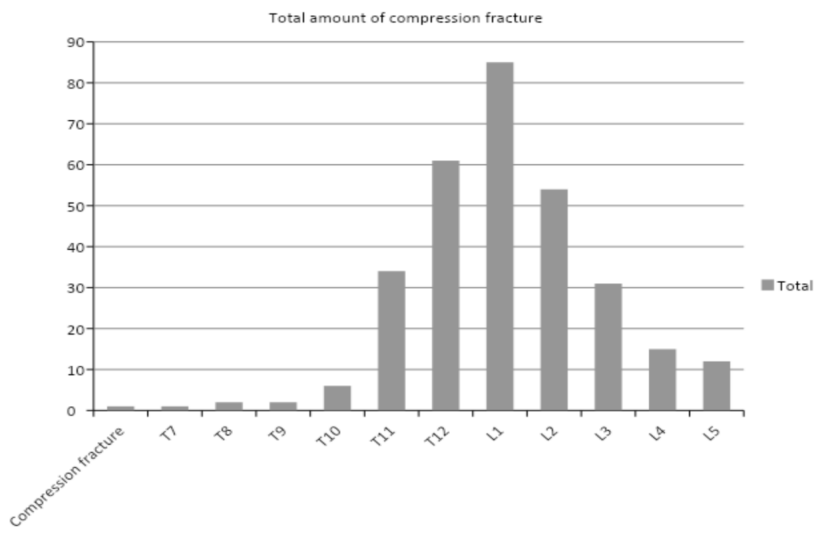
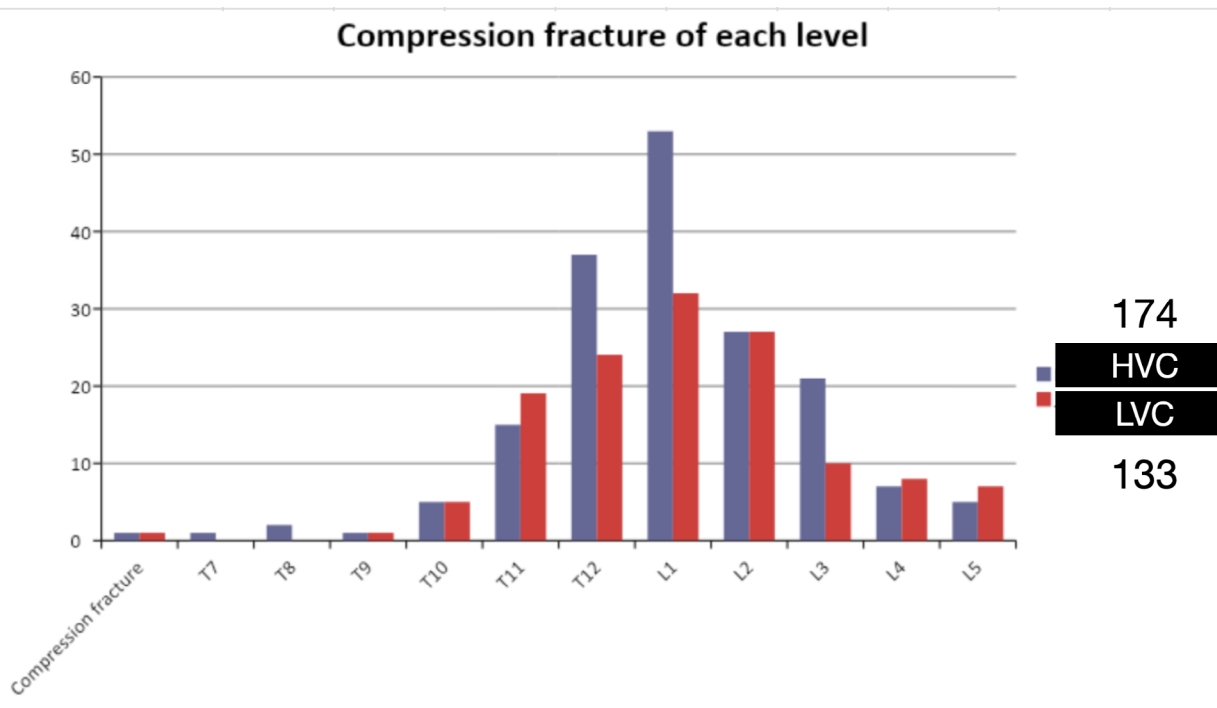
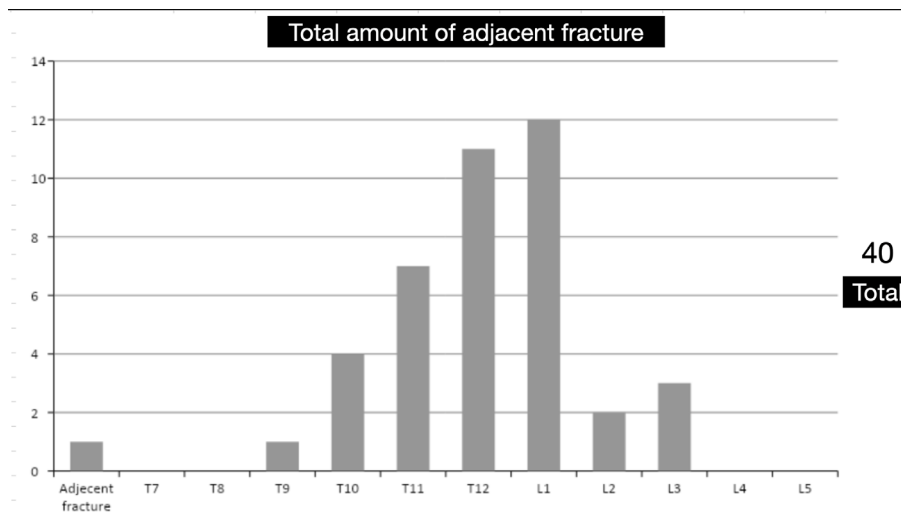


Figure 1: Total 366 patients underwent vertebroplasty with both cement material in each segment of compression fracture.



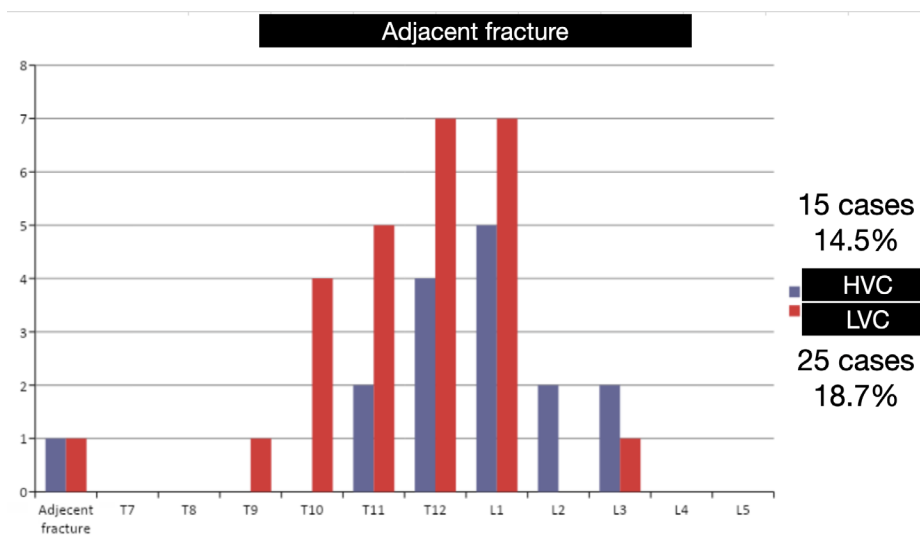
Blue stripe: HVC in each segment, total 174; Red stripe: LVC in each segment, total 133, The peak located over the 11th thoracic spine to the 3rd lumbar spine

Figure 2: Compression fracture in each segment.



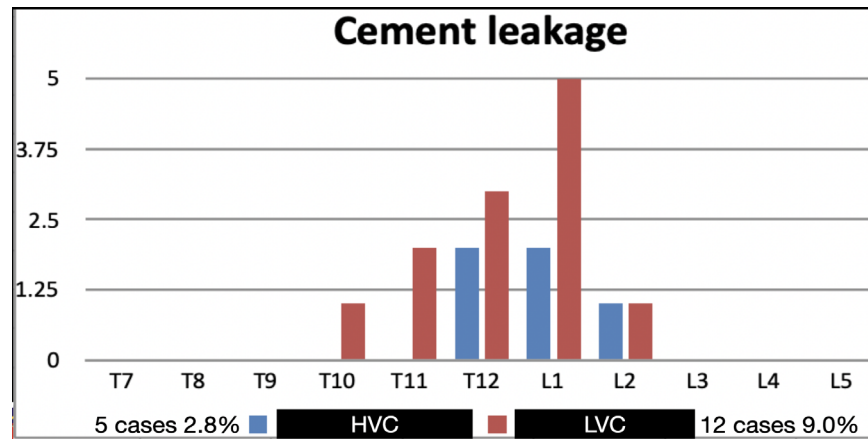
Total amount(40) of adjacent fractures in each segment, both HVC and LVC; The peak located over the 11th thoracic spine to the 1st lumbar spine.

Figure 3: Adjacent fracture of both HVC & LVC.



Blue stripe: HVC, 15 cases(15/174, 14.5%); Red stripe: LVC, 25 cases(25/133, 18.7%)

Figure 4: Adjacent fracture in each segment.



Blue stripe: HVC, 5 cases(5/174, 2.8%); Red stripe: LVC, 12 cases(12/133, 9.0%)

Figure 5: cement leakage to intervertebral disc area in each segment.

Discussion

The overall vertebral compression fractures occurred of T12 and L1 the most. A recent meta-analysis demonstrated no difference in adjacent vertebral fracture with cement augmentation as compared with conservative treatment [6]. But in our study revealed that the HVC reduced the risk of adjacent vertebral fracture: HVC has the lower incidence 14.5% compared with LVC 18.7%($P = 0.022$). Also adjacent vertebral fracture occurred at T12 and L1 in both group the most. Cement leakage to intervertebral disc level: HVC has the lower incidence 2.8% compared with LVC 9.0%($P = 0.028$). Cement leakage level also occurred at T12 and L1 level which underwent vertebralplasty. Adjacent fracture/ cement leakage has positive correlation ($P = 0.009$) in our study. Edward et al concluded the cement leakage to the disk increase the risk of subsequent fracture of adjacent vertebral bodies [7]. And this phenomenon also was observed in our study, and we noticed maybe that's also a contributing factor that because HVC has lower cement leakage to disk level which caused lower adjacent vertebral fracture rate than LVC.

Limitation

Retrospective study, unbiased randomization of patients of cementation.

Conclusion

In our study, in vertebroplasty high-viscosity cement decreased leakage incidence and adjacent fracture rate. The lower cement leakage incidence has the positive correlation with lower incidence of adjacent fracture.

Reference

1. Habib M, Serhan H, Marchek C, Baroud G (2010) Cement leakage and filling pattern study of low viscous vertebroplastic versus high viscous confidence cement, SAS journal 4: 26-33.
2. Kyung-Ah Lee, Suk-Joo Hong, Seunghun Lee, In Ho Cha, Baek-Hyun Kim (2011) Analysis of adjacent fracture after percutaneous vertebroplasty: does intradiscal cement leakage really increase the risk of adjacent vertebral fracture? Skeletal Radiology 40: 1537-1542.
3. Edward P Lin, Sven Ekholm, Akio Hiwatashi, Per-Lennart Westesson (2004) Vertebroplasty: cement leakage into the disc increases the risk of new fracture of adjacent vertebral body AJNR Am J Neuroradiol 25: 175-180.
4. Wen-Jer Chen, Yu-Hsien Kao, Shih-Chieh Yang, Shang-Won Yu, Yuan-Kun Tu, et al. (2010) Impact of Cement Leakage Into Disks on the Development of Adjacent Vertebral Compression Fractures. Journal of Spinal Disorders & Techniques 23: 35-39.
5. Marcia S, Muto M, Hirsch JA (2018) What is the role of vertebral augmentation for osteoporotic fractures? A review of the recent literature. Neuroradiology 60: 777-783.
6. Zhang H, Xu C, Zhang T, Gao Z, Zhang T (2017) Does percutaneous vertebroplasty or balloon kyphoplasty for osteoporotic vertebral compression fractures increase the incidence of new vertebral fractures? A meta-analysis. Pain Physician 20: E13-E28.
7. Edward P Lin, Sven Ekholm, Akio Hiwatashi, Per-Lennart Westesson (2004) Vertebroplasty: Cement Leakage into the Disc Increases the Risk of New Fracture of Adjacent Vertebral Body. AJNR Am J Neuroradiol 25: 175-180.