



Case Report

Impending Rupture of A Rapidly Evolving Descending Thoracic Aortic Aneurysm in a Patient with Active Sars-Cov2 Infection: Surgical and Anesthetic Approach

Maria Grazia Romeo*, Emanuele Pilato, Annarita Iavazzo, Mario Torre, Fabio Scigliano, Luigi Di Tommaso

Department of Advanced Biomedical Science, Cardiac Surgery, University “Federico II”, Naples, Italy

*Corresponding author: Maria Grazia Romeo, Department of Advanced Biomedical Science, Cardiac Surgery, University “Federico II”, Via S. Pansini 5, 80131, Naples, Italy

Citation: Romeo MG, Pilato E, Iavazzo A, Torre M, Scigliano F, Tommaso LD (2022) Impending Rupture of A Rapidly Evolving Descending Thoracic Aortic Aneurysm in a Patient with Active Sars-Cov2 Infection: Surgical and Anesthetic Approach. J Surg 7: 1683. DOI: 10.29011/2575-9760.001683

Received Date: 13 December, 2022; Accepted Date: 22 December, 2022; Published Date: 26 December, 2022

Abstract

A 70-year-old patient affected by a severe Sars-Cov-2 infection, was admitted in emergency to our department during the second Coronavirus disease 2019 outbreak with suspected descending thoracic aortic ruptured aneurysm. After 36 hours of hospitalization in a specific Covid-unit, following a new onset of chest pain, surgery became mandatory, despite the patient was affected by an active Coronavirus disease 2019 infection. While the indications and the choice of surgical technique for Coronavirus disease 2019 patients are defined by the guidelines, to date, the choice of the anesthetic approach to surgically treat Covid-positive patients still represents a challenge.

Keywords: Covid-19; Descending-thoracic-aortic aneurysm; Endoleak; Endovascular treatment; TEVAR

Introduction

The spread of Coronavirus disease 2019 (Covid-19) pandemic, has led to an upheaval of all fields of medicine. Growing number of hospitalizations for Covid-positive patients has led to reduction of access to health-care facilities for treatment of pathologies usually treated in an elective regimen, giving priority to emergencies [1]. The medical staff was forced to adapt their therapeutic choices and their working methods to comply with new conditions imposed by pandemic.

Case Presentation

A 70-year-old man with active Covid-19 infection, following

chest pain, was transferred in emergency from the Covid-unit to our department with a diagnosis of impending rupture of a descending thoracic aortic aneurysm due to a late acute distal type 1 endoleak develop.

The patient’s clinical history included hypertension and ascending thoracic aortic replacement for an ascending aortic aneurysm, treated 10-years earlier with a Dacron tubular prosthesis and a thoracic aortic endovascular repair (TEVAR), for a descending thoracic aortic aneurysm treated 6-years earlier. Contrast-enhanced-computer-Tomographic-Scan (CT-scan) showed an aneurysmal dilatation of the descending thoracic aorta’s distal part, due to an endoleak type-Ib at distal end of the previously implanted stent-graft and a second aneurysmal dilatation (50 mm) of the supra-diaphragmatic aorta (Figure1).

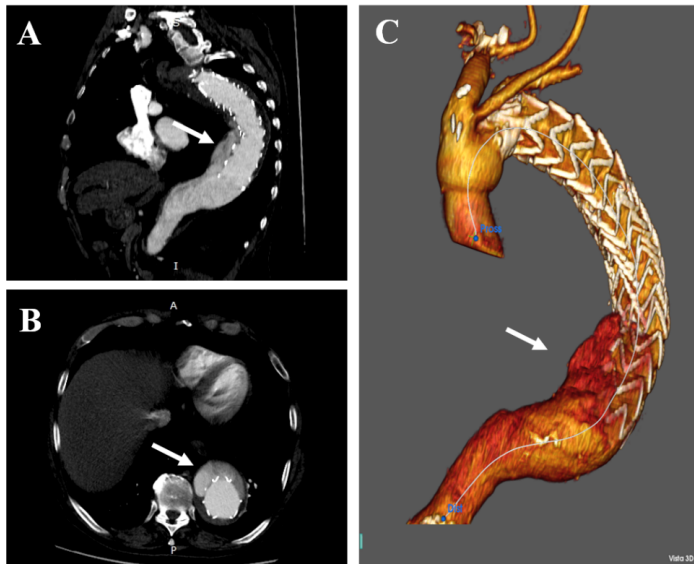


Figure 1: Preoperative CT-scan. **A-B:** Multi-Planar Reconstruction; **C:** 3-D Reconstruction. The arrows show the type 1B distal endoleak.

On admission to our department the patient developed fever higher than 38 °C, dry cough and difficult breathing including a SpO2 less than 93% on room air. Chest X-ray showed a consolidation pattern spreading at the inferior lobes of the lungs and peripheral ground glass opacities. Assessed the patient's stable hemodynamic conditions and confirmed the regression of chest pain, he was transferred back to the Covid-unit of our hospital, to give priority to the infection treatment, planning the endovascular procedure later, when the patient's general condition would be optimal for surgery. During Covid-unit stay, the patient was examined daily by our surgical team in order to evaluate general conditions and aortic disease develop. On the third-day, the patient reported a new chest pain onset associated with worsening of the hemodynamic status. Therefore, despite the concomitant active Covid-19-infection, an emergency treatment of the aortic disease became mandatory. An emergency endovascular approach of aortic disease was planned in our hybrid operating room. After a briefing between the anesthetic care team and the surgical team, we chose to perform endovascular procedure under local anesthesia, avoiding general anesthesia as suggested by Hotta K. [2], favored by the stable clinical, hemodynamic and cognitive conditions of the patient. A distal extension of the previously implanted thoracic endograft was performed (Figure-2). A surgical access was obtained at the left common femoral artery and an aortic stent-graft was implanted. The choice of the operative strategy and the type of anesthesia was submitted to guidelines [3,4] and patient's conditions, in order to avoid intubation, minimize exposure to the staff and to avoid more lung-damaging procedure for patient. The procedure was performed without complications. Immediately

after the procedure, the patient was transferred to our Intensive-Care-Unit (ICU) isolation room, which is equipped with an anti-viral air filtration system. Twenty-four hours after surgery, the patient was transferred to a dedicated Covid-ward. On the 30-day of hospitalization into Covid-ward, following a negative nasopharyngeal swab, serological screening and remission of symptoms, the patient was discharged. A CT-scan follow-up was performed two weeks, six months and one year after surgery, which showed optimal endograft placement and regression of the endoleak.

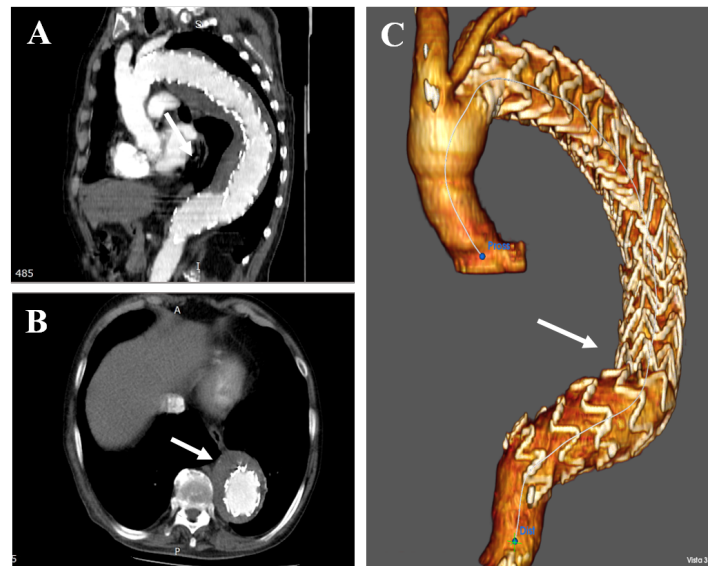


Figure 2: CT-scan at six-month follow-up. **A-B:** Multi-Planar Reconstruction; **C:** 3D-Reconstruction. The arrows show optimal endograft placement and endoleak regression.

Discussion

Currently, the indications and the choice of the operative techniques for the surgical approach of Covid-19 positive patients are established by guidelines [3,4], disease and surgeon experience. Guidance for hospitalization and pre/post-operative isolation for these patients are planned by internal departmental protocol for prevention of hospital acquired Covid-19 infections. Obviously the strategy may vary among different hospitals, based on own architectural design of the hospital facility. At present, anesthetic treatment of covid-19 positive surgical patient still represents a challenge when it is possible to choose between general and local anesthesia. The safety of both patients and healthcare workers should be taken into consideration when performing anesthesia management for these patients. Local anesthesia for TEVAR correlates to shorter ICU stay, lower pulmonary complications, and lower mortality [5,6]. Local anesthesia is not an aerosol generating procedure associated with a lower risk-rate of Covid-19 transmission. Furthermore, all procedures for general anesthesia,

such as mask ventilation, tracheal intubation and extubation can lead to generation of aerosols, a potential threat to all personnel in the operating room. Moreover, general anesthesia and intubation can be associated with a worse patient's outcome, exacerbating respiratory tract infection with further pulmonary complications[7]. An unplanned conversion from local anesthesia to general anesthesia can be considered the main complication of the loco-regional anesthesia procedure increasing spread of infection for patients and operating room staff. Since our patient was compliant with the proposed surgical approach, he was deemed suitable for this anesthetic management.

Conclusion

The anesthetic treatment of the covid-19 positive surgical patient still represents a challenge today. From our experience, we can assume that when it is possible to choose between general and local anesthesia, the latter is to be preferred because it avoids exposure of medical personnel to infections and allows a safer procedure for patients, avoiding intubation and limiting the exposure of personnel to infectious aerosols. At the same time, it allows to decrease the patient's possible pulmonary complications and to reduce the ICU stay, thus improving the outcome. The treatment of the aortic emergencies with an endovascular technique under local anesthesia in Covid-19 positive patients is therefore to be preferred, when the patient's conditions allow it. Less invasive surgical and anesthetic approaches are the key to managing cardiovascular emergencies, reducing hospitalization times and avoiding contagion from Covid-19.

References

1. Czerny M, van den Berg J, Chiesa R, Jacobs M, Jakob S, et al. (2021) Management of acute and chronic aortic disease during the COVID-19 pandemic-Results from a web-based ad hocplatform.*J Card Surg* 36: 1683-1692.
2. Hotta K (2021) Regional anesthesia in the time of COVID-19: a minireview. *J Anesth* 35: 341344.
3. Martin Grabenwöger, Fernando Alfonso, Jean Bachet (2012) Thoracic Endovascular Aortic Repair (TEVAR) for the treatment of aortic diseases: a position statement from the European Association for Cardio-Thoracic Surgery (EACTS) and the European Society of Cardiology (ESC), in collaboration with the European Association of Percutaneous Cardiovascular Interventions (EAPCI), *European Heart Journal* 33: 1558-1563.
4. MacGillivray TE, Gleason TG, Patel HJ (2022) The Society of Thoracic Surgeons/American Association for Thoracic Surgery Clinical Practice Guidelines on the Management of Type B Aortic Dissection. *Ann Thorac Surg* 2022.
5. Tran K (2013) Aerosol-Generating Procedures and Risk of Transmission of Acute Respiratory Infections: A Systematic Review." *CADTH Technology Overviews* 3.
6. Faizer R, Weinhandl E, El Hag S, et al. (2019) Decreased mortality with local versus general anesthesia in endovascular aneurysm repair for ruptured abdominal aortic aneurysm in the Vascular Quality Initiative database. *J Vasc Surg* 70: 92-101.
7. Heffernan, Daithi S (2020) Surgical infection society guidance for operative and peri-operative care of adult patients infected by the severe acute respiratory syndrome coronavirus-2 (SARS-CoV-2). *Surgical infections* 21: 301-308.