



Review Article

Musculo-Skeletal Ultrasound in the Diagnosis of Clinical Orthopedic Disorders: The Orthopedic Stethoscope

Alexander Blankstein*

Department of Orthopedics, Sheba Medical Center University Of Tel Aviv School of Medicine, 16 Kehilat Bavel St, p.o.b 66, Ramat Hasharon 4710001, Israel

*Corresponding author: Alexander Blankstein, Department of Orthopedics, Sheba Medical Center University Of Tel Aviv School of Medicine, 16 Kehilat Bavel St, p.o.b 66, Ramat Hasharon 4710001, Israel

Citation: Blankstein A (2023) Musculo-Skeletal Ultrasound in the Diagnosis of Clinical Orthopedic Disorders: The Orthopedic Stethoscope. J Orthop Res Ther 8: 1279. DOI: 10.29011/2575-8241.001279

Received Date: 13 March, 2023; Accepted Date: 20 March, 2023; Published Date: 23 March, 2023

Introduction

Ultrasound equipment and our clinical experience has continued to evolve and improve, helping to provide a better understanding and treatment of the musculoskeletal disorders. We added more information on this important subject. We have more information on pathology indication and treatment suggestion. We learned the normal sono anatomy and the sono pathology in the musculoskeletal system. A normal orthopedic examination of diverse pathology is done, while moving the joint in order to examine among other the R.O.M – range of motion. The dynamic u.s examination is a part of achieving correct diagnosis and treatment. Ultrasonography has advantages over other imaging modalities in terms of availability and comfort, safety, and diagnostic potential. Operating costs are low compared with both Computed Tomography (CT) and magnetic resonance imaging (MRI). It is safe for all patients, including those with cardiac pacemakers and metal implants, without any contraindications.

Calcification in soft tissue and destructive and reparative hypertrophic changes on bone surfaces are more readily apparent on u.s examination, and at an earlier stage, than with plain X-rays, CT or MRI. Ultrasonography thus enhances early detection of pathologies. The real time capability of musculoskeletal sonography enables dynamic assessment of joint and tendon movements and stability, and detection of fracture union and reunion, structural abnormalities, infection, ligamentous injury, nerve compression and mechanical impingement between orthopedic hardware and soft tissue structures. Beyond diagnostics, real time capability is useful for guiding therapeutic interventions, such as cyst aspiration. The fact that ultrasound examinations may be easily repeated as often as necessary, makes this modality useful for monitoring treatment. Due to its flexibility and precision in the selection of the point of examination and in

the field of vision, musculoskeletal ultrasonography has spatial, as well as temporal benefits. The possibility of placing the sonographic probe at the point of maximal tenderness increases the likelihood of detecting abnormalities, and ensures clinical relevance of the examination. Sonography affords comparisons of targeted findings with those of the contralateral side, and also enables under “vision” biopsy or joint aspiration. Ultrasound does not use radiation and is therefore safe during pregnancy. Ultrasound can also help diagnose the reason of painful movement-related snaps and pops. By evaluating patients dynamically while they demonstrate their symptoms. Of the many indications for musculoskeletal ultrasonography, the evaluation of soft tissue pathology is particularly common. In addition, ultrasonography is useful for the detection of fluid collection, and for visualization of cartilage and bone surfaces. Color or power Doppler provides important physiological information, including that relating to the vascular system. The capability of ultrasonography in delineating structures according to their echo textures results in excellent pictorial representation.

We use ultrasound to guide emerging therapies, including tendon fenestration (percutaneous tenotomy) and platelet-rich plasma (PRP) injections. This imaging principle is based on physical changes in composition, as compared to imaging with MRI, which is based on changes in chemical composition. We use musculoskeletal ultrasound to diagnose and treat a wide range of tendon, muscle and joint disorders. This article reviews the contribution of sonography to the evaluation of the musculoskeletal system.

Neck Region

Ultrasonography is preferable to radiography for the early detection of calcification in soft tissue in the neck region. In the

investigation of suspected soft tissue tumors, such as in acute swelling of sterno-cleido mastoideus, and in cases of congenital muscular torticollis (Figure 1).

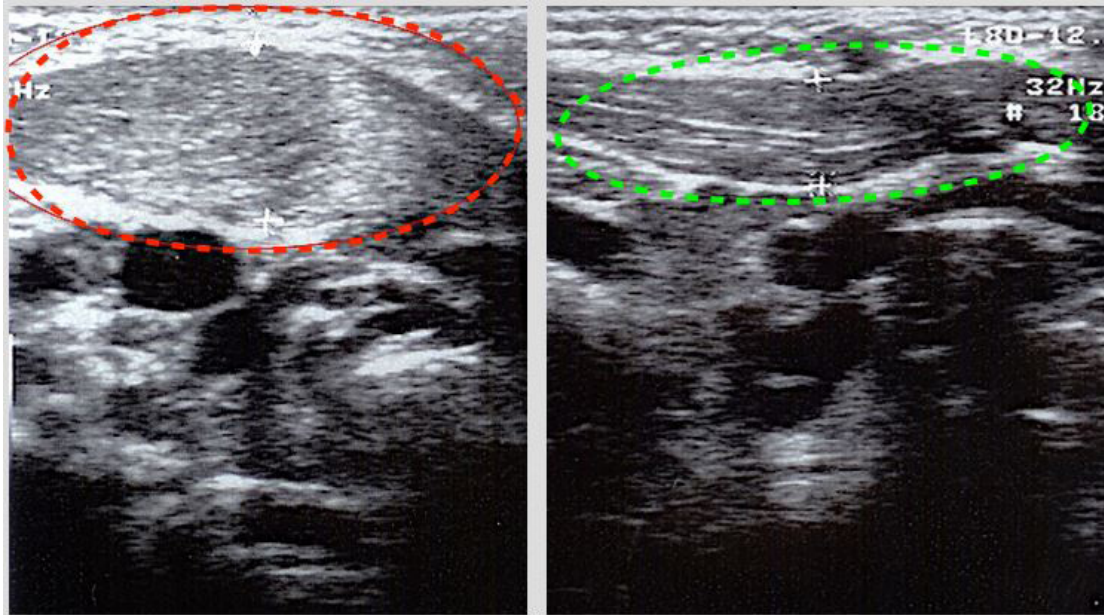


Figure 1: Torticollis: swelling of RT sternocleidomastoid. LT normal appearance.

Ultrasound can often distinguish between a true tumor mass and a hematoma or muscle rupture [1]. In cases of congenital muscular torticollis u.s shows a well defined mass in the sternocleidomastoid muscle. The lesion ranged in size from 8-16 mm. on transvers diameter with length from 14-45 mm. Clinically tilt torticollis, disappears between 1-6 weeks. Unilateral contraction of the S.C.M muscle forces the baby to hold his head towards the affected side [2]. The appearance of an echogenic structure with acoustic shadowing in the region of tenderness may indicate a cervical rib [3]. Fracture of the clavicle in the newborn [4] and congenital pseudoarthrosis of the clavicle can also be diagnosed with ultrasound [5].

Shoulder

Shoulders disorders are commonly experienced, affecting approximately 10% of the population. The shoulder joint is probably the most accessible joint for sonography in the adult. Most shoulder joint syndromes are caused by pathological changes in the periarticular soft tissues of the joint, or are related to an erosive or degenerative arthropathy. Ultrasound offers very high resolution imaging of the tendons of the Rotator cuff and related structures. [6] A further considerable benefit of ultrasound is the opportunity to integrate both clinical history and morphological assessment with dynamic imaging. The sight and nature of pain is helpful in , making the diagnosis. Focal pain along the line of the biceps sheath is suggestive of bicipital tendinitis, or dislocation of biceps (Figure 2).

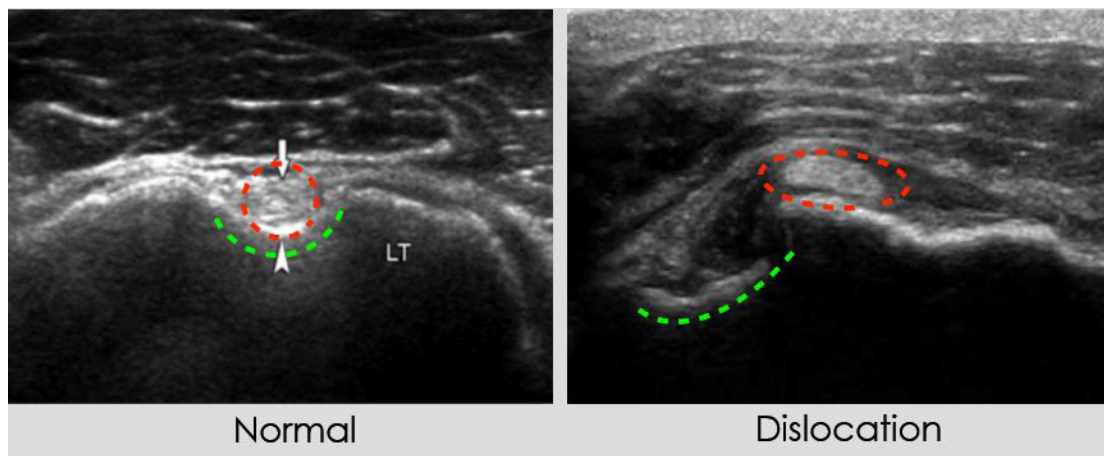


Figure 2: Dislocation of biceps LT shoulder.

Partial-and full thickness rotator cuff tears and tumors of bone (Figures 3).

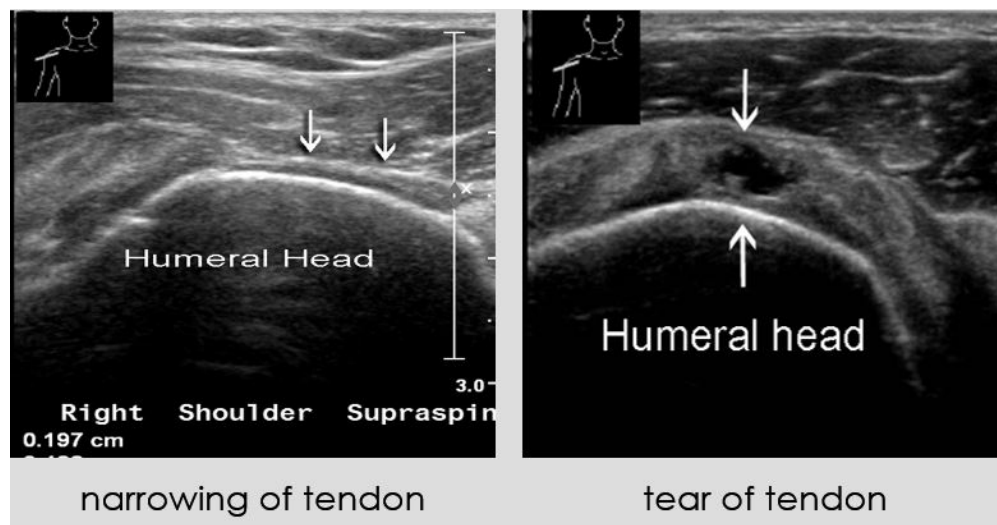
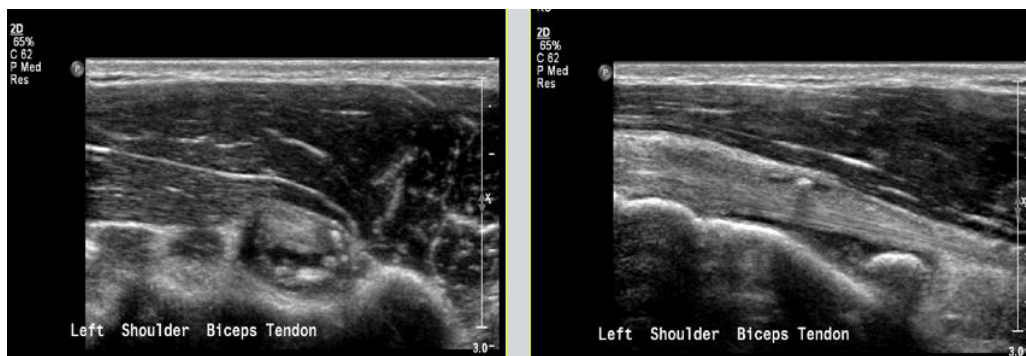
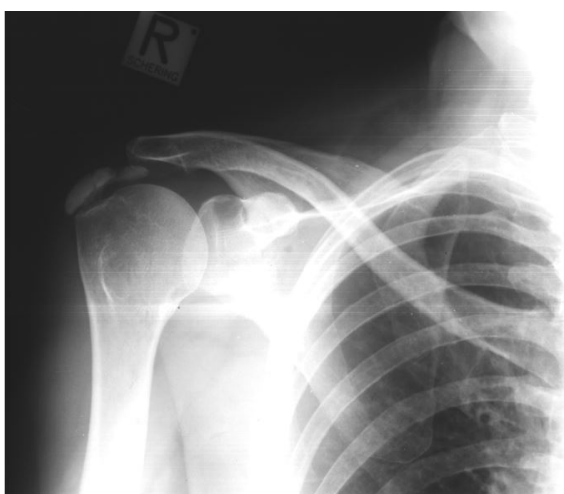

Figure 3: Tear of supraspinatus.

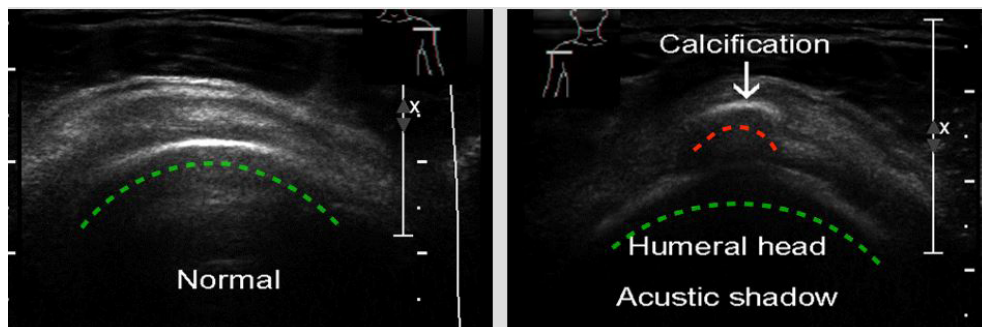
Focal pain localized to the acromioclavicular joint (ACJ) indicates arthropathy. painful arc has symptoms suggestive of impingement. pain worsening at night, may have a variety of etiologies. These include rotator cuff tendinosis (Figure 4).



A



B



C

Figure 4: Calcific tendonitis A,B,C.

The effectiveness of sonography has been demonstrated for the evaluation and diagnosis of Hill-Sachs lesions (Figure 5).

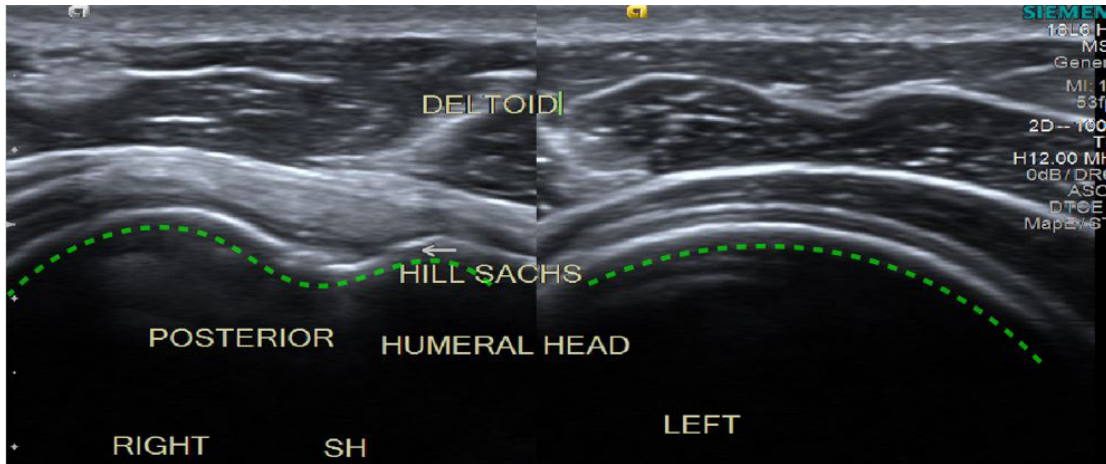


Figure 5: Hill-Sachs lesions.

Which frequently follow anterior gleno-humeral dislocation of the shoulder [7]. Moreover, ultrasound can be used to assess sonographic images in hemiplegic shoulders of stroke patients [8]. Dynamic sonography enables direct visualization of the relationships between the acromion, humeral head, and intervening soft tissues during active shoulder motion, and can provide information on the potential intrinsic and extrinsic causes of shoulder impingement syndrome [9]. In cases of frozen shoulder, abnormal gliding and rotational movement are apparent, with the entire soft tissue moving as a single unit (deltoid, rotator cuff, and humeral head). The capability of ultrasound in detecting a full thickness tear is impressive. Drakeford et al [10] reported sensitivity of 92% and specificity of 95%.

Ultrasound can also be used to detect tears of pectoral muscle (Figure 6).

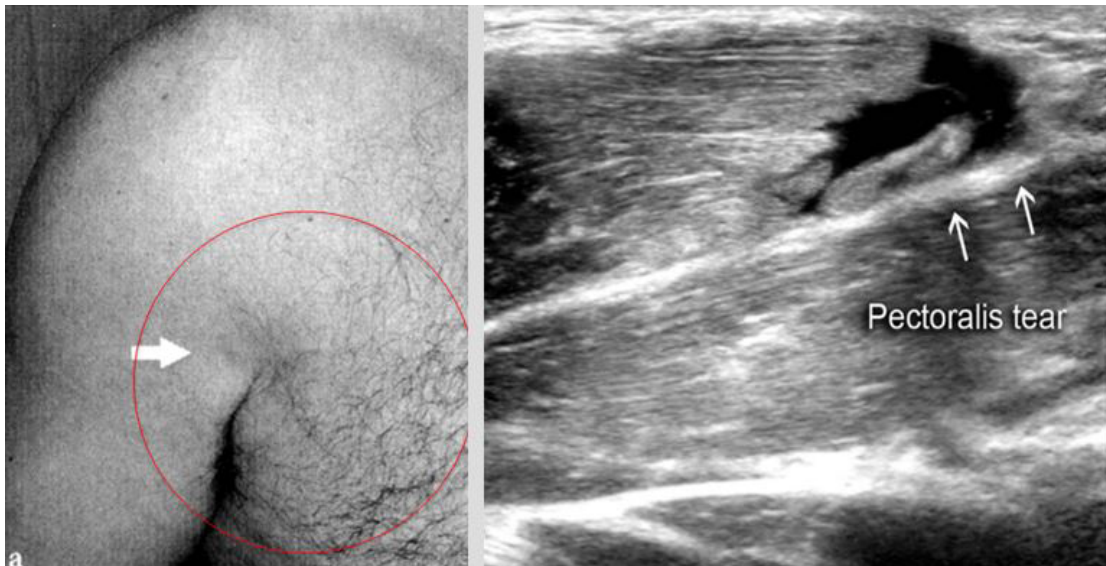


Figure 6: Pectoralis tear.

Ultrasound is useful in detecting pathologies in the acromioclavicular joint, such as acromioclavicular joint arthritis and dislocation [11], as well as septic arthritis of the sternoclavicular [12] and acromioclavicular joints [13] (Figures 7-9).

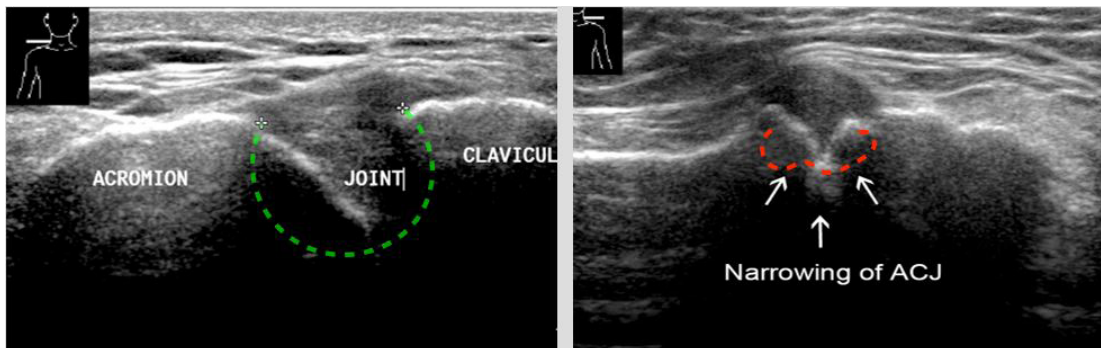


Figure 7: A.C.J Arthritis.

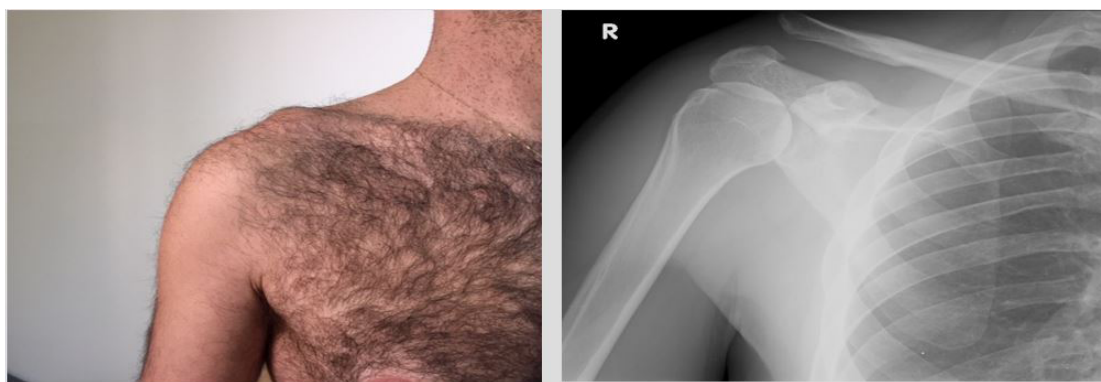

Figure 8,9: A.C.J dislocation.

The presence of fluid around the biceps tendon or subdeltoid bursa may indicate a bursitis infection (Figure 10).

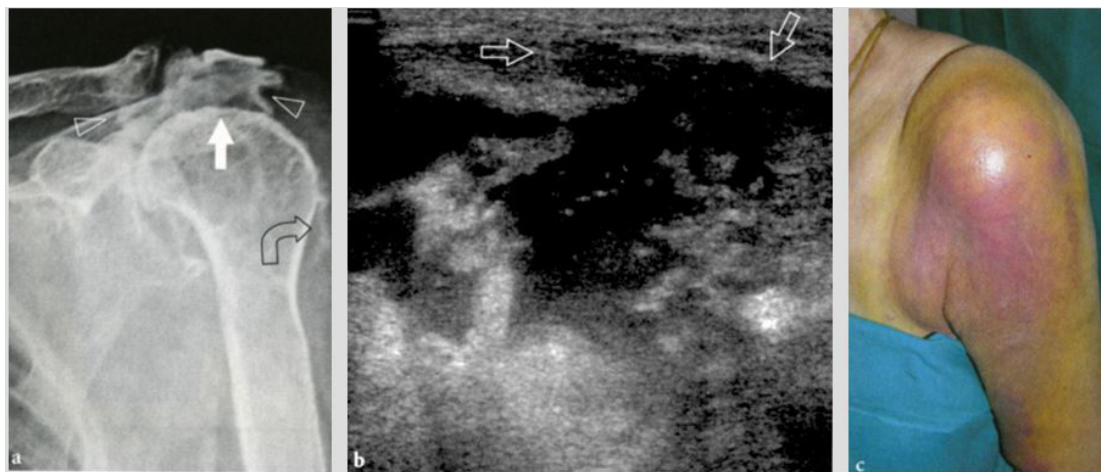


Figure 10: Septic arthritis.

A history of trauma and localized tenderness may indicate the presence of a radiographically occult fracture (Figure 11).

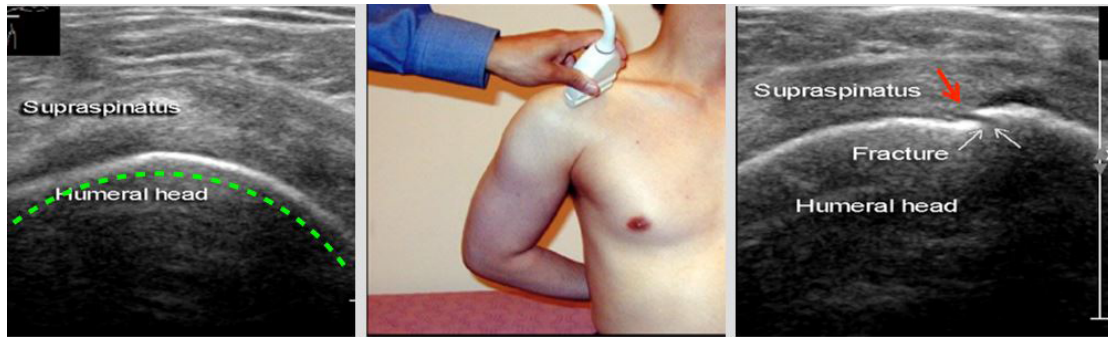


Figure 11: Greater Tuberosity Fracture.

Suspicion of rotator cuff pathology is the most important indication for shoulder sonography. Musculoskeletal ultrasound enables early detection of changes in tendons (Figure 12).

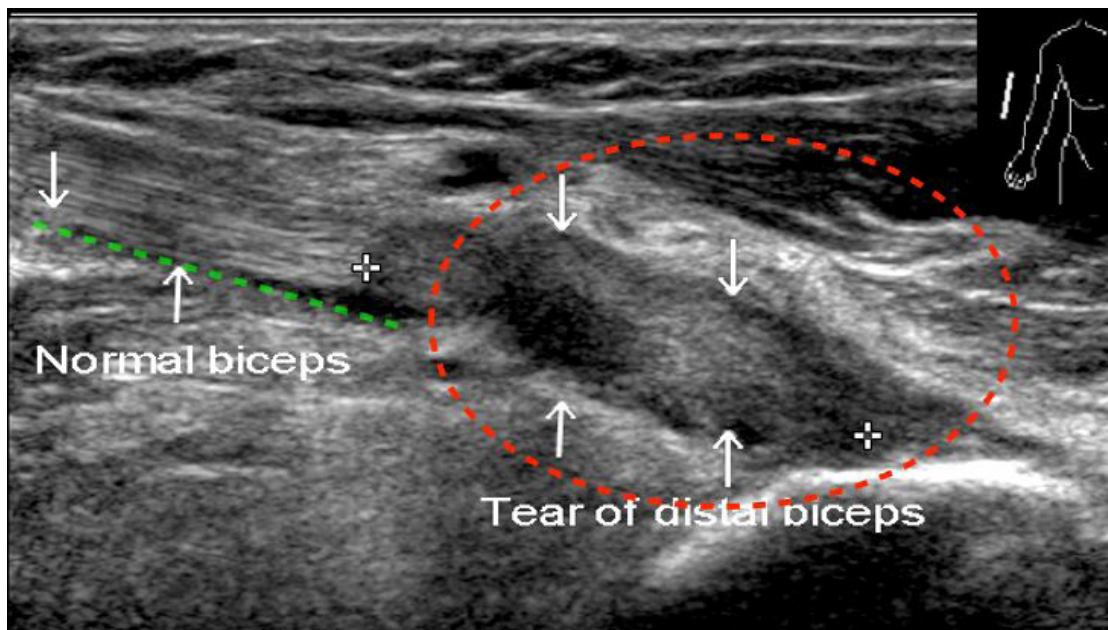


Figure 12: Distal Biceps Tear.

At our medical center, the shoulder is one of the bodily areas for which musculoskeletal sonography is most requested [14]. Age-related degenerative changes and overuse syndrome with degenerative tears leads many patients to seek medical treatment for painful shoulder. Tears can be seen, located, and measured [15-17]. Their full anatomical extent can be assessed. Calcification is more visible with ultrasound than with MRI and the capability of precise location enables assessment of treatment. Sonographic palpation and comparison with the other shoulder is easily performed. Lesions associated with rotator cuff disease, such as long biceps tenosynovitis and sub-acromial deltoid bursitis, can be visualized by ultrasound. Ultrasound can detect fractures in the head and shaft of the humerus, especially the greater tuberosity. Greater tuberosity fractures are characterized by sonography as cortical discontinuity, and may appear as a cortical gap or step-off (double line) [2]. They should be included in the differential diagnosis of every shoulder sonography examination, even in the absence of a clear history of trauma. Osteolytic lesions of the proximal humerus can also be detected in ultrasound (Figure 13).

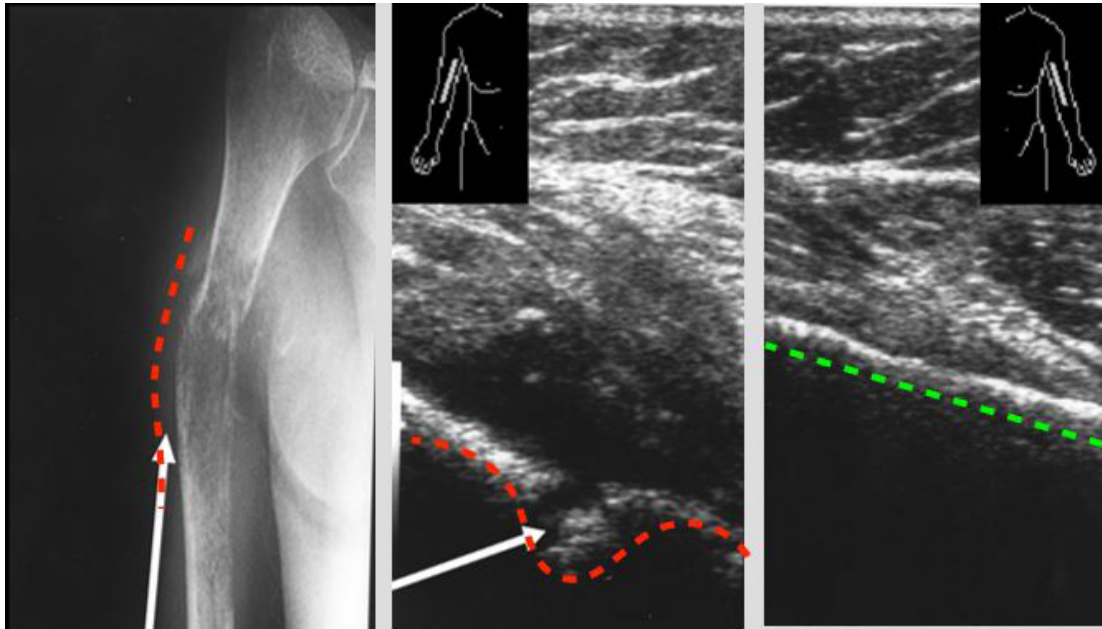


Figure 13: Tumors of bone.

Since conventional radiography does not adequately diagnose symptoms of shoulder pain, a sonographic examination is recommended as part of the early diagnostic protocol [18,19].

Arm-Elbow

Solid and cystic masses can be encountered in the soft tissue of the elbow as incidental findings. Most are benign and have an indolent behavior such as lipomas, ganglia and neural tumors and can be easiest diagnosed with u.s. Ultrasound is useful for examining proximal muscles acting on the shoulder and elbow. Muscle compartments are divided into flexor and extensor groups. Ultrasound can detect common tendon injuries, such as “tennis” and “golfer” elbow, in which swelling, thickening, and accumulation of fluid is apparent [20,21]. Musculoskeletal ultrasound is an effective imaging technique for the diagnosis of olecranon bursitis, especially its early manifestation. Sensitive detection of small fluid collection is possible, as well as differentiation between soft tissue and bone lesion, and between septic and non septic elbow. Ultrasound examination allows detection of effusions, synovial proliferation, calcification, loose bodies, rheumatoid nodules, gout tophi, and septic processes [20-23], as well as distal biceps tendon lesions.

Hand - Wrist

Ultrasound examination of the flexor and extensor tendons and ligaments of the finger may reveal such pathologies as tendinopathy, tenosynovitis, ruptures, and neoplasia (Figures 14-16).

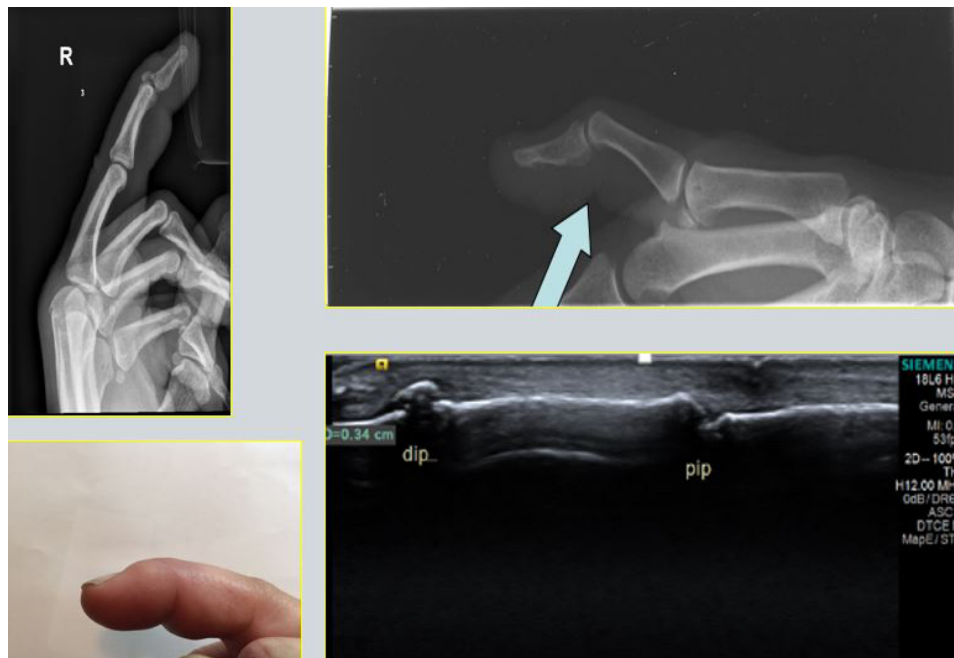

Figure 14: Mallet finger.

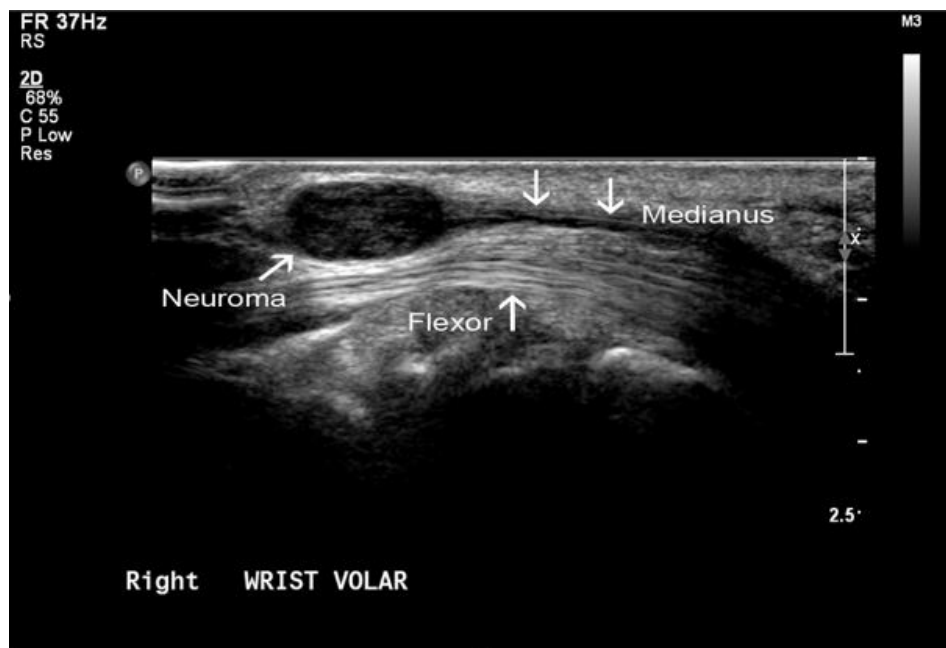


Figure 15: Neuroma of median nerve.

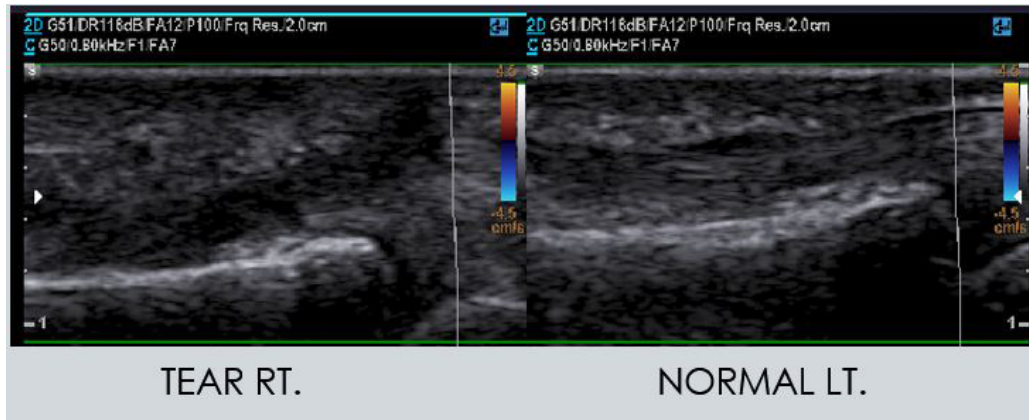


Figure 16: Tear of flexor tendon finger 3 RT.

Cystic or solid swelling palpable tumors and occult ganglion can be observed [24-26]. Foreign bodies often remain undetected in penetrating wounds and lacerations, pathologies frequently treated in the emergency room. Sonography is useful in the localization and removal of soft tissue foreign bodies [27,28], and in the detection of greenstick fractures of the distal radius and ulna [29]. The sonographic examination of a patient with suspected traumatic Mallet finger is important for the differentiation between traumatic Mallet finger and flexion deformity due to rheumatoid arthritis or osteoarthritis [30]. Mallet finger is caused by a disruption of the extensor mechanism. Ultrasound is extremely valuable in identifying sites and extend of rupture, allowing the surgeon to plan reconstructive procedure effectively. Discontinuity of the tendon is the best sign of tendon rupture. Retraction of the tendon can be evaluated with dynamic examination during flexion and extension. Sonography is used helpful in the characteristic of soft tissue mass in the hand. These include ganglion cyst, giant cell tumor lipoma, glomus tumor, vascular pathology, muscle pathology and foreign bodies. u.s can demonstrate inflammatory diseases like RA or Dequervain disease and degeneration changes like Duputren contracture. Ganglion cyst is the most common lesion. It is smooth firm round mass. The most common location is over the scapholunate joint dorsal aspect. Ultrasound can be helpful in differentiating synovial and teno-synovial pathology, and in examining pathological and morphostructural changes of the median nerve in carpal tunnel syndrome.

Knee

Ultrasound is an important adjunct to the clinical examination in the diagnosis of musculoskeletal disorders. Knee problems account for 10% of referrals to orthopedic surgeons. The technique has shown accuracy in the workup of soft-tissue and joint pathology. Knee ultrasound can be routinely used to evaluate traumatic and inflammatory disorders [31]. Nearly every kind of orthopedic disorder presents in the knee. In addition to vulnerability to blunt and penetrating injury, the spectrum of pathology of the knee is broad. In young patients, pathology may appear at birth as in hypoplasia of the patella seen in Nail-Patella syndrome, or may become apparent later in life. The metaphysis around the knee is the part of the lower limb with the most active bone growth during adolescence; as a consequent of the unique anatomy and physiology of the growth plate, it is a common site of osteomyelitis and primary bone tumors. Young active patients usually present with traumatic injury of the bone and/or soft tissues, such as collateral ligament injuries or avulsion of the tibial tuberosity. There is a high prevalence of P.F.P (Patello Femoral Pain) and u.s examination of the knee demonstrate intra articular knee effusion among young dancers. [32].

Older and generally less active patients are more likely to present with degenerative joint disease. The knee may be affected by metabolic, inflammatory noninflammatory, or neoplastic disease. It is prone to almost every kind of arthritis, particularly osteoarthritis (Figure 17).

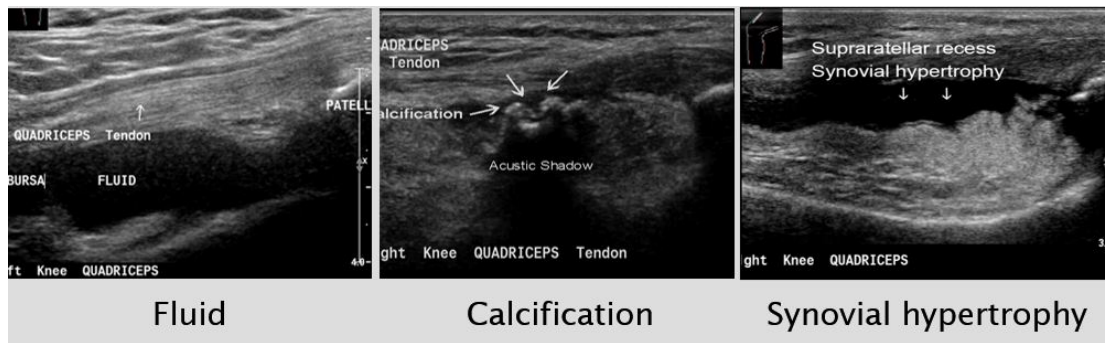


Figure 17: Fluid calcification and synovial hypertrophy.

Moreover, it is the joint most commonly affected by osteochondritis dissecans and intra-articular loose body formation. The possibility of ready comparison between symptomatic and asymptomatic knee, as well as direct correlation of sonographic finding to the patient's symptoms are advantages of ultrasound. The main strength of knee ultrasound is its assessment of periarticular disease. Ultrasound precisely demonstrates the fibrillar microanatomy of tendons, muscles, masses to those familiar with ultrasound knee anatomy. Ultrasound is also effective for joint effusions, synovial thickening, bursal fluid collections, intra-articular loose bodies, ganglia, ligament and tendon tears, (Figures 18).

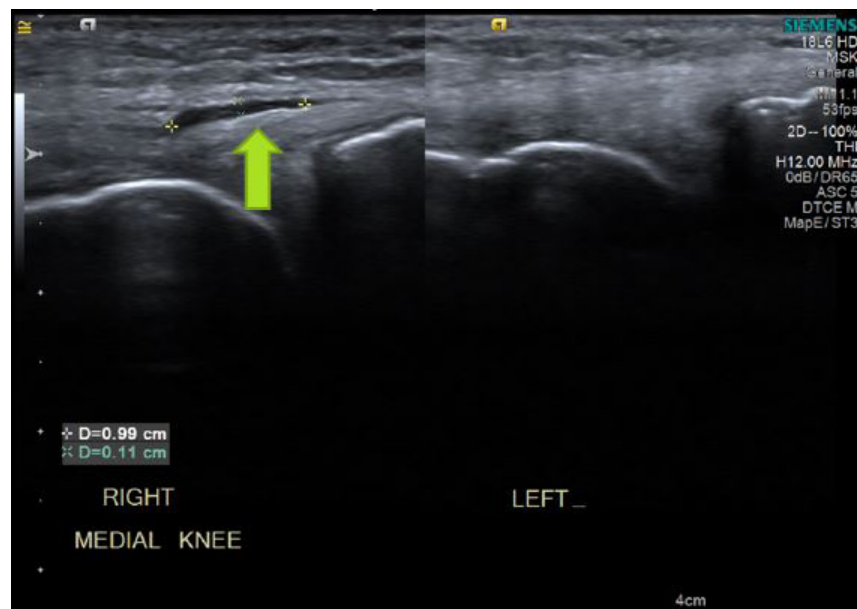


Figure 18: Tear of M.C.L tendonitis, and occult fractures.

Diagnostic ultrasound is an invaluable technique in the management of a variety of musculoskeletal disorders. Technical innovations such as color-flow Doppler, three dimensional surface reconstruction, and ultrasound contrast agents have already introduced new areas to clinical practice. As image quality improves, the role of diagnostic ultrasound in clinical orthopedic practice increases. safety and availability are strengths of diagnostic ultrasound. While, clinical examination of the knee joint is relatively easy, very small effusions and synovitic proliferations may be missed. Ultrasound can detect these, as well as fluid in the knee and in the area of the tendons. Further, ultrasound is useful for assessing ligaments, and for diagnosing pathologies relating to anterior knee pain [33-35]. Dynamic sonographic examination, with stress tests, can demonstrate instability and meniscal pathology [36]. Synovial cysts, medial collateral ligaments, lateral collateral ligaments and tears of tendon can be assessed. Ultrasound is also used in diagnosis of patellar and quadriceps tears (Figure 19).

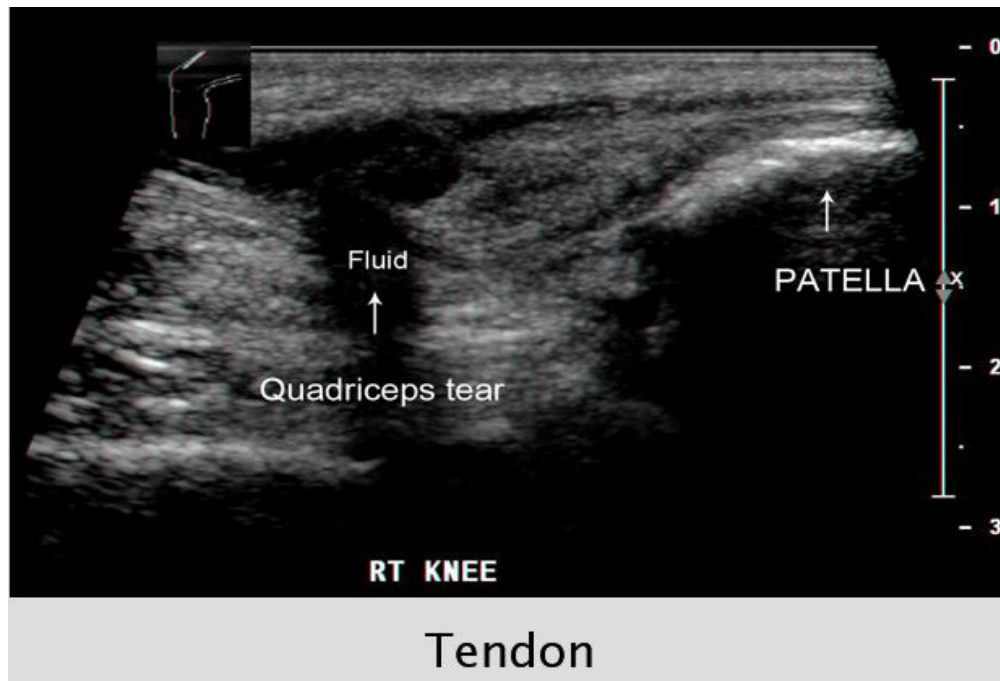


Figure 19: quadriceps tears.

Sonographic examination of the knee has been proposed as a simple and reliable method for diagnosis of Osgood-Schlatter (Figure 20).

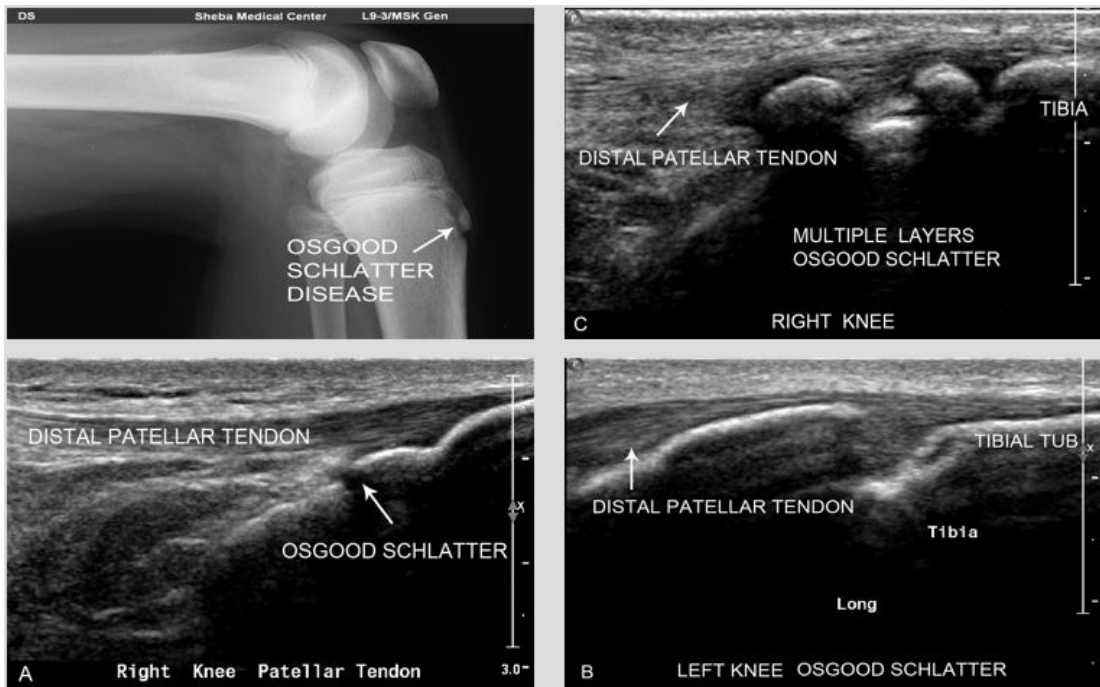


Figure 20: Osgood-Schlatter.

Disease [37] patella bipartite and exostosis (Figures 21,22) [35].

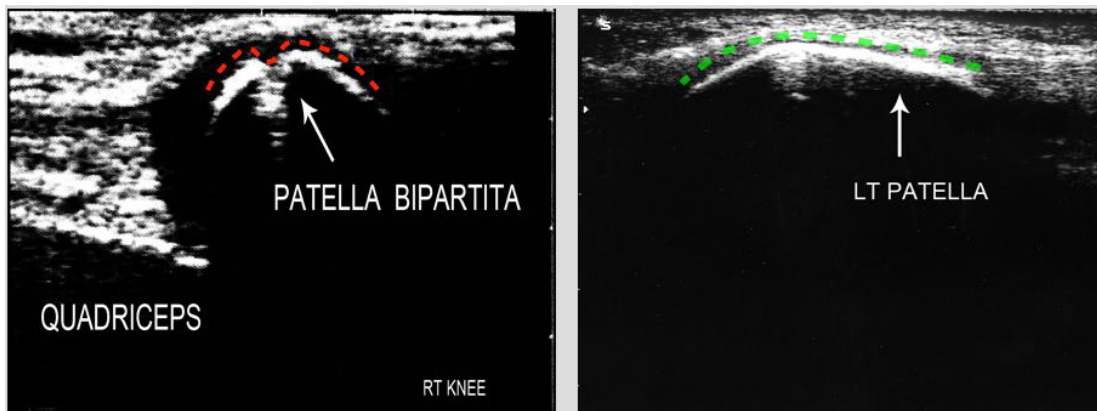


Figure 21: Patella Bipartita.

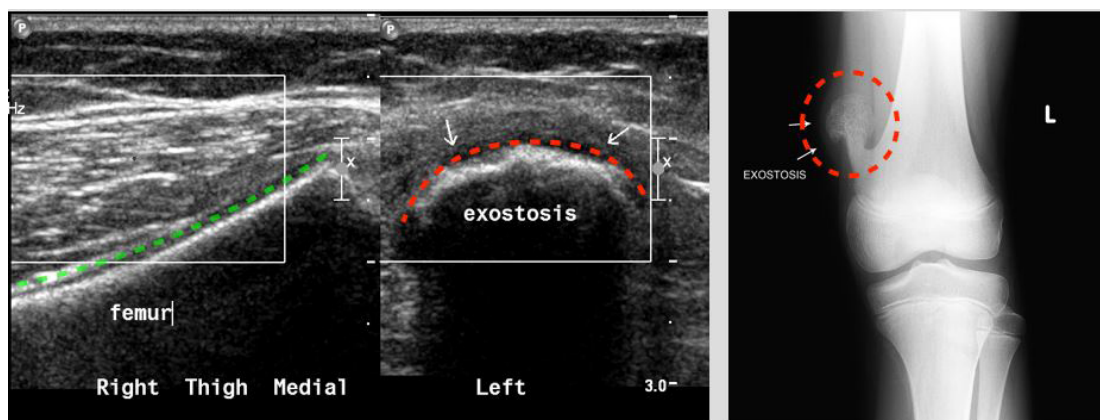


Figure 22: Exostosis medial distal femur.

In Medial Collateral Ligament (MCL) injury, the combination of sonographic findings with those from a real time sonography valgus stress test can support the clinical diagnosis of an MCL stretch or tear, and pinpoint the exact location of the isolated MCL injury, thus facilitating proper treatment (Figure 23), [38,39].

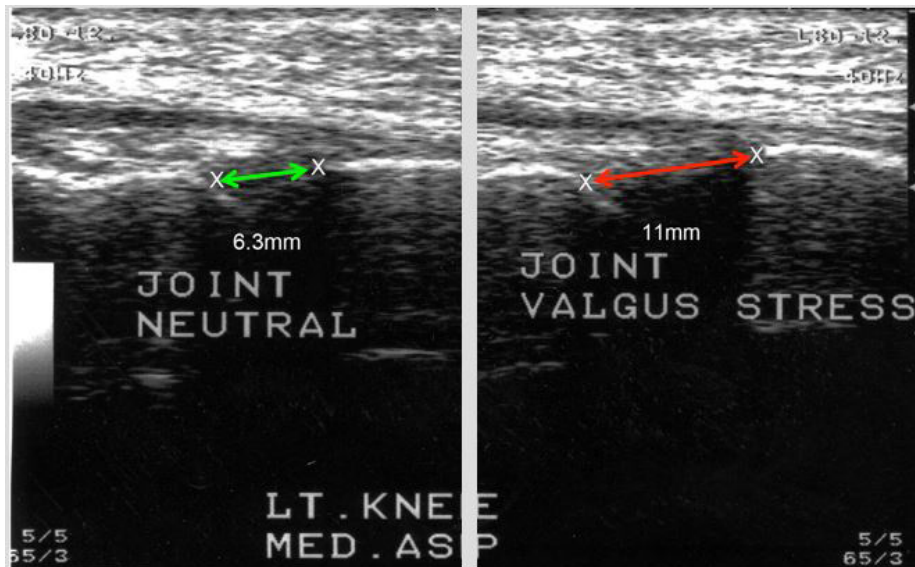


Figure 23: Valgus stress test LT knee.

Ultrasound can suggest an early diagnosis of osteoarthritis (Figure 24).

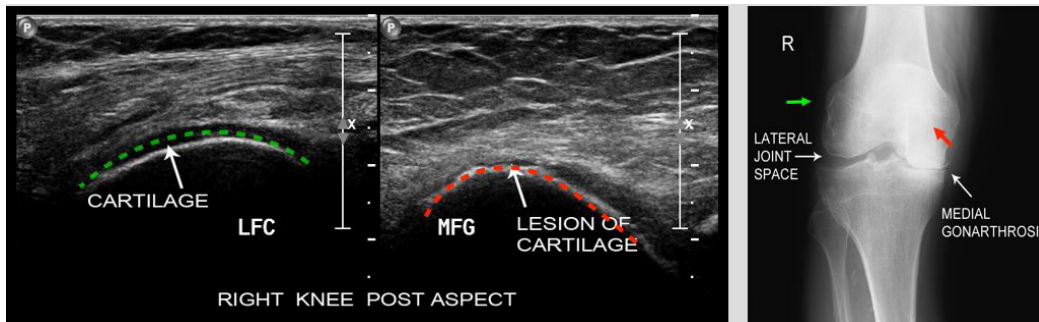


Figure 24: Gonarthrosis RT knee, note severe narrowing medially.

By demonstrating joint effusion, synovial thickening, bony changes, patello femoral changes, articular cartilage changes, peripheral tears and lesions of the tendon, and meniscal pathologies (Figure 25).

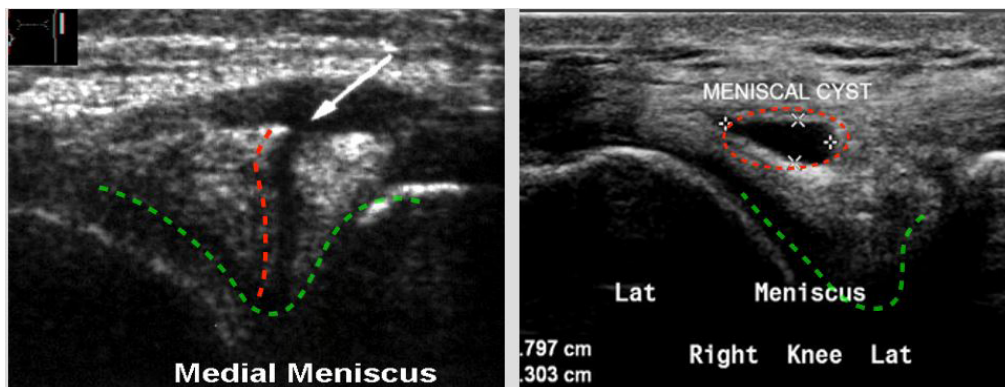


Figure 25: Meniscal pathologies.

Such as meniscal cysts, and Baker cyst [40]. Pathologies can be detected by ultrasound at a stage in which plain radiographs still appear normal. Muscle and ligament pathology, and tumors of the tibial tuberosity can be diagnosed [41], as well as fractures of the patella (Figure 26), [42,43].

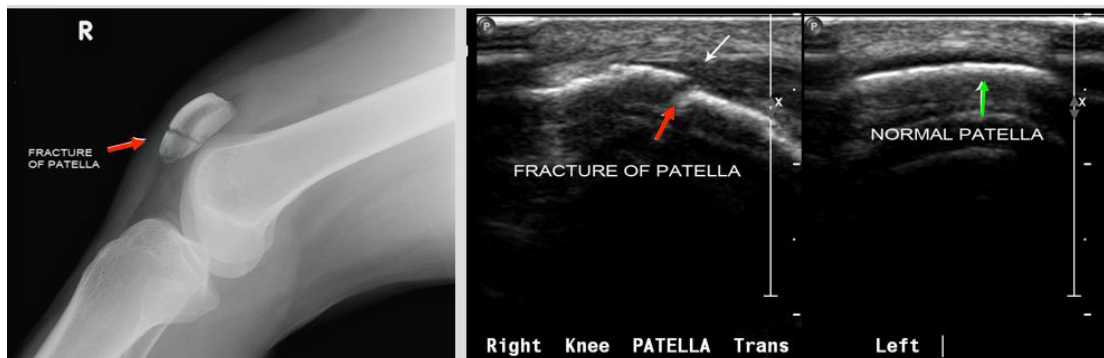


Figure 26: Fractures of the patella.

Hip And Thigh

Ultrasound is used in the evaluation of painful hip (Figure 27).

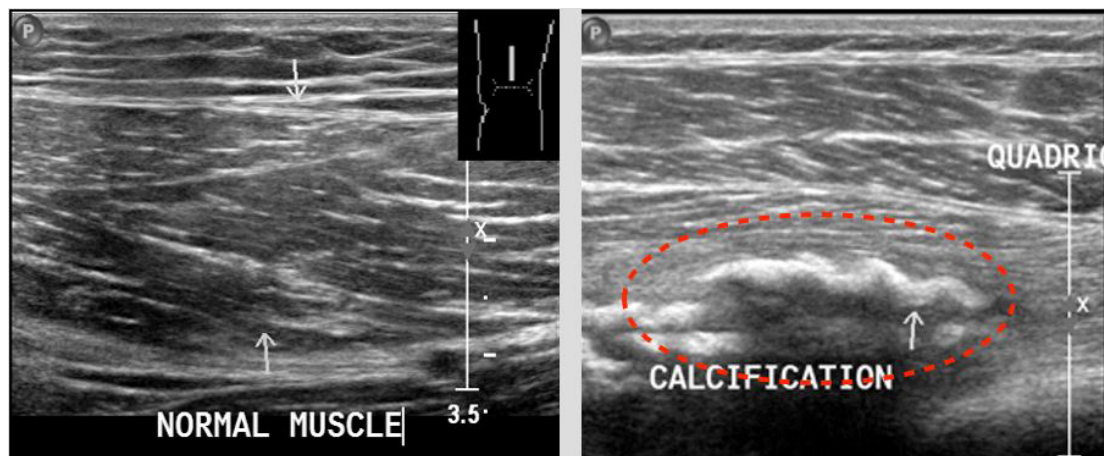


Figure 27: Myositis ossifications.

Assessment of joint effusion and synovial proliferation is an important indication for sonography of the hip. Tear, tendinopathy, hematomas, and inguinal hernia can be assessed. Ultrasound of the thigh can demonstrate soft tissue masses, myositis, ossifications, muscle or tendon injuries, and trochanteric bursitis (Figures 28-30).

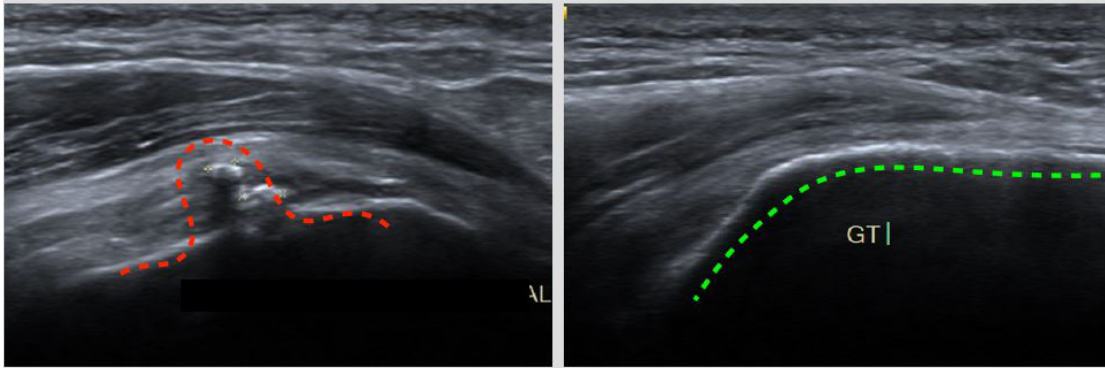


Figure 28: Calcified bursitis LT greater trochanter.

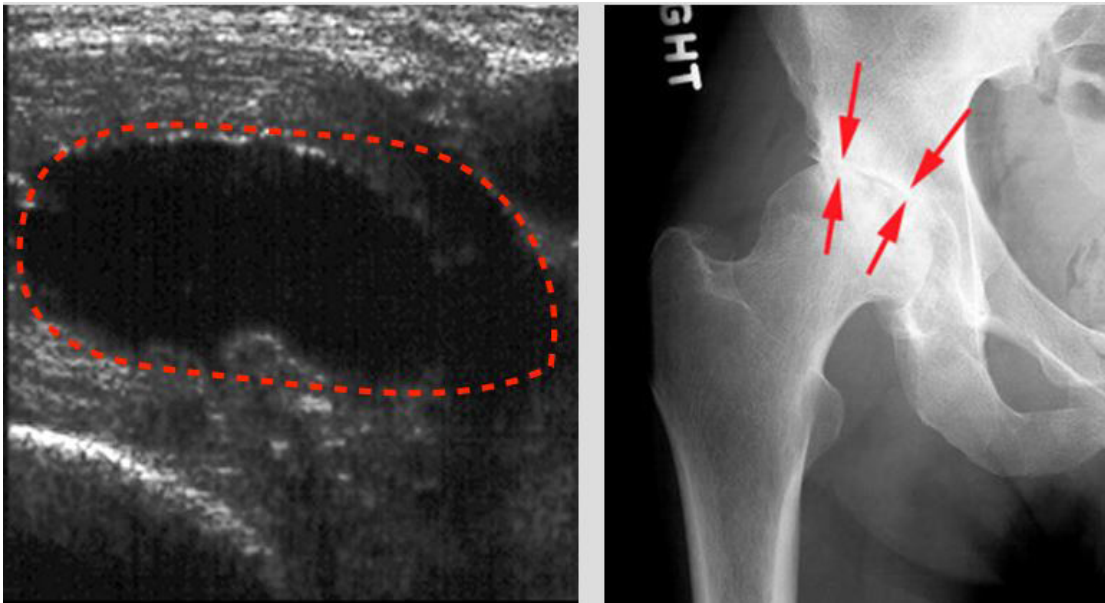
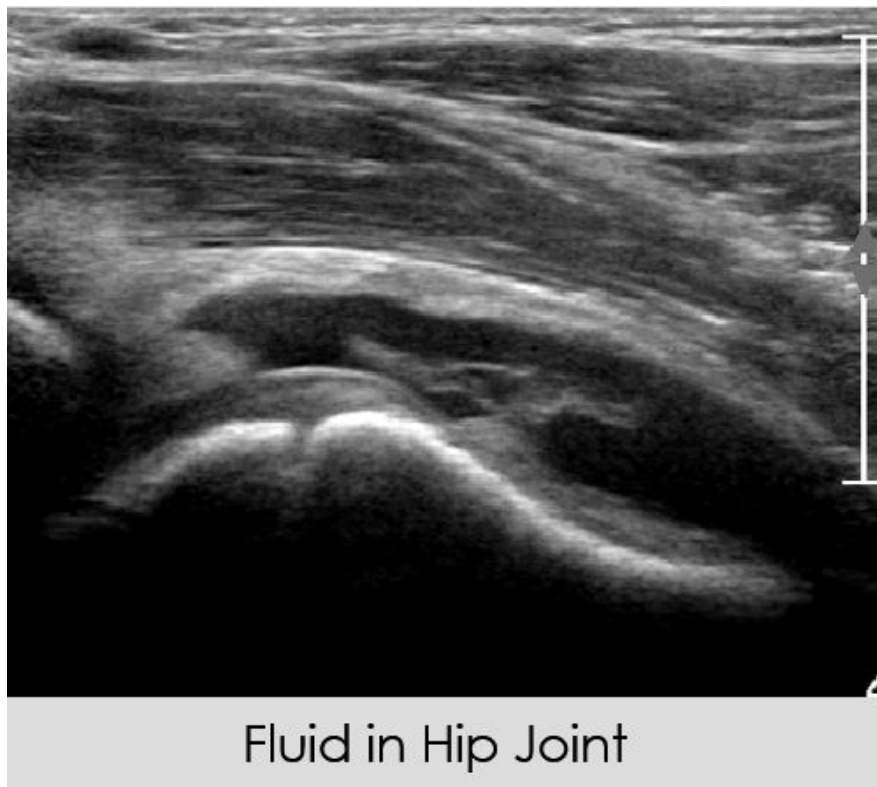


Figure 29: Arthritis of hip joint.



Fluid in Hip Joint

Figure 30: Fluid in hip joint.

The greater trochanter is a prominent palpable landmark for the lateral hip. on examination usually the R.O.M of the hips is normal in all directions. There is a local tenderness proximal and distally to the trochanter. On X- ray there are osteophytes over the greater trochanters. On u.s examination there is swelling of soft tissue with fluid, irregularity of the bone surface and distended trochanteric bursa.

Leg-Foot

Ultrasound can provide a dynamic assessment of muscle tear, or of an intermittent muscle hernia or tendon subluxation. As with other soft tissue lesions, ultrasonography is useful for the evaluation of underlying pathologies in patients presenting with achillodynia and ankle pain. The Achilles tendon is the tendon most commonly evaluated in the leg and may be associated with a wide range of pathologies, including tendonosis, tears, calcification, and inflammations (Figures 31,32) [44,45].

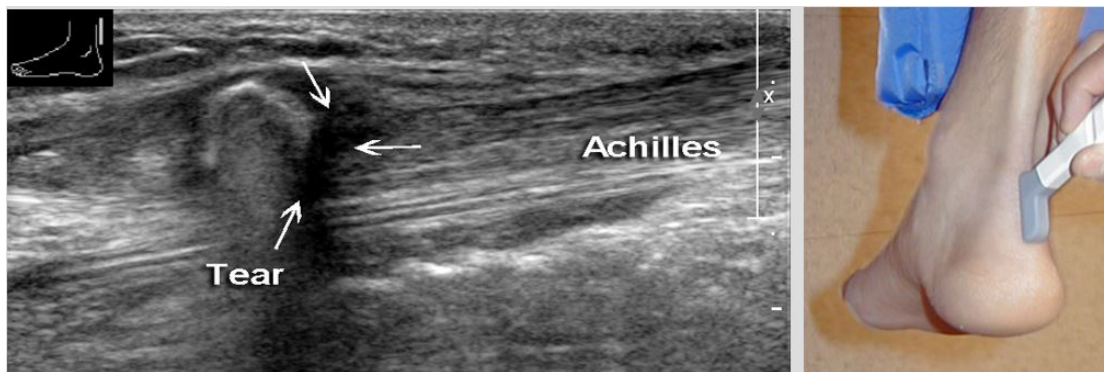


Figure 31: Tear of achilles.

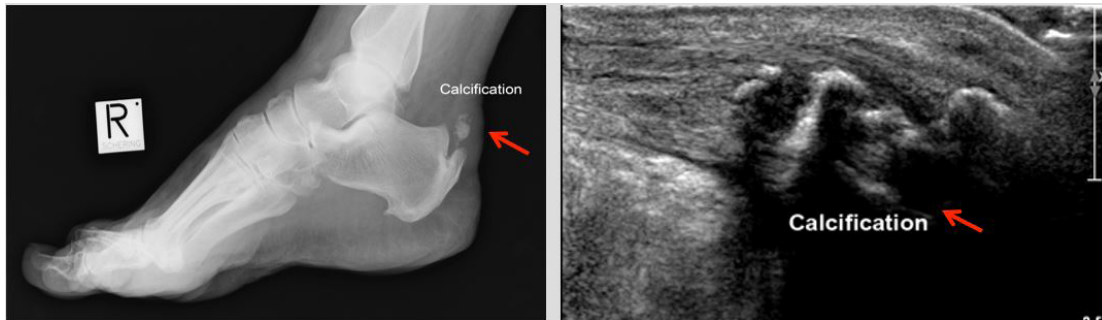


Figure 32: Calcification of RT Achilles tendon.

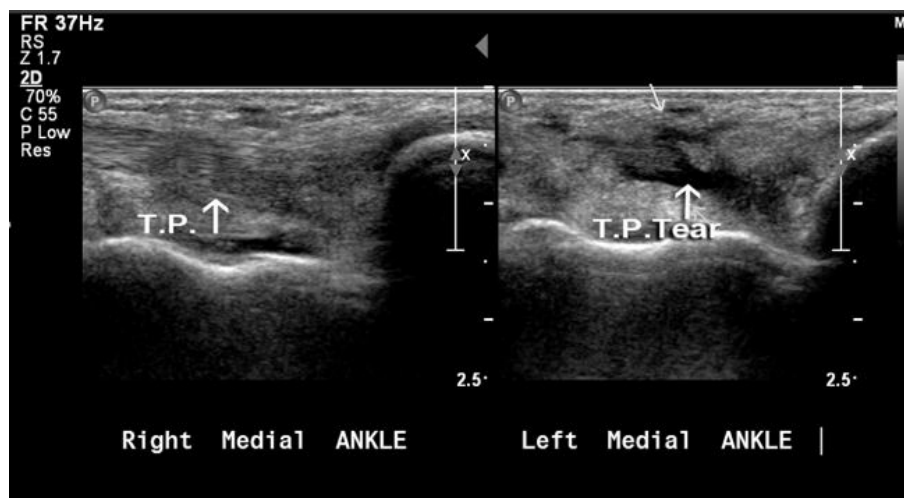


Figure 33: Tibialis posterior tear LT.

Haglund deformity may be related to Achilles tendon pathology. The dynamic nature of the ultrasound examination enables tendon movement and visualization from the origin to the insertion of a tendon, as is needed in the evaluation of the Achilles tendon. Diseases of the Achilles tendon include a broad spectrum of pathologies ranging from paratendonitis to complete tendon ruptures. Tendonitis appears as fusiform swelling with hypoechoogenicity and, tears and gaps can be measured. Ultrasound examination can detect shrapnel lesions and contribute to the planning of surgical correction of ruptures in the Achilles tendon [46]. Ultrasound is also useful for diagnosing such pathologies of the ankle as tendon and ligament ruptures, and inflammation of the tendon sheath [43,47-49]. Ankle sprain can demonstrate partial or complete tears. The most common torn ankle ligament is the anterior talofibular.

Lesion of the ATT are not frequently reported in the international literature although pathology is not rare (Figures 34,35).

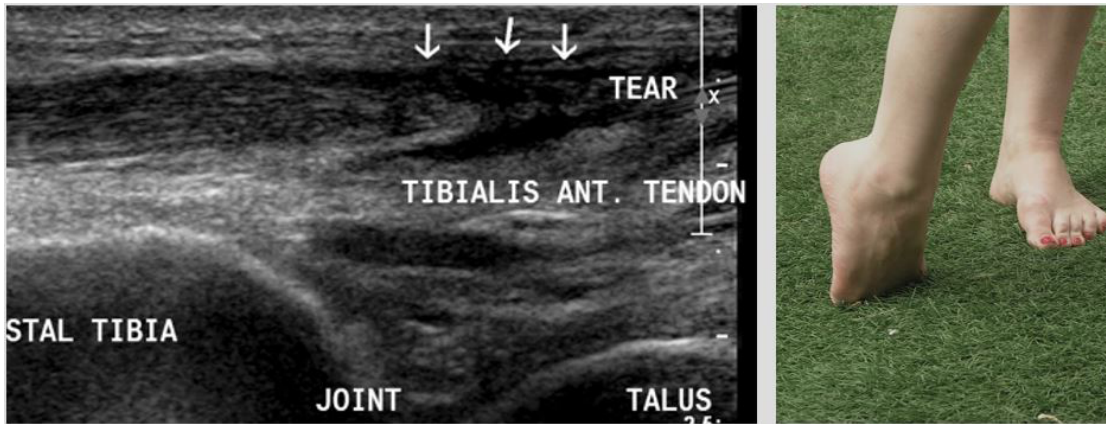


Figure 34: Tibialis anterior tear

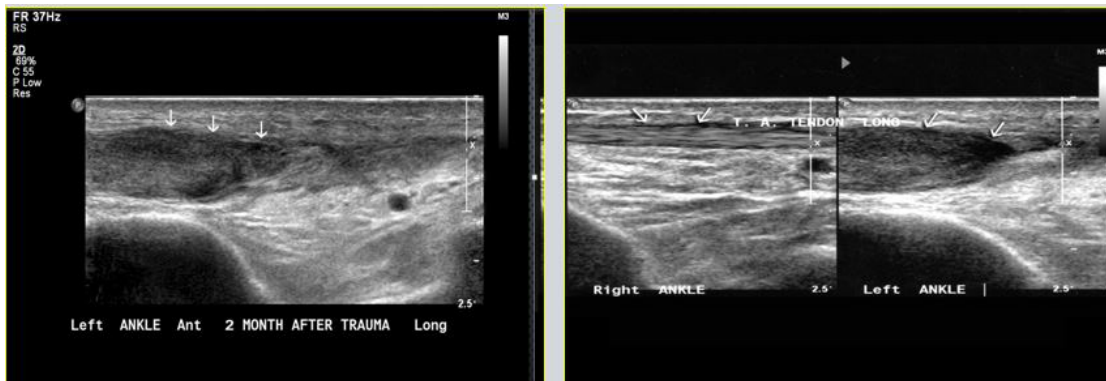


Figure 35: Repair of tib. Ant. Left.

The symptoms can be spontaneous or connected with trauma, arthropathy or other conditions. Clinical examination may not be sufficient for differential diagnosis like tendinopathy, tears bursitis, etc. Ultrasonography of the ankle is a well known modality for diagnosing tendon tears and tendon inflammation around the ankle joint. usually the sonographic examination of the ankle is focused on the medial tendons, especially the tibialis posterior tendon and deltoid ligament. On the lateral side the examination checks the peroneal tendons and the ATFL-anterior talo-fibular ligament, respectively. On the posterior aspect the Achilles tendon is evaluated. the tendons on the anterior aspect of the ankle, especially tibialis anterior tendon sometimes does not get the same attention as the tendon and ligaments mentioned before. Tibialis anterior tendon rupture is a rare entity, with spontaneous tear being the most common etiology, often secondary to diabetes mellitus, hyperparathyroidism, gout, and also after local injection of corticosteroids. Diagnosis is often delayed because dorsiflexion of the foot is able to be performed by both the extensor digitorum longus and extensor hallucis longus. Since anterior tibialis tendon tear occurs rarely. Its clinical manifestations are not always clear cut [50].

Ultrasonography of the tibialis anterior tendon can be used for diagnosing and follow up of ATT tears. Complete evaluation of tibialis anterior tendon should be a crucial part of the sonographic examination of the ankle. Ligaments may appear hypoechoic with fluid, or discontinuous. Similarly, ultrasound allows the appearance of the calcaneo fibular and deltoid ligaments to be seen. The sonographic appearance of rough fragmentation with saw-teeth appearance is a specific sign which has demonstrated effectiveness in the evaluation of Sever's disease [51]. Sonography can be effective in evaluating cases of tibial stress fractures [52]. Routine ultrasound examination includes the anterior tibial, posterior tibial, peroneal and Achilles tendon and the tibiotalar joint is evaluated for effusion or loose bodies. Tendinitis is visualized in ultrasound as hypoechoogenicity of the tendon with increased interfibrillar distance. Retro-calcaneal bursitis and cellulitis can be seen. Partial tears indicate intrasubstance defects extending toward one surface of the tendon. Tendon discontinuity may indicate the proximal and distal stumps of the tendon. Insertion tendinopathy is seen as a hypoechoic enlargement of the tendon with fluid in the area inserted in the bone. Ultrasound is helpful in evaluating any syndesmosis, as is needed in post traumatic anterior ankle pain and in detecting foreign bodies in the ankle (Figures 36,37).

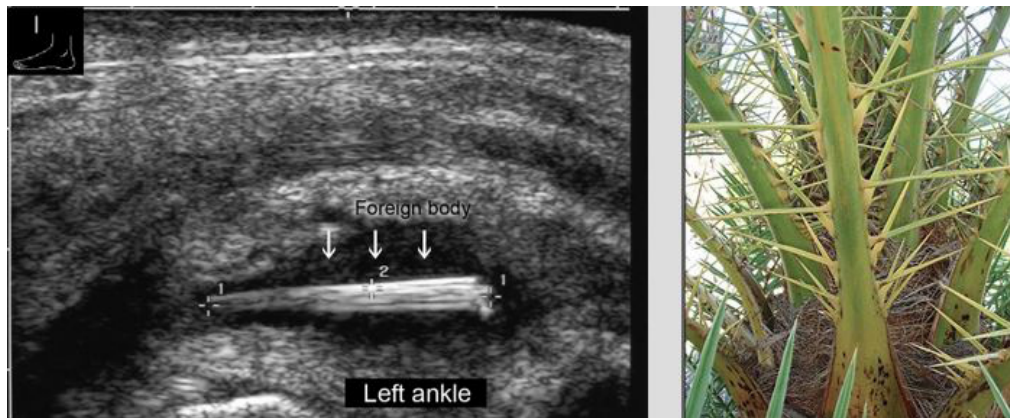


Figure 36: Foreign body injury ankle with a palm tree thorn.

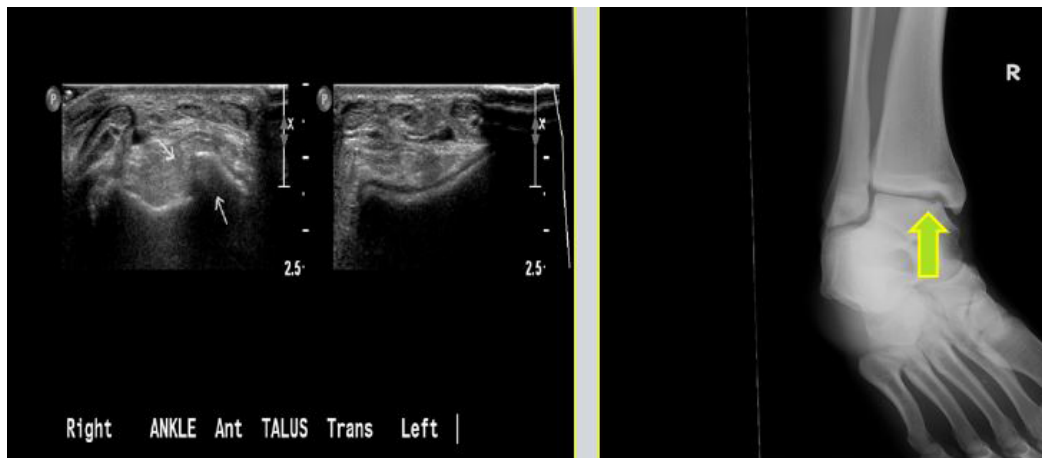


Figure 37: Osteochondritis of talus.

Post traumatic tibio-fibular synostosis is a rare complication of tibial and ankle fractures and can be diagnosed with u.s. distal tibio-fibular synostosis is the most common. Ultrasound is useful in the assessment of foot lesions such as plantar fasciitis, plantar fascial tears, fibromatosis, morton neuroma, Jones fractures, and fractures of sesamoids and the 5th metatarsal bone [53]. Plantar fasciitis is a disorder of connective tissue that supports the longitudinal arch of the foot. The fascia runs along the sole with insertion to the heads of the metatarsal bones and origin in the calcaneus (Figure 38).

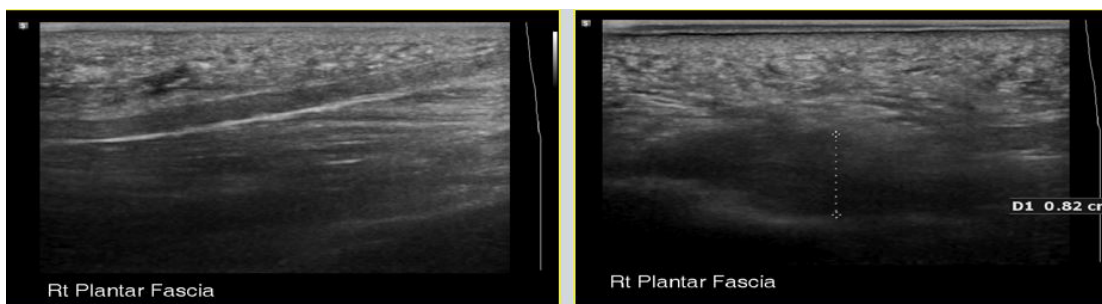


Figure 38: Plantar fascia.

This is a common cause for heel pain, when may develop into chronic heel pain changes the way we walk and lead to foot, knee, hip or back problems. The palmar fascia is a common source of symptoms. On u.s examination ,we can access the fascia with its narrow attachment to the calcaneus, tears, or fibroma or plantar fasciitis with widening and fluid accumulation near the calcaneus [54].

Hip Pathology In Children

Only rarely can a small effusion of the hip joint be detected by clinical examination. Thus, ultrasound, with its effectiveness in detecting effusion and synovitis, is generally used in the early assessment of hip pathology [55]. Detection of an effusion allows direct aspiration to decrease the pressure and to evaluate the fluid for possible septic arthritis [56]. Prompt aspiration in suspected cases of septic arthritis obviates the need for lengthy workups, and guides further treatment [57]. Further, ultrasound can be used to visualize fragmentation of the femoral head in “Perthes disease”[58], and to detect a slipped capital femoral epiphysis [59].

Developmental Dysplasia Of The Hip (Ddh)

Clinical assessment of the newborn hip is routinely performed in the first days of life. Static and dynamic scanning by ultrasound enhances the rate of early detection of hip abnormalities [60]. Ultrasound follow-up is part of the routine management of hip dysplasia.

Bone and Muscles Pathology

Assessment of the echogenic surface of bone and the acoustic shadow behind it can reveal abnormalities. Although sonography is not generally the examination of choice for the diagnosis of bone pathology, it should not be ignored, since significant pathologies, including fractures, bone erosions and lytic lesions, are occasionally detected. Ultrasound can be used to detect subperiosteal collections of fluid in early osteomyelitis, as well as fractures [61], osteophyte, and bone tumors with bone damage. It provides excellent anatomical detail of the cortical surface of superficial bone. In cases of exostosis, it may be used to measure the thickness of the cartilage cap. The use of ultrasound for the diagnosis of fractures is gaining more and more interest. When ultrasound evaluation is targeted and combined with an orthopedic examination of the pathological area, precise demonstration of cortical disruption, soft tissue damage, and hematoma are possible. Knowledge of bone anatomy is essential for complete ultrasound evaluation of the musculoskeletal system. Muscle pathologies such as rupture, calcification, myositis ossificans, hemorrhage can be also assessed by ultrasound.

Musculoskeletal Ultrasound In Rheumatology

During recent years, musculoskeletal ultrasound has become recognized as an effective imaging technique for the diagnosis and follow-up of patients with rheumatic diseases [62-67]. While most commonly used in the assessment of soft tissue disease or detection of fluid collection, ultrasound can also be used to visualize other structures, such as cartilage and bone surfaces

[62,68,69]. In patients who have rheumatoid arthritis u.s is a very good modality for detection of early bone erosions in the hand and finger. They are oval or rounded, well defined cortical breaks with an irregularity of the bone surface. Hypoechoic synovial tissue and doppler signal with hypervascularity is detectable. There is a loss of articular cartilage and widening of the joint space.

Conclusion

Ultrasound is a safe and painless way of using sound waves to look at parts of the human anatomy, and allow us to move around during the procedure and focus on the exact location of the patient pain, and find how motion effects the area of the pathology. Contralateral comparison can help to distinguish significant finding from variation of normal. Compression by applying pressure under real time visualization can reveal important information about the composition of the structure. Color or power Doppler features show the degree of vascularity associated with inflammatory process. The main drawback of musculo skeletal U.S remain the strong operator dependence. Ultrasound is an invaluable diagnostic technique in orthopedic practice. Technological developments in resolution quality have increased the diagnostic possibilities while improvements in picture quality have increased clinical applications. Musculoskeletal sonography is safer and more informative than X-rays for evaluating soft tissues pathology. Compared with MRI, it is accessible to all patients, without contraindications, and provides real time dynamic assessment.

Musculoskeletal ultrasonography is indicated for evaluation of soft tissue damage, particularly in sports injuries. The most practical uses are the evaluation of tendon structures, dynamic examination in motion, and the assessment of articular structures and diseases. Bursal disease with synovitis can be easily detected. Ultrasound should be performed when investigating rotator cuff tears, inflammation, calcific tendinitis and impingement syndrome, frozen shoulder, tennis or golfer elbow, biceps muscle, and distal biceps tendon insertion. Other indications include carpal tunnel syndrome, cysts of the wrists, pathology of tendon of the hands, retained foreign bodies, joint effusion, diseases of the knee, meniscal cysts, Baker cyst, ligament and osteoarthritis changes, Osgood Schlatter, and patella bipartite. In the ankle, ultrasound can detect tibio talar effusion, pathology of tibialis anterior, posterior, peroneal tendons, Achilles tendon, plantar fasciitis, and Morton neuroma. Musculoskeletal sonography should be performed by an experienced operator with extensive knowledge of anatomy. Investment in training is justified in light of the contribution of this technology to diagnostic and therapeutic orthopedics and its accessibility to patients due to safety, non- ionizing radiation, low operating costs, lack of contraindications, and availability in locations distant from medical centers.

It is a quick and effective imaging tool that can be utilized by orthopedic and other doctors to identify common musculoskeletal pathology. It becomes a standard tool to help physicians in orthopedic and sports medicine. Ultrasonography is totally safe, and does not emit ionizing radiation. In today’s world, ionizing radiation is present in all spheres of life,

including industrial radiography, medical radiology and nuclear medicine, Uranium mining, Nuclear power plant, nuclear fuel reprocessing workers and Research laboratories. Radiation and radioactive substances are used for diagnosis, treatment and research. All modern communication systems use forms of electromagnetic radiation. Exposure to radiation causes damage to living tissue, and high doses can result in mutation, radiation sickness, cancer and death. We are developing safe and cost effective modality without exposing the patient if possible to dangerous ionizing radiation and help patient get faster diagnosis and treatment. Given all this work has helped and will help mankind in the future.

References

1. Dudkiewicz I, Ganel A, Blankstein A (2005) Congenital muscular torticollis in infants: ultrasound-assisted diagnosis and evaluation. *J Pediatr Orthop* 25: 812-814.
2. Kleinbaum Y, Heyman Z, Ganel A, Mirovski Y, Blankstein A (2004) Detection of greater tuberosity fractures by sonography. *J Musculoskeletal Res* 8: 102-105.
3. Blankstein A, Ganel A, Diamant L, Chechick A (2008) Cervical rib--preliminary data on diagnosis by ultrasound. *Ultraschall Med* 29: 286-288.
4. Blankstein A, Ganel A, Salai M, Cohen I, Heim M, Diamant L, Chechick A (2001) Fracture of the clavicle in the newborn - Detection and follow-up by sonography. *Akt Traumatol* 31: 27-29.
5. Blankstein A, Dudkiewicz I, Givon U, Ganel A (2004) Ultrasonographic imaging of congenital pseudoarthrosis of the clavicle. *Akt Traumatol* 34: 234-236.
6. Coombs ,Ptaznik R (2016) Sonography of the shoulder Musculo skeletal ultrasound Third edition 2016: 737-733
7. Dudkiewicz I, Blankstein A (2006) Ultrasonography: A highly efficient modality for diagnosis of Hill-Sachs lesions. *Akt Traumatol* 36: 29-31.
8. Blankstein A, Ganel A, Dudkiewicz I, Givon U, Mirovski Y, Adunsky A (2004) Ultrasonographic imaging in hemiplegic shoulders of stroke patients. *Akt Traumatol* 34: 132-135.
9. Boehm TD, Kirschner S, Mueller T, Sauer U, Gohlke FE (2005) Dynamic ultrasonography of rotator cuff muscles. *J Clin Ultrasound* 33: 207-213.
10. Drakeford MK, Quinn MJ, Simpson SL, Pettine KA (1990) A comparative study of ultrasonography and arthrography in evaluation of the rotator cuff. *Clin Orthop Relat Res* 1990: 118-122.
11. Blankstein A, Ganel A, Givon U, Dudkiewicz I, Perry M, Diamant L, Chechick A (2005) Ultrasonography as a diagnostic modality in acromioclavicular joint pathologies. *Isr Med Assoc J* 7: 28-30.
12. Blankstein A, Nerubay J, Lin E, Keren G, Friedman B, Horoszowski H (1986) Septic arthritis of the sternoclavicular joint. *Orthop Rev* 15: 440-442.
13. Blankstein A, Amsellem JL, Rubinstein E, Horoszowski H, Farin I (1985) Septic arthritis of the acromioclavicular joint. *Arch Orthop Trauma Surg* 103: 417-418.
14. Blankstein A, Heyman Z, Yitzchak Y (1995) [Ultrasound examination of the shoulder] *Harefuah* 128: 441-444.
15. van Holsbeeck MT, Kolowich PA, Eyler WR, Craig JG, Shirazi KK, Habra GK, Vanderschueren GM, Bouffard JA (1995) US depiction of partial-thickness tear of the rotator cuff. *Radiology* 197: 443-446.
16. Farin PU, Jaroma H. Acute traumatic tears of the rotator cuff: value of sonography. *Radiology*. 1995;197:269-273.
17. Teefey SA, Hasan SA, Middleton WD, Patel M, Wright RW, Yamaguchi K (2000) Ultrasonography of the rotator cuff. A comparison of ultrasonographic and arthroscopic findings in one hundred consecutive cases. *J Bone Joint Surg Am* 82: 498-504.
18. Blankstein A, Mirovski Y, Givon U, Chechick A, Adunsky A, Ganel A (2004) Ultrasonographic diagnosis in the evaluation of shoulder pain. *J Musculoskeletal Res* 8: 195-200.
19. Middleton WD, Teefey SA, Yamaguchi K (1998) Sonography of the Shoulder. *Semin Musculoskelet Radiol* 2: 211-222.
20. van Holsbeeck MT (2001) Sonography of the elbow, wrist and hand. In: van Holsbeeck MT, Introcaso JH, eds , editors. *Musculoskeletal Ultrasound*. St Louis: Mosby 2001: 517-571.
21. Martinoli C, Bianchi S, Giovagnorio F, Pugliese F (2001) Ultrasound of the elbow. *Skeletal Radiol* 30: 605-614.
22. Levin D, Nazarian LN, Miller TT, O'Kane PL, Feld RI, Parker L, McShane JM (2005) Lateral epicondylitis of the elbow: US findings. *Radiology* 237: 230-234.
23. Blankstein A, Ganel A, Givon U, Mirovski Y, Chechick A (2006) Ultrasonographic findings in patients with olecranon bursitis. *Ultraschall Med* 27: 568-571.
24. Blankstein A, Chechick A, Adunski A, Givon U, Mirovski Y, Ganel A (2005) Characteristics of soft tissue mass in the hand by ultrasonographic examination. *J Musculoskeletal Res* 9: 45-51.
25. Cardinal E, Buckwalter KA, Braunstein EM, Mih AD (1994) Occult dorsal carpal ganglion: comparison of US and MR imaging. *Radiology* 193: 259-262.
26. Dias JJ, Dhukaram V, Kumar P (2007) The natural history of untreated dorsal wrist ganglia and patient reported outcome 6 years after intervention. *J Hand Surg Eur Vol* 32: 502-508.
27. Blankstein A, Cohen I, Heiman Z, Salai M, Diamant L, Heim M, Chechick A (2001) Ultrasonography as a diagnostic modality and therapeutic adjuvant in the management of soft tissue foreign bodies in the lower extremities. *Isr Med Assoc J* 3: 411-413.
28. Blankstein A, Cohen I, Heiman Z, Salai M, Heim M, Chechick A (2000) Localization, detection and guided removal of soft tissue in the hands using sonography. *Arch Orthop Trauma Surg* 120: 514-517.
29. Cohen E, Blankstein A, Rosenstock M, Atar D (2000) Greenstick fractures of distal radius followed-up by ultrasound - A prospective study. *Akt Traumatol* 30: 227-229.
30. Kleinbaum Y, Heyman Z, Ganel A, Blankstein A (2005) Sonographic imaging of mallet finger. *Ultraschall Med* 26: 223-226.
31. Blankstein A (2016) Sonography of the knee and lower limb. *Musculo skeletal ultrasound Third edition 2016: 996-997*.
32. Siev-Ner I., Stern M., Tenenbaum S., Blankstein A (2018) Ultrasonography finding and physical examination outcomes in dancers with and without patellofemoral pain. *The physician and sports medicine* 2018: 1-8
33. Friedman L, Finlay K, Popovich T, Chhem RK (2003) Sonographic findings in patients with anterior knee pain. *J Clin Ultrasound* 31: 85-97.
34. Dudkiewicz I, Blankstein A (2006) Ultrasonography: A highly efficient modality for anterior knee pain diagnosis. *Akt Traumatol* 36: 180-182.
35. Blankstein A, Ganel A, Mirovsky Y, Chechick A, Dudkiewicz I (2006) Early diagnosis of generalized knee pain and osteoarthritis by

- ultrasound. *Akt Traumatol* 36: 175-179.
36. Azzoni R, Cabitza P (2002) Is there a role for sonography in the diagnosis of tears of the knee menisci? *J Clin Ultrasound* 30: 472-476.
 37. Blankstein A, Cohen I, Heim M, Diamant L, Salai M, Chechick A, Ganel A (2001) Ultrasonography as a diagnostic modality in Osgood-Schlatter disease. A clinical study and review of the literature. *Arch Orthop Trauma Surg* 121: 536-539.
 38. Blankstein A, Cohen I, Salai M, Diamant L, Chechick A, Ganel A (2001) Ultrasonography: an imaging modality enabling the diagnosis of bipartite patella. *Knee Surg Sports Traumatol Arthrosc* 9: 221-224.
 39. Kleinbaum Y, Blankstein A (2008) Mild to moderate medial collateral ligament (MCL) injuries of the knee: sonographic findings and sonographic valgus stress test. *J Musculoskeletal Res* 11: 9-14.
 40. Ward EE, Jacobson JA, Fessell DP, Hayes CW, van Holsbeeck M (2001) Sonographic detection of Baker's cysts: comparison with MR imaging. *AJR Am J Roentgenol* 176: 373-380.
 41. Bruck N, Sherr-Lurie N, Ganel A, Blankstein A (2003) Tumours of the tibial tuberosity in children. *Akt Traumatol* 33: 300-301.
 42. Bianchi S, Zwass A, Abdelwahab IF, Banderli A (1994) Diagnosis of tears of the quadriceps tendon of the knee: value of sonography. *AJR Am J Roentgenol* 162: 1137-1140.
 43. Bianchi S, Martinoli C, Gaignot C, De Gautard R, Meyer JM (2005) Ultrasound of the ankle: anatomy of the tendons, bursae, and ligaments. *Semin Musculoskelet Radiol* 9: 243-259.
 44. Blankstein A, Israeli A, Dudkiewicz I, Chechik A, Ganel A (2007) Percutaneous Achilles tendon repair combined with real-time sonography. *Isr Med Assoc J* 9: 83-85.
 45. Blankstein A, Cohen I, Diamant L, Heim M, Dudkiewicz I, Israeli A, Ganel A, Chechick A (2001) Achilles tendon pain and related pathologies: diagnosis by ultrasonography. *Isr Med Assoc J* 3: 575-578.
 46. Blankstein A, Heyman Z, Salai M, Yitzchak Y, Horoszowski H (1995) Shrapnel lesion of the Achilles tendon: Diagnosis by ultrasonography. *Eur J of Ultrasound* 2: 219-221.
 47. Peetrans P, Creteur V, Bacq C (2004) Sonography of ankle ligaments. *J Clin Ultrasound* 32: 491-499.
 48. Jacobson JA, Andresen R, Jaovisidha S, De Maeseneer M, Foldes K, Trudell DR, Resnick D (1998) Detection of ankle effusions: comparison study in cadavers using radiography, sonography, and MR imaging. *AJR Am J Roentgenol* 170:1231-123
 49. Khoury V, Guillin R, Dhanju J, Cardinal E (2007) Ultrasound of ankle and foot: overuse and sports injuries. *Semin Musculoskelet Radiol* 11: 149-161.
 50. Blankstein A (2022) Tibialis anterior tendon rupture evaluation and follow up by ultrasonography. *J. of Musculoskeletal Res.*
 51. Kleinbaum Y, Ganel A, Blankstein A (2006) Ultrasonography as a diagnostic modality in Sever's disease (calcaneal apophysitis) *Akt Traumatol* 36: 294-297
 52. Farkash U, Naftal J, Deranze E, Blankstein A (2008) Ultrasonography as a diagnostic modality of tibial stress fractures. *J Musculoskelet Res*11: 55-61.
 53. Dudkiewicz I, Singh D, Blankstein A (2005) Missed diagnosis fracture of the proximal fifth metatarsus – The role of ultrasound. *Foot and Ankle Surg* 11: 161-166.
 54. Held R., Blankstein A (2021) Plantar Fasciitis: A novel crowdsourcing (plantar fasciitis) approach to data collection and analysis. *J. of musculoskeletal Res* Vol 24: 1-11
 55. Novick GS (1988) Sonography in pediatric hip disorders. *Radiol Clin North Am* 26: 29-53.
 56. Givon U, Liberman B, Schindler A, Blankstein A, Ganel A (2004) Treatment of septic arthritis of the hip joint by repeated ultrasound-guided aspirations. *J Pediatr Orthop* 24: 266-270.
 57. Bickerstaff DR, Neal LM, Booth AJ, Brennan PO, Bell MJ (1990) Ultrasound examination of the irritable hip. *J Bone Joint Surg Br* 72: 549-553.
 58. Terjesen T. (1993) Ultrasonography in the primary evaluation of patients with Perthes disease. *J Pediatr Orthop* 13: 437-443.
 59. Terjesen T (1992) Ultrasonography for diagnosis of slipped capital femoral epiphysis. Comparison with radiography in 9 cases. *Acta Orthop Scand* 63: 653-657.
 60. Rosendahl K, Markestad T, Lie RT, Sudmann E, Geitung JT (1995) Cost-effectiveness of alternative screening strategies for developmental dysplasia of the hip. *Arch Pediatr Adolesc Med* 149: 643-648.
 61. Tomer K, Kleinbaum Y, Heyman Z, Dudkiewicz I, Blankstein A (2006) Ultrasound diagnosis of fractures in adults. *Akt Traumatol* 36: 171-174.
 62. Backhaus M, Burmester GR, Gerber T, Grassi W, Machold KP, Swen WA, Wakefield RJ, Manger B (2001) Guidelines for musculoskeletal ultrasound in rheumatology. *Ann Rheum Dis* 60: 641-649.
 63. Gibbon WW, Wakefield RJ (1999) Ultrasound in inflammatory disease. *Radiol Clin North Am* 37: 633-651.
 64. Grassi W, Cervini C (1998) Ultrasonography in rheumatology: an evolving technique. *Ann Rheum Dis* 57: 268-271.
 65. Wakefield RJ, Gibbon WW, Emery P (1999) The current status of ultrasonography in rheumatology. *Rheumatology (Oxford)* 38: 195-198.
 66. Manger B, Kalden JR (1995) Joint and connective tissue ultrasonography--a rheumatologic bedside procedure? A German experience. *Arthritis Rheum* 38:736-742.
 67. Manger B, Backhaus M (1997) [Ultrasound diagnosis of rheumatic/inflammatory joint diseases] *Z Arztl Fortbild Qualitatssich* 1: 341-345.
 68. Grassi W, Tittarelli E, Pirani O, Avaltroni D, Cervini C (1993) Ultrasound examination of metacarpophalangeal joints in rheumatoid arthritis. *Scand J Rheumatol* 22: 243-247.
 69. Grassi W, Lamanna G, Farina A, Cervini C (1999) Sonographic imaging of normal and osteoarthritic cartilage. *Semin Arthritis Rheum* 28: 398-403.