



Research Article

Penile Preserving and Reconstructive Surgery: The Initial Experience with Scrotal Flap in the Management of Penile Cancer

Venturini B¹, Zacché B², Frasson PL³, Borges CF¹, Prado R¹, Faber N¹, Rocha WS¹, Bechara GR^{1*}

¹Department of Urology, Federal University of Espírito Santo, Vitória, ES, Brazil

²Urology Residency Program, Federal University of Espírito Santo, Vitória, ES, Brazil

³Department of Plastic Surgery, Federal University of Espírito Santo, Vitória, ES, Brazil

*Corresponding author: Gustavo Ruschi Bechara, Department of Urology, Hospital Universitário Cassiano Antônio de Moraes, HUCAM, Federal University of Espírito Santo (UFES), Av. Marechal Campos - Nazareth, Vitória, ES, Brazil

Citation: Venturini B, Zacché B, Frasson PL, Borges CF, Prado R, et al. (2024) Penile Preserving and Reconstructive Surgery: The Initial Experience with Scrotal Flap in the Management of Penile Cancer. J Surg 9: 11069 DOI: 10.29011/2575-9760.11069

Received Date: 05 June 2024; **Accepted Date:** 10 June 2024; **Published Date:** 12 June 2024

Abstract

Purpose: Organ-Sparing Surgery (OSS) in Penile Cancer (PC) maintains sexual and voiding function, as well as quality of life and psychological well-being. Herein, we describe a reconstructive surgery using a scrotal flap after partial penectomy when there is not enough skin to cover the penile shaft.

Methods: A PubMed search was conducted using the keywords organ sparing/conserving in penile cancer, alone or in combination with partial penectomy; partial penectomy; reconstructive surgery techniques; and surgical flaps to identify OSS techniques. We reconstructed the neoglans with a urethral flap and the penile skin shaft with a scrotal flap at the same time as the surgical resection in 5 patients who underwent partial penectomy for penile Squamous Cell Carcinoma (SCC).

Results: We noted no neomeatal stenosis or flap necrosis secondary to the technique. Surgical wound infection was observed in 1 patient (20%) and was treated with intravenous antibiotic therapy. Surgical wound hematoma was observed in 1 patient (20%) with no need for drainage. At this time, there is no tumor recurrence, and voiding function is preserved. Regarding sexual function, the patients maintain penetration with Phosphodiesterase Type 5 Inhibitors (PDE5) or intracavernous injection.

Conclusion: OSS with a scrotal flap proved to be a safe and viable option for the treatment of localized PC, ensuring a favorable penile appearance, preserving sexual and voiding function, and providing good quality of life and psychological well-being without compromising oncological outcomes.

Keywords: Penile cancer; Partial penectomy; Reconstructive surgery techniques; Scrotum; Surgical flaps

Introduction

Although Penile Cancer (PC) only represents 1% of all male cancers, surgical amputation is the oncological gold standard treatment for the primary tumor of the penis. Radical surgery can be mutilating and devastating for patients, leading to high

physical and psychological morbidity [1]. Organ-sparing surgery (OSS) has become a standard option for the treatment of localized PC, ensuring a favorable penile appearance, preserving sexual and voiding function, and providing good quality of life and psychological well-being [2]. There is no clear evidence about the required width of negative surgical margins, but 3-5 mm can be considered safe according to the literature [3]. Besides that, local recurrence has little influence on long-term survival, so OSS

is recommended [4]. Enhancing the length of the penile stump, using a skin graft to cover the distal corpora, creating a neoglans, or performing a ventral spatulated urethral advancement flap are some of the maneuvers used to restore cosmesis, form, and function [5]. We describe a reconstructive surgery using a scrotal flap after partial penectomy when there is not enough skin to cover the penile shaft.

Materials and Methods

A review was conducted with the search period from 1985 through May 2024 to identify OSS techniques. Initial search terms were organ sparing/conserving in penile cancer alone or in combination with partial penectomy; reconstructive surgery techniques; surgical flaps. We analyzed the clinical and functional evolution in five patients who underwent partial penectomy for Squamous Cell Carcinoma (SCC), followed by reconstructive surgery using a scrotal flap over 12 months. We performed the partial penectomy originally described by Pack and Ariel [6]. The neoglans reconstruction was performed with a urethral flap as described by Belinky JJ et al [7]. The remaining corpora is usually covered with penile shaft skin, but in this case, we decided to use a scrotal skin flap at the same time as the surgical resection, which allowed us to maintain a satisfactory length of the remaining phallus (Figures 1 and 2). A prerequisite to perform this technique was complete tumor excision confirmed by a negative intraoperative frozen section. A demarcation was made on the scrotal raphe with methylene blue, similar in size to the length of the remaining phallus (Figures 1A and 2A). Then, an incision was made along the previous demarcation resulting in a “V” shape (Figures 1B and 2B). Another two demarcations with methylene blue were made on the scrotum. These two lines must be distant from the median raphe by 3 cm or wider, depending on the thickness of the penis. The demarcations will appear as a trapezoidal shape with its smaller base in the scrotum (Figures 1C and 2C). The lines and the smaller base of the trapezoidal shape are then incised to obtain the scrotal flap (Figures 1D and 2D). The scrotal flap should then be advanced and sutured to the urethra, covering the remaining exposed corpora using 4-0 interrupted vicryl sutures. Other sutures

are performed using nylon 4-0 single stitches, starting from the ventral portion of the penis, joining the two scrotal flaps, followed by the dorsal portion of the penis and the flap angles (Figures 1E and 2E). The vertex of the “V” formed from the incised median scrotum line is anchored to the base of the penis with a nylon 2.0 suture (Figures 1F and 2F). After completion of the sutures, a Foley catheter is introduced for 5 to 7 days to keep the wound clean, dry, and minimize the chances of urethral stenosis.

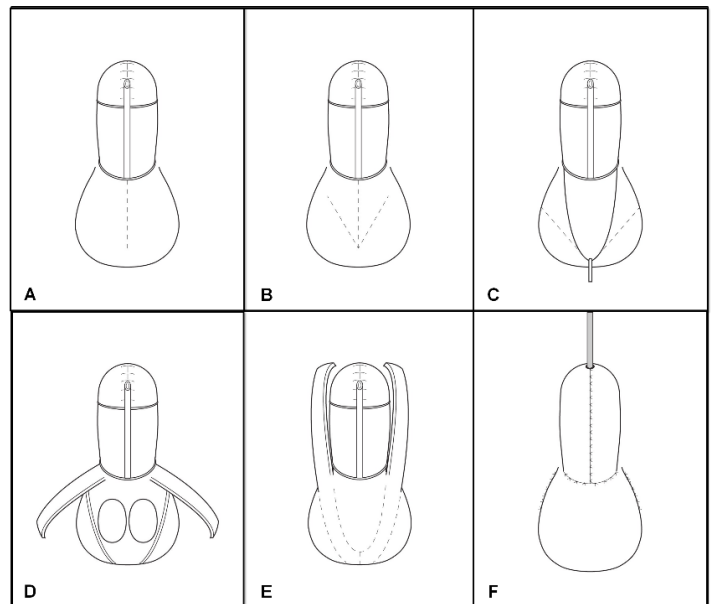


Figure 1: Illustration of scrotal flap reconstructive surgery for partial penectomy in penile cancer. **(A)** Demarcation on the scrotal raphe. **(B)** Incision along the demarcation resulting in a “V” shape. **(C)** Demarcations will appear as a trapezoidal shape with its smaller base in the scrotum. **(D)** Incision of the lines and the smaller base of the trapezoidal shape obtaining the scrotal flap. **(E)** Rotation of the scrotal flap. **(F)** Suturing of the flap and final appearance.

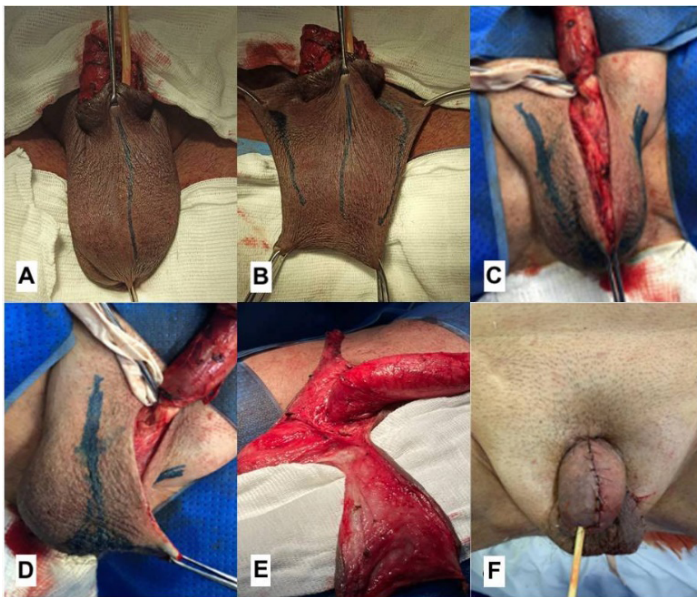


Figure 2: Intraoperative construction of a scrotal flap to cover the remaining penile shaft after partial penectomy. (A) Demarcation on the scrotal raphe. (B) Incision along the demarcation resulting in a “V” shape. (C) Demarcations will appear as a trapezoidal shape with its smaller base in the scrotum. (D) Incision of the lines and the smaller base of the trapezoidal shape obtaining the scrotal flap. (E) Rotation of the scrotal flap. (F) Suturing of the flap and final appearance.

Results

The appearance was satisfactory in all patients. We noted no neomeatal stenosis or flap necrosis secondary to the technique. Surgical wound infection was observed in one patient (20%), and he was treated with intravenous antibiotic therapy for seven days. Surgical wound hematoma was observed in one patient (20%) with no need for drainage. At this time, there is no tumor recurrence, and voiding function is preserved. Regarding sexual function, the patients maintained penetration with Phosphodiesterase Type 5 Inhibitors (PDE5) or intracavernous injection of vasoactive drugs.

Discussion

Penile tumor is a rare disease in most developed countries, but it has one of the highest prevalence rates worldwide in Brazil [8]. Although rare, reconstructive surgery following partial penectomy for penile carcinoma remains challenging, and the final appearance of the penis is a major concern. Partial penectomy remains the standard care for distal penile cancer. It offers excellent local control with low recurrence rates (<10%), and in most cases, sexual intercourse and adequate voiding are achievable goals [9]. OSS should be considered in patients with stages Tis/Ta/T1

(Carcinoma in situ/ Non-invasive verrucous carcinoma/tumor invades subepithelial connective tissue with lymphovascular invasion or perineural invasion) and some T2 (tumor invades corpus spongiosum with or without invasion of the urethra), especially when there is no invasion of the urethra and a well or moderately differentiated PC. A select few with Stage T3 (tumor invades into corpora cavernosum with or without invasion of the urethra) may be considered for OSS when urethral involvement is confined to the glans and total glans excision is performed. Patients should have a penile stump that is sufficient for a forward-directed urine stream in an upright position, and the suggested penile length to maintain urinary function is 3-4 cm [10].

The classic technique described by Pack GT et al. often causes partial penile retraction in the flaccid or erect state, involves urethral meatal stenosis, and does not include glanuloplasty [6]. Puckett CL et al. described a groin flap without sensation that was used to tailor a glans [11]. Chang TS et al. described a radial forearm flap for phallic reconstruction in 1984 [12]. Semple JL et al. and Biemer E et al. reported modifications of these flaps in which the glans was formed by a split-thickness skin graft, plicating sutures, or tattooing [13,14]. Horton CE et al. described skin grafts and preputial flaps that have been used in certain traumatic situations [15]. Mazza ON et al. developed a 2-stage technique in which a scrotal fasciocutaneous flap is advanced, tubularized, and sutured to the distal end of the penis. The flap pedicle is then resected with the patient under local anesthesia 6 weeks later [16]. Korkeas F et al. described the parachute technique for stump reconstruction after partial penectomy with a good outcome. They used the shaft skin to cover the penile body. With little skin remaining for reconstruction, we propose this scrotum flap surgery as a means to preserve the morphological aspect of the penis as normally as possible [17]. The major limitation of our study is the small number of cases performed at the time. Despite this limitation, to the best of our knowledge, the present study is the first reported reconstructive surgery using a scrotal flap for PC.

Conclusion

Penile-preserving and reconstructive surgery with a scrotal flap has proven to be a safe and viable option for the treatment of localized penile cancer. It ensures a favorable penile appearance, preserves sexual and voiding function, and maintains good quality of life and psychological well-being without compromising oncological outcomes. Local recurrence rates are higher with all types of local organ-sparing treatment, typically occurring within the first two years. However, local recurrence does not impact the rate of cancer-specific survival. Therefore, close clinical surveillance is necessary following OSS, as it can be easily detected through physical examination.

Citation: Venturini B, Zacché B, Frasson PL, Borges CF, Prado R, et al. (2024) Penile Preserving and Reconstructive Surgery: The Initial Experience with Scrotal Flap in the Management of Penile Cancer. *J Surg* 9: 11069 DOI: 10.29011/2575-9760.11069

Funding

The author(s) received no financial support for the research, authorship, and/or publication of this article.

References

1. Mahesan T, Hegarty PK, Watkin NA (2016) Advances in Penile-Preserving Surgical Approaches in the Management of Penile Tumors. *Urol Clin North Am* 43: 427-434.
2. Burnett AL (2016) Penile preserving and reconstructive surgery in the management of penile cancer. *Nat Rev Urol. Actions* 13: 249-257.
3. Philippou P, Shabbir M, Malone P, Nigam R, Muneer A, et al. (2012) Conservative surgery for squamous cell carcinoma of the penis: resection margins and long-term oncological control. *J Urol* 188: 803-808.
4. Leijte JA, Kirrander P, Antonini N, Windahl T, Horenblas S (2008) Recurrence patterns of squamous cell carcinoma of the penis: recommendations for follow-up based on a two-centre analysis of 700 patients. *Eur Urol* 54: 161.
5. Kamel MH, Bissada N, Warford R, Farias J, Davis R (2017) Organ Sparing Surgery in Penile Cancer: A Systematic Review. *J Urol* 198: 770-779.
6. Pack GT and Ariel IM (1963) Treatment of tumors of the penis. In: *Treatment of Cancer and Allied Diseases: Tumors of the Male Genitalia and the Urinary System*, 2nd ed. New York: Harper and Row 15.
7. Belinky JJ, Cheliz GM, Graziano CA, Rey HM (2011) Glanuloplasty with urethral flap after partial penectomy. *J Urol* 185: 204-206.
8. Favorito LA, Nardi AC, Ronalsa M, Zequi SC, Sampaio FJ, et al. (2008) Epidemiologic study on penile cancer in Brazil. *Int Braz J Urol* 34: 587-591.
9. Zukiwskyj M, Daly P, Chung E (2013) Penile cancer and phallus preservation strategies: a review of current literature. *BJU Int.* 112 Suppl 2: 21-26.
10. Li J, Zhu Y, Zhang SL, Wang CF, Yao XD, et al. (2011) Organ-sparing surgery for penile cancer: complications and outcomes. *Urology* 78: 1121.
11. Puckett CL. and Montie JE (1978) Construction of male genitalia in the transsexual, using tube groin flaps for the penis and hydraulic inflation device. *Plast Reconstr Surg* 61: 523-530.
12. Chang TS. and Hwang WY (1984) Forearm flap in one-stage reconstruction of the penis. *Plast Reconstr Surg* 74: 251-258.
13. Semple JL, Boyd JB, Farrow GA (1991) The "cricket bat" flap: a one-stage free forearm flap phalloplasty. *Plast Reconstr Surg* 88: 514-519.
14. Biemer E (1988) Penile construction by the radial arm flap. *Clin Plast Surg* 15: 425-430.
15. Horton CE, and Dean JA (1990) Reconstruction of traumatically acquired defects of the phallus. *World J Surg* 14: 757-762.
16. Mazza ON and Cheliz GM (2001) Glanuloplasty with scrotal flap for partial penectomy. *J Urol* 166: 887-889.
17. Korke F, Neves-Neto OC, Wroclawski ML, Tobias-Machado M, Pompeo AC, et al. (2010) Parachute technique for partial penectomy. *Int Braz J Urol* 36: 198-201.