



Case Report

Phalangeal Schwannoma: Case Report and Literature Review

Eugenio Martínez Ceballos¹, Fernando Tellez Pallares^{1*}, Karen Campos Gómez¹, Francisco Padilla¹, Ricardo Romero¹, Carolina M. Castro², Alberto Valdez², María de Guadalupe Gómez², Edna M. Aizpuru^{1*}

¹Department of Plastic Surgery, Angeles Pedregal Hospital, Mexico City, Mexico

²Department of Radiology, Magnetic Resonance Imaging. Angeles Pedregal Hospital, Mexico City, Mexico

*Corresponding author: Fernando Téllez Pallares, Department of Plastic Surgery, Angeles Pedregal Hospital, Mexico City, Mexico

Citation: Martínez E, Aizpuru EM, Pallares FT, Castro CM, Valdez A, et al. (2022) Phalangeal Schwannoma: Case Report and Literature Review. J Surg 7: 1659. DOI: 10.29011/2575-9760.001659

Received Date: 29 November, 2022; Accepted Date: 05 December, 2022; Published Date: 08 December, 2022

Abstract

Objective and Introduction: To present a case and review the literature on the behavior and diagnosis of upper extremity schwannomas. Schwannomas are the most common benign tumors of the peripheral nerve. In Mexico, their incidence is unknown. Due to their slow growth and variable clinical presentation, they are often misdiagnosed, so an adequate understanding of their presentation and evolution are crucial to make an accurate diagnosis. The clinical presentation and the most frequent diagnostic methods will be analyzed with the purpose of unifying a systematized critical thinking for an accurate diagnosis. Conclusions: If a systematized approach to tumors of the upper extremity is determined, the incidence of errors or diagnostic delay can be reduced.

Keywords: Finger; Shwanoma; Soft tissue; Tendon sheath

Introduction

Within the tendon sheath tumours of the upper extremity, the most frequent benign neoplasms are Schwannomas.

Schwannomas are slow-growing tumours that originate from Schwann cells along the nerve sheath. This lesion develops eccentrically to the nerve fibers, being encapsulated by the perineurium. It is usually detected as a solitary lesion, within the age range of 20 to 50 years. Due to its insidious development, diversity of location, and involvement of structures, the definitive diagnosis is often delayed or even misdiagnosed. Different initial diagnostic methods such as magnetic resonance imaging and Doppler ultrasound have been proposed. Although they may share some clinical characteristics, certain specific symptoms of schwannomas suggest their diagnosis and allow for appropriate treatment. The objective is to discuss the clinical, imaging, histological, and immunohistochemical factors to identify nerve

tumours of the hand sheath and upper extremities and differentiate them from their malignant counterparts. The literature and the most current recommended surgical techniques for tumour removal are also reviewed.

Case Report

A 32-year-old male with no significant history is presented and comes for evaluation due to a current condition of 24 months of evolution, it begins with an increase in volume, initially asymptomatic and with slow and progressive growth; without clinical follow-up due to the SARS COV2 pandemic. At the time of the examination, a tumour located in the 4th finger of the left hand was evident on the palmar side of the palpable proximal phalanx, solid, firm consistency, with adherence to deep planes, approximately 5x3 cm, capillary refill of fewer than 3 seconds with preserved strength 5/5, paresthesias on the ulnar edge of the same finger. Extension 35 degrees, limitation of metacarpophalangeal flexion function with 120 degrees and proximal interphalangeal 110 degrees of the 4th finger, abduction and adduction of 20

degrees. The study protocol began requesting radiography, USG Doppler, and magnetic resonance imaging of the left hand, as well as preoperative laboratories. In the X-ray of the left hand, in the palmar region of the proximal phalanx of the 4th finger, a radiolucent image with a nodular appearance, with irregular edges, which causes irregularity in the bone cortex, with areas of thinning and deformity due to bone destruction, showing a predominance of affection in its volar aspect. As a final statement, a lytic and expansive tumour is reported in the proximal phalanx of the fourth finger (Figure 1).

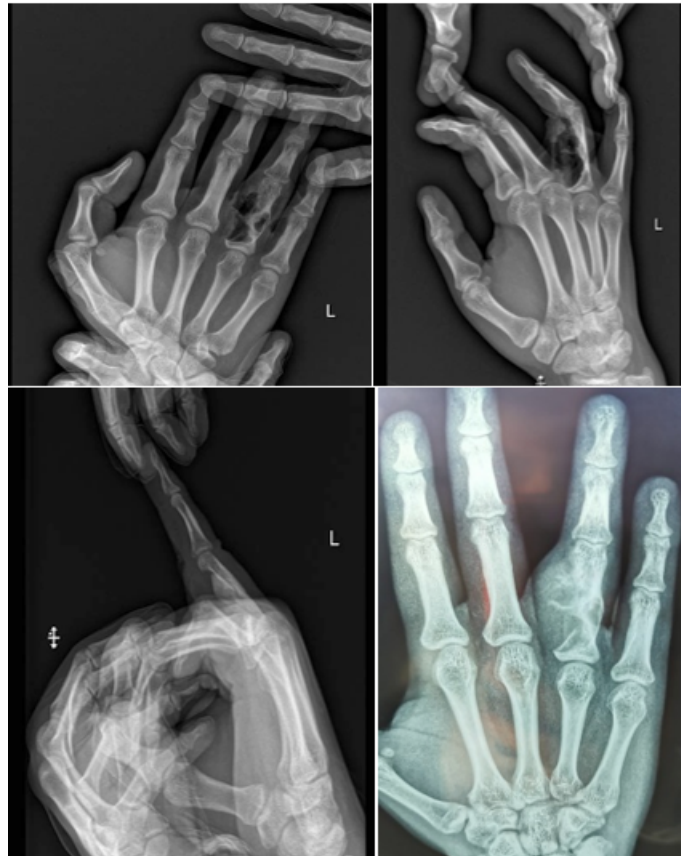

Figure 1: X-ray of the left hand, a radiolucent image with a nodular appearance in the phalanx of the 4th finger.

USG Doppler reports a nodular-looking image in the proximal phalanx of the fourth finger of the left hand, dependent on deep soft tissues, with lobulated but defined edges, heterogeneous content, predominantly hypo-echogenic with dimensions of 30 x 19 x 20 mm, in its longitudinal, anterosuperior, and transverse axes, respectively with an approximate volume of 6.3 CC. The color Doppler application showed predominantly peripheral mixed vascularity dependent on the radial interdigital artery, spectrum was taken in peripheral vessels with systolic velocity up to 45 cm/s and 5 cm/s in the centre. The lesion caused bone remodelling and ulnar displacement of the flexor tendons, recovering their alignment at the level of the middle and distal phalanx. The fibrillar pattern and diameter were preserved within the parameters without evidence of solutions of continuity. The flexor and extensor tendons of normal sonographic characteristics. As a final state, it is reported: A deep soft tissue tumour on the palmar side of the proximal phalanx which, due to its characteristics, suggests hemangioma; intact superficial and deep flexor tendons with ulnar displacement at the level of the proximal phalanx (Figure 2).

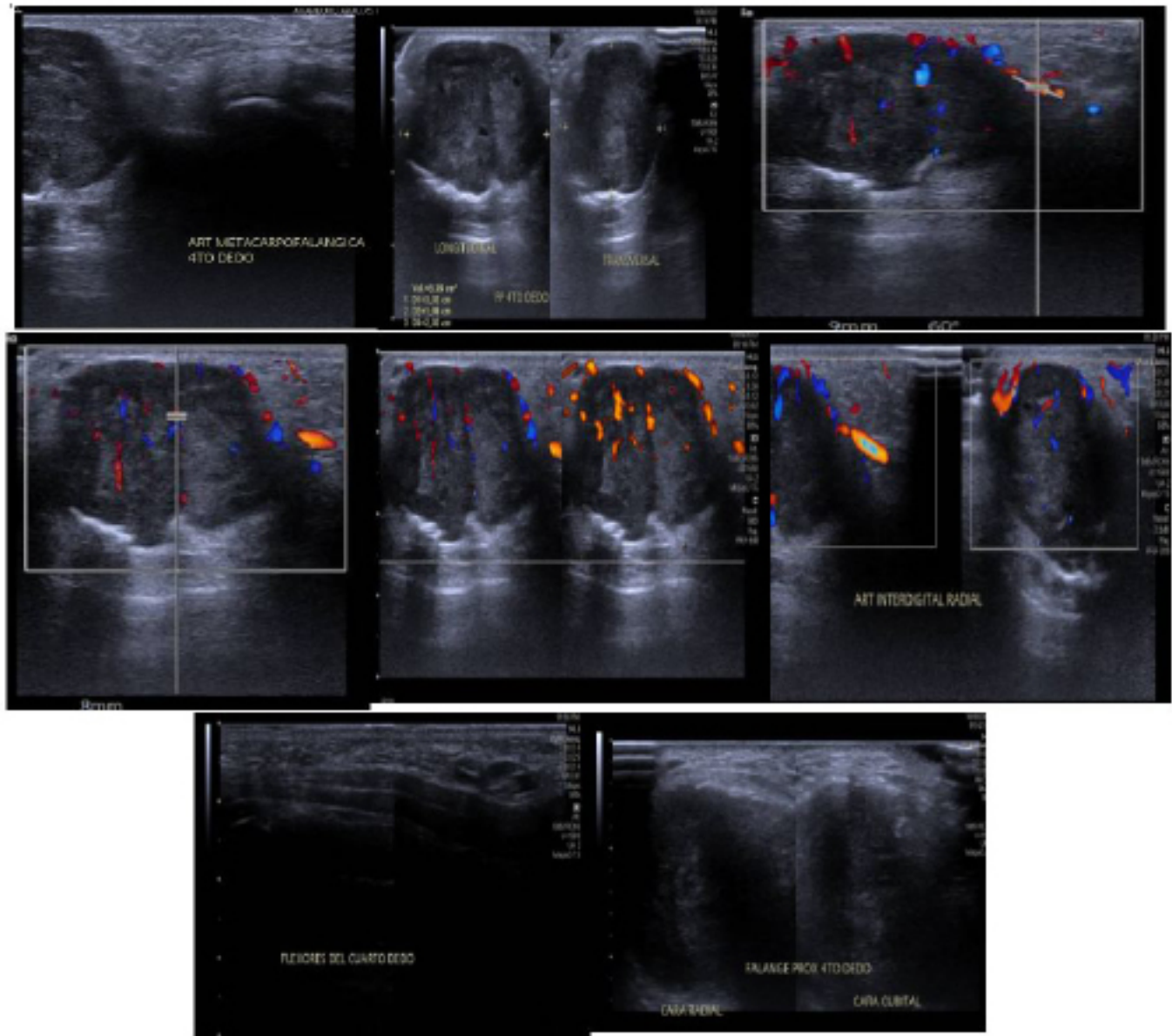


Figure 2: Doppler USG shows a nodular-looking image in the proximal phalanx of the fourth finger of the left hand. Color Doppler application showed peripheral mixed vascularity dependent on the radial interdigital artery and bone remodelling with ulnar displacement of the flexor tendon.

The Magnetic Resonance of the left hand was carried out in weighted sequences in T1, T2 and fat saturation, as well as the application of intravenous contrast medium, observing a well-defined nodular image in the palmar end of the proximal phalanx of the fourth finger with an erosion of the adjacent cortex, behaviour isointense to the muscles on T1, heterogeneous, predominantly hyperintense on T2, and homogeneous hyperintense on fat saturation, showing heterogeneous enhancement upon passage of the contrast medium and dimensions in the coronal plane of 3.3 x 2.3 cm. In the angiography sequence, dependent irrigation of the digital artery of the fourth finger is observed. Due to the findings described above, a space-occupying lesion affecting the deep soft tissues of the palmar portion of the proximal phalanx of the fourth finger was left as a conclusion to be considered a giant cell tumour of the tendon sheaths vs. hemangioma (Figure 3).

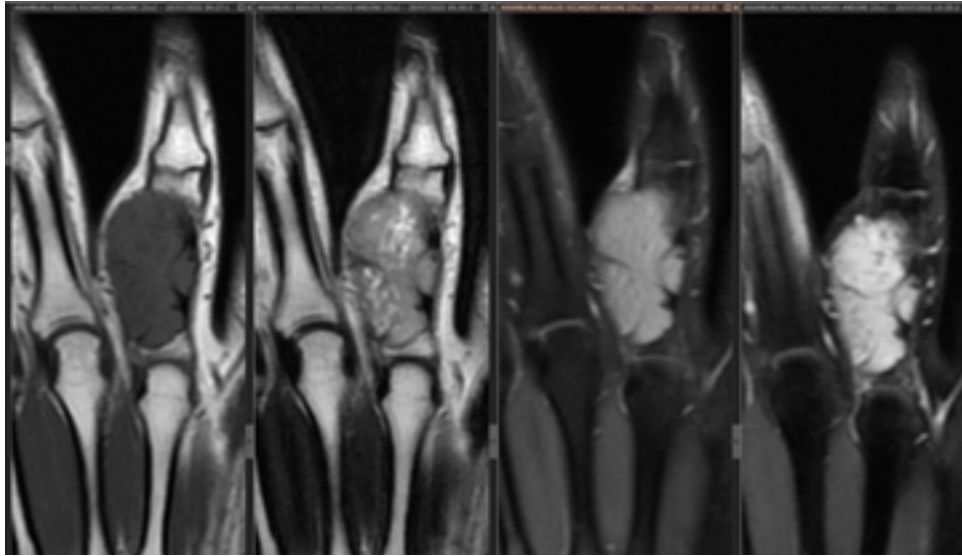


Figure 3: MRI of the left hand nodular image in the palmar end of the proximal phalanx of the fourth finger with an erosion of the adjacent cortex.

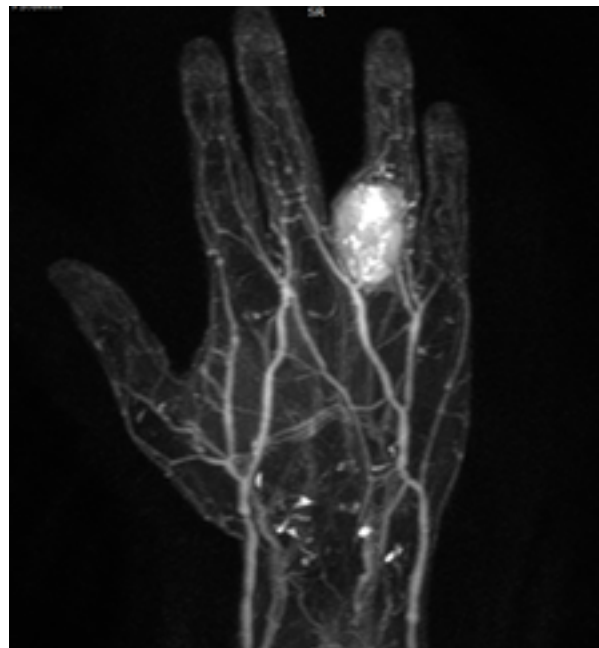

Figure 4: angiography sequence, dependent irrigation of the digital artery of the fourth finger is observed. conclusion to be considered a giant cell tumour of the tendon sheaths vs. hemangioma.

Due to clinical progression, surgical management was decided. Planned surgery: en bloc resection of the tumour with bone reconstruction with cadaveric bone graft plus deep flexor tenorrhaphy. The procedure is performed under mixed anaesthesia with balanced regional + general block, asepsis and antisepsis with chlorhexidine, and the ischemia time begins. Tumour resection is performed with monopolar energy. There is no evidence of injury to the tendon sheath, the capsule is intact, and it is resected en bloc without eventualities. Bone scarification is performed, edge regularization and bone tissue is filled with surgical cement. Hemostasis is verified. The A2 pulley is rebuilt and repaired. Finally, flaps are made for skin closure. The surgery lasted 120 minutes, with 90 minutes of ischemia. 50cc bleeding. A transoperative study was carried out where a tumor of the peripheral nerve sheath was reported. Subsequently, a definitive

report of injury to the proximal phalanx of the fourth finger of the left hand was received; Cellular shwannoma, immunophenotype SOX10 +, S100 +, AML -, CD34 -. With a Ki67 proliferation index of 6%.

Discussion

Primary tumor and pseudotumor lesions of the hand are very common. However, it must be said that a large part of the so-called tumors are not really tumors from the histological point of view, being in most cases ganglions and other non-tumoral reactive lesions.

In a Spanish series published by Del Valle et al, a retrospective epidemiological study was made of 305 primary hand tumours reported the most common tumour was tendon sheath giant cell tumours (47%), followed by vascular tumours (18%), tendon sheath fibromas (13%), lipomas (13%) and the least frequent hand nerve tumours (7.5%). Nerve tumours of the hand and upper extremity sheath include benign and malignant tumours of the peripheral nerve sheath. Tumours derived from Schwann cells (schwannomas, neurinomas or neurilemmomas) belong to the benign neoplasms of the neural sheath, originating in Schwann cells and devoid of axons, with locally expansive growth, their aetiology remains uncertain. They can occur sporadically or be associated with type 2 neurofibromatosis, usually arising from the vestibular nerve and in the cerebellopontine angle or peripheral nerve roots and spinal roots. They are frequently confused with other types of tumours, mainly those derived from adipose tissue called lipomas. Although they are frequent in long nerves, they are not exclusive to the extremities, they are even present in less frequent sites and with symptoms that resemble other local tumours specific to certain areas of the head and neck. Unlike what happens with neurofibromatous tumours, schwannomas, also called neurilemmomas, neurinomas or also neurolemmomas, are the most frequent tumours of peripheral nerves that expand from an initial nerve fascicle, in most cases respecting, the remaining healthy fascicles of the nerve that are displaced towards the periphery of the tumour.

In general, these types of tumours appear isolated and with slow growth and few symptoms. Generally, patients come to the consultation for noticing a tumour and not for sensory deficit symptoms and even less, motor. It usually appears between the second and fourth decade of life and without a marked predilection for sex, although some series refer to a predilection for the female sex. [1] Schwannomas are circumscribed encapsulated nodules on the periphery of the endoneurium, usually confined to the subcutaneous tissue, of variable size, generally small (<5 cm) and microscopically soft, encapsulated brownish-whitish lesions that may have focal areas of cystic degeneration [2].

Clinical Diagnosis

The clinical diagnosis of Schwannoma is intricate since it is slow growing and lacks specific symptoms or signs. Its distribution is variable, it has been reported in order of frequency in the nose, ear, and throat, followed by the thorax, upper limbs, and lower limbs. And when we refer to the peripheral nerves, their most frequent location is usually in the flexors nerves, involving the ulnar nerve and in most cases being distal to the elbow.[3] The data that should make us think of a Schwannoma is an isolated, palpable, slow-growing tumour, with lateral movement with respect to the axis of the nerve involved, but fixed longitudinally. Macroscopically it is usually a round, encapsulated mass, well differentiated from the adjacent tissues. [4] The symptoms are usually minimal, secondary to gradual compression of the peripheral nerves, presenting with paresthesias, dysesthesias, and sometimes intermittent stabbing pain. Severe neurological involvement is very rare because tumours only tend to displace the nerve, applying minimal compression, thereby preserving the integrity and neural function. [5] We are aware of the clinical difficulty of diagnosing this pathology. Even in 2003 Rockwell et al, reported that the accurate diagnosis of this pathology was only made in 19% of cases [6].

Imaging Diagnosis

In conventional radiographic studies, they are visualized as a subcutaneous nodule that presents remodelling of the adjacent cortex, which makes it indistinguishable from tumours of the tendon sheath or hemangiomas, which is why magnetic resonance or ultrasound is requested for its proper characterization. On magnetic resonance, they have been described as well-defined spindle-shaped lesions that do not usually exceed 5 cm in diameter. If it is in an intramuscular location and is surrounded by fat, an image called "Fat Separation Sign" is reported on T1. They are isointense or slightly hyperintense with respect to muscle on T1, and hyperintense with respect to the fat on T2. On contrasted T2 sequences, sensitive to fluids, the lesions may present hyperintensities in the periphery with low or moderate intensity in the centre, also described as a target sign. On some occasions, the capsule can be seen on T2 sequences. Chronic Schwannomas are usually heterogeneous tumours, with areas of haemorrhage, calcifications, and cystic changes, which can cause confusion or similarities with other pathologies such as sarcomas [7].

It is important to mention that Schwannomas share practically all the radiological characteristics with neurofibromas, so their differentiation by imaging is usually practically impossible. However, there are imaging findings that suggest malignancy: 1) increased dimensions (>5 cm), 2) presence of peripheral enhancement, 3) perilesional oedema, 4) heterogeneous content intratumoral cystic changes, 5) loss of nerve continuity, 6) and infiltrative margins [8].

Histopathology

Schwannomas present two types of characteristic architectural constitutions described as Antoni type A and type B. A mutation of the SMARCB1 suppressor gene located on chromosome 22q11 are described, manifesting multiple intradermal Schwannomas. Antoni's pattern A is comprised of a proliferation of spindle cells, with elongated contours, well organized, with the presence of Verocay's nodules. Antoni's B pattern is characterized by irregularly arranged cells in a microcytic stroma, sometimes reported as a honeycomb, with collagen fibres and inflammatory cells. The Antoni type A zones form the component of the lesion, an area that stands out for the proliferation of spindle-shaped tumour cells arranged in compact rows, with dense areas separated by the Schwann cell prolongations originating Verocay bodies, fused cell processes in eosinophilic masses, without axons, named after the Uruguayan physician José Verocay described in 1910. [9] Antoni type B tissue consists of looser areas and widely separated Schwann cells, predominantly a myxoid stroma, lipid-laden macrophages, and dilated blood vessels with thick hyaline walls, a useful diagnostic feature are thick-walled hyalinized vessels that tend to bleed, resulting in hemosiderin deposition [10].

When we see chronic Schwannomas, degenerative changes such as calcifications, hemorrhages, hyalinization, infiltration of histiocytes, siderophages or cystic images can be observed. They are usually hypervascularized lesions, characterized by vessels with thickened walls. It is important to mention that the cells usually express the S100 protein and CD57, a marker of cells derived from the neural crest. As well as the AntiKI67 cell proliferation marker. They do not usually have a high mitotic index, usually less than 1%, so it should not be associated as an indicator of malignancy. [11] When there is haemorrhage with hemosiderin, cystic degeneration, calcification and marked cellular atypia in schwannomas, they are known as schwannomas with degenerative changes (ancient schwannoma) and there are, in addition to the classic type, rare variants of schwannoma: plexiform, cellular, aged, epithelioid, melanocytic.

Plexiform neurilemmoma: Multiple encapsulated, hypercellular nodules, detached from the normal connective tissue, with a palisade nuclear arrangement with signs of vascular degeneration. [12] They affect multiple nerve roots, and can simulate a neurofibroma both microscopically and macroscopically, their differentiation is important since plexiform neurofibroma is strongly related to neurofibromatosis type 1 and risk of malignant degeneration. The S-100 protein and SOX-10 are diffusely positive in schwannoma and in patches in neurofibroma, useful information to distinguish these two entities. In addition, CD34 is diffusely positive in neurofibroma and only focal in schwannoma. [13] **Cellular neurilemmoma.** Highly cellular tumour, particularly in Antoni's A zones. Mitoses are present, but not atypical, occurring

more frequently in the paraspinal region of the pelvis, in the retroperitoneum, and in the mediastinum, and may reappear [14].

Cellular schwannoma may resemble a malignant tumour of the peripheral nerve sheath. The histological characteristics that suggest cellular schwannoma are the absence of necrosis, the presence of a capsule with lymphoid aggregates, the absence of fasciculated architecture, and diffuse and intense expression of the S-100 and SOX10 protein with Ki-67 less than 20%. [15] **Aged neurilemmoma.** It presents degenerative changes in the form of calcifications, haemorrhages, hyalinization or cystic degeneration. With infiltration secondary to numerous histiocytes and siderophages, with the presence of Schwann cells with voluminous, hyperchromatic, multilobulated nuclei and with atypia, but without mitosis. [16] **Epithelioid Neurilemmoma.** Subcutaneous multinodular tumours, and highly cellular, form an epithelioid structure in trabeculae, cords, and cumuli. It is a highly vascularized tumour with infrequent mitoses. [17] **Neurilemmoma** with a predominance of Verocay bodies. Its particularity is the predominant or exclusive presence of Verocay bodies (from 75 to 100% of the tumour). [18]

Other variants are mixed neurilemmoma composed essentially of Antoni's B zones) with a predilection for the extremities, particularly the fingers. Histologically, they are globular aggregates of Schwann cells with vacuolated cytoplasm immersed in a myxoid matrix where, focally, Verocay bodies can be found. This lesion is intensely positive for S-100 protein, SOX-10, GFAP, and CD57 [19].

Pigmented neurilemmoma that contains melanin, its presence in this neoplasm is explained because the melanocytes are derived from Schwann cell precursors. This tumour does not have Antoni A, Antoni B areas, or Verocay bodies [20,21].

Conclusion

We propose the following critical thinking; In the clinical approach, the key data that should make us think about this pathology are; Palpable, single, slow-growing, rounded tumour, with lateral movement with respect to the axis of the nerve and fixed longitudinally. Subsequently, in support of imaging studies, the USG Doppler should look for a hypervascularized tumour, predominantly peripheral. On the MRI, a homogeneous tumour, of medium intensity on T1 and high intensity on T2, which stands out in contrast. If there is high suspicion, a biopsy and histopathology should be performed where they are characterized by two different architectures; Antoni A type (high cellularity) and Antoni B type (low cellularity). Likewise, the presence of the S-100 protein and CD57 support the diagnosis. Schwannoma continues to be a tumour that historically is usually diagnosed postoperatively due to the difficulty and connotation similarity with other peripheral tumours. If we follow this systematized process when assessing

tumours of the upper limbs, we can reduce the delay in diagnosis of Schwannomas and therefore carry out the early treatment.

References

1. Muñoz S (2003) Tumores neurogénicos de nervios periféricos: estudio por imágenes. *Rev Chil Radiol* 9: 124-136.
2. Rodríguez FJ, Folpe AL, Giannini C, Perry (2012) Pathology of Peripheral Nerve Sheath Tumors: Diagnostic Overview and Update on Selected Diagnostic Problems. *Acta Neuropathol* 123: 295-319.
3. Perteu M, Filip A, Huzum B, Lunca S, Car, C, et al. (2022) Schwannoma of the Upper Limb: Retrospective Study of a Rare Tumor with Uncommon Locations. *Diagnostics* 12: 1319.
4. Adani R, Baccarani A, Guidi E, Tarallo L (2008) Schwannomas of the upper extremity: Diagnosis and treatment. *La Chirurgia Degli Organi Di Movimento* 92: 85-88.
5. HASHA, S, MATTEUCCI P, STANLEY PRW (2006) Schwannomatosis: Multiple Schwannomas of the Upper Limb. *Journal of Hand Surgery* 31: 182-184.
6. Rockwell GM, Thoma A, Salama S (2003) Schwannoma of the Hand and Wrist. *Plastic and Reconstructive Surgery* 111: 1227-1232.
7. Woertler K (2010) Tumors and Tumor-Like Lesions of Peripheral Nerves. *Seminars in Musculoskeletal Radiology* 14: 547-558.
8. Wasa J, Nishida Y, Tsukushi S, Shido Y, Sugiura H, Nakashima H, et al. (2010) MRI features in the differentiation of malignant peripheral nerve sheath tumors and neurofibromas. *AJR. American Journal of Roentgenology* 194: 1568-1574.
9. Ortiz-Hidalgo C, José Verocay (2004) Neurinomas y cuerpos de Verocay y otras contribuciones a la medicina. *Rev Neurol* 39: 487-489.
10. De Luca-Johnson J, Kalof AN (2016) Peripheral nerve sheath tumors: an update and review of diagnostic challenges. *Diag Histopathol* 22: 447-457.
11. Coulon A, Milin S, Laban E, Debais C, Jamet C, et al. (2009) Aspects histopathologiques des principales tumeurs des nerfs périphériques. *Neurochirurgie* 55: 454-458.
12. Zhou J, Man XY, Zheng M, Cai SQ (2012) Multiple plexiform schwannoma of a finger. *European Journal of Dermatology* 22: 149-150.
13. Berg JC, Scheithauer BW, Spinner RJ, Allen CM, Koutlas IG (2008) Plexiform schwannoma: a clinicopathologic overview with emphasis on the head and neck region. *Hum Pathol* 39: 633-640.
14. Cimino-Mathews AM (2011) Peripheral nerve sheath tumors. *Surg Pathol* 4: 761-782.
15. Pekmezci M, Reuss DE, Hirbe AC (2015) Morphologic and immunohistochemical features of malignant peripheral nerve sheath tumors and cellular schwannomas. *Mod Pathol* 28: 187-200.
16. Kljanić J, Caillaud J-M, Lagacé R (2006) Cytohistologic correlations in schwannomas (neurilemmomas), including "ancient," cellular, and epithelioid variants. *Diagnostic Cytopathology* 34 :517-522.
17. Koepfel MC, Andrac-Meyer L (2005) Tumores conjuntivos cutáneos benignos. En: *Enciclopedia médica quirúrgica*. Edit Elsevier 2005: 98-610.
18. Camacho-Partida IG, Ortiz-Hidalgo C (2017) El diagnóstico histológico y la inmunohistoquímica de las neoplasias de la vaina del nervio periférico. *Patología Rev Latinoam* 55: 445-464.
19. Graham A (2009) Melanocyte production: dark side of the Schwann cell. *Curr Biol* 19: R1116-1117.
20. Er U, Kazanci A, Eyriparmak T, Yigitkanli K, Senveli E (2007) Melanotic schwannoma. *Journal of Clinical Neuroscience* 14: 676-678.
1. Bartolome del Valle, Garcia, Gonzalez (1998) Primary Tumors of the soft tissues of the hand. *Epidemiological Analysis of 305 cases*. *Revista de Ortopedia y Traumatología* 42: 418-426.