



Case Report

Pseudosarcomatous Myofibroblastic Proliferation, A Rare Bladder Condition Successfully Managed with Partial Cystectomy - A Case Report and Literature Review

Raymond Xu¹, Davis Temple², Majid Mirzazadeh^{2*}

¹Wake Forest Baptist Medical Center, Department of Urology, Winston-Salem, NC, USA

²Wake Forest School of Medicine, Winston-Salem, NC, USA

*Corresponding author: Majid Mirzazadeh, Wake Forest School of Medicine, Winston-Salem, NC, USA

Citation: Xu R, Temple D, Mirzazadeh M (2023) Pseudosarcomatous Myofibroblastic Proliferation, A Rare Bladder Condition Successfully Managed with Partial Cystectomy - A Case Report and Literature Review. J Urol Ren Dis 08: 1353. DOI: 10.29011/2575-7903.001353.

Received Date: 27 September 2023; **Accepted Date:** 02 October 2023; **Published Date:** 04 October 2023

Abstract

Purpose: Pseudosarcomatous fibromyxoid tumors of the genitourinary tract are rare tumors that can be a surgical emergency, presenting with relentless gross hematuria. While the majority of cases reported in the literature describe transurethral resection as the initial approach, poor visibility and large tumor burden, particularly in the pediatric population, may obviate successful management. We reviewed the literature and report a case in which the bleeding mass was acutely managed with an open partial cystectomy with no long-term complications, including no tumor recurrence or progression.

Case Presentation: A healthy 16 year-old, non-smoking male presented with severe gross hematuria causing hemodynamically instability requiring management with open partial cystectomy. Initial transurethral resection was attempted, however poor visibility and large tumor burden prevented adequate resection. The case was converted to an open approach and a partial cystectomy was performed. The patient was closely monitored subsequently, and was without any evidence of tumor recurrence/progression, or repeated episodes of hematuria 18 months following intervention.

Conclusions: While pseudosarcomatous fibromyxoid proliferation of the bladder may be managed with transurethral resection as an initial approach, we propose a low threshold for converting to open partial cystectomy. Furthermore, in this case we show that open partial cystectomy was a feasible and effective approach that may deserve consideration as an initial approach in the pediatric population where the smaller lumen pediatric cystoscope has visibility limitations. Open partial cystectomy is most efficacious in the setting of large tumors or managing more emergent presentations such as relentless gross hematuria causing hemodynamic instability.

Keywords: Pseudosarcomatous fibromyxoid tumors; Pseudosarcomatous myofibroblastic proliferation of bladder

Introduction

Pseudosarcomatous fibromyxoid tumors of the urinary tract are rare, reactive proliferations with low malignant potential classified microscopically by spindled myofibroblastic proliferations encircled by a background of myxoid stromal tissue. [1] The tumor was first characterized by Roth in 1980 who diagnosed the mass in a 32-year-old woman with a history of chronic cystitis. [2] Since the first description, it has been described in the literature by a variety of names including: inflammatory tumor, nodular fasciitis, atypical myofibroblastic tumor, and psudeomalignant spindle cell proliferation. A systemic review conducted by Teoh et al. in 2014 analyzed 41 studies comprising of 182 patients and determined that the tumors had a higher female prevalence with a male-to-female ratio of 1: 1.67 and that they tend to occur more frequently in younger patients with a peak age of diagnosis of less than 10 years old. [3,4] The most common presentation was with gross hematuria. [4] While the majority of patients underwent TURBT (60.8%), partial cystectomy (29.2%) & radical cystectomy (9.2%) were also performed.[3] Their analysis found that local recurrence was rare (4%) and there were no distant metastases reported at the time of their publishing. Xu et al. also has described minimally invasive techniques (e.g. laparoscopic & robot-assisted laparoscopic partial cystectomy) for approach following failed initial endoscopic approach. [5,6] Given the rarity of the disease, there are no formal recommendations regarding the appropriate treatment of pseudosarcomatous fibromyxoid tumors of the urinary tract. Seven cases reported by Spiess et al. underwent transurethral resection of bladder tumor (TURBT). [1] In 1995, Lakshmanan et al described the case of a four-year-old boy whose tumor was initially managed with TURBT, but found the large 6 cm mass precluded transurethral resection and he instead underwent a partial cystectomy. [5] A case series of eleven pediatric patients reports nine children required partial cystectomy, six of whom had failed initial management with TURBT [4].

Here we report the case of a pseudosarcomatous fibromyxoid tumor in a 16-year-old otherwise healthy male who presented to the emergency department with gross hematuria and hemodynamic instability requiring open partial cystectomy after attempted TURBT.

Materials & Methods

Literature Review

A Pubmed search for “pseudosarcomatous myofibroblastic proliferation of the bladder” produced 45 results, of which we selected published articles describing intervention used in initial management and outcomes including recurrence or metastasis.

Case Presentation

A 16 year-old otherwise healthy, non-smoker male presented to the emergency department with a spontaneous episode of severe gross hematuria. Initial evaluation in the emergency department included laboratory work-up that revealed a hemoglobin of 8.2 from a baseline of 13.9, and CT imaging showed 2.9 x 2.9 x 2.5 cm enhancing mass along the left aspect of bladder wall (Figure 1). Urgent cystoscopy & Transurethral Resection of Bladder Tumor (TURBT) was performed, however the attempt was limited by poor visibility from the profusely bleeding mass, and the decision was made to convert to an open partial cystectomy. The patient had an uncomplicated post-operative recovery and received one unit of blood before being subsequently discharged on post-operative day three. There were no post-operative complications reported at the three-week follow-up, and CT cystogram performed at that time demonstrated no extravasation. At the subsequent six-month, one-year, and two-year follow-ups the patient remained without any reported issues, including no reports of voiding symptoms or repeat episodes of hematuria. The patient underwent a surveillance cystoscopy at this time that demonstrated no visible evidence of tumor recurrence. CT Urogram was also without evidence of recurrence or metastasis. The final pathology revealed Pseudosarcomatous myofibroblastic proliferation of the bladder, positive for ALK-1, with negative surgical margins and no evidence of vascular invasion.

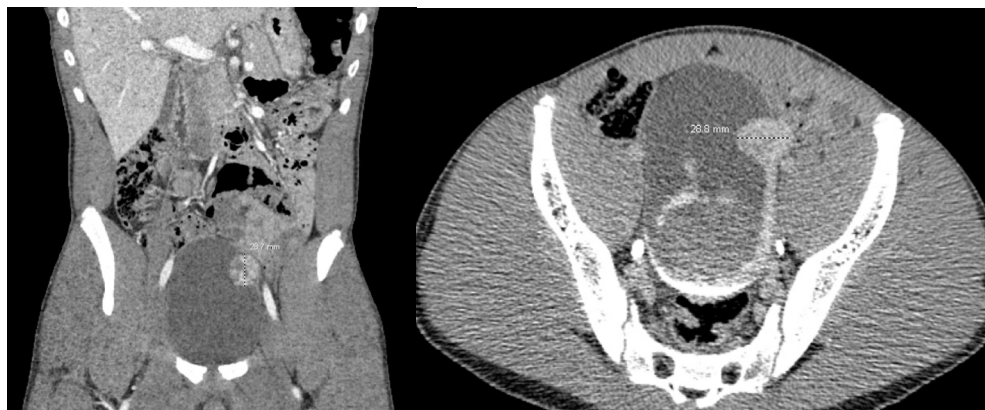


Figure 1: Initial CT imaging demonstrating the 2.87 cm left posterolateral bladder wall mass.

Discussion

Pseudosarcomatous fibromyxoid tumors of the genitourinary tract are rare, however can often be a surgical emergency. While the majority of cases reported in the literature describe transurethral resection of the mass for initial management, poor visibility and large tumor burden may obviate successful surgical control. This is particularly true in the pediatric population, in which the smaller instruments compound visibility problems, and an open partial cystectomy may be the most appropriate approach. With the rarity of this tumor, there is little data to support a uniform and singular initial approach to surgical management (Table 1). Harik et al. described a case series of 42 cases of pseudosarcomatous fibromyxoid tumor of both pediatric and adult patients that were managed by either TURBT (30/42), partial cystectomy (9/42), or total cystectomy (3/42). [7] Follow-up was obtained in 28 of the cases, with recurrence being documented in 3/28, and metastasis reported in 0/28.

Table 1: Literature Review of Studies Describing Pseudosarcomatous fibromyxoid tumors of the urinary tract for adults.

Study	Author	Year	Patient #	Intervention	Outcomes
#1	Harik et al. [7]	2006	42 (mean 47 yo)	TURBT (30/42), Partial Cystectomy (9/42), Total Cystectomy (3/42)	Recurrence in 3/28, no metastasis
#2	Hsiao et al. [8]	2008	1 (38 yo female)	TURBT, required repeat TURBT	Recurrence discovered 2 months later. No subsequent recurrence
#3	Singh et al. [9]	2015	1 (30 yo male)	Open cystectomy	No reported outcome
#4	Son et al. [10]	2023	1 (45 yo female)	TURBT	18 months no recurrence or metastasis
#5	Lei et al. [11]	2015	1 (22 yo male)	TURBT, required repeat TURBT + MMC (weekly x 6)	No recurrence or metastasis after 42 months
#6	Ayati et al. [12]	2019	1 (42 yo female)	Initial partial cystectomy, subsequent open radical cystectomy + ileal conduit	Recurrence after 6 months, no recurrence after subsequent treatment
#7	Gass et al. [13]	2019	1 (51 yo male)	TURBT	No recurrence or metastasis
#8	Villalba et al. [14]	1997	1 (79 yo male)	TURBT	No recurrence or metastasis

TURBT as initial treatment

Several individual case studies report successful initial management with TURBT without long-term recurrence or tumor progression. [10,13-16] In these reports the average age was 47.5 years, with only one reporting on a pediatric female of 15 years of age. However, there have also been documented cases where TURBT failed to control the tumor during initial treatment. Hsiao et al. reported a 38 year-old female who underwent initial TURBT, however required a second TURBT several months later due to recurrence. [8] Lei et al. similarly reported a 22 year-old male who underwent initial TURBT with local recurrence discovered 4 months later, requiring a repeat TURBT with weekly adjuvant intravesical mitomycin C treatment. [11].

Partial cystectomy as initial treatment

While several studies have described TURBT as a mainstay initial approach, it appears that often the cause of instability is a bleeding mass that may not be controlled with an endoscopic approach due to factors such as poor visibility and large tumor size. Ayati et al. reported a 42-year-old female who presented with several months of hospitalization and treatments for refractory gross hematuria, requiring two operations for cystoscopy, clot evacuation & fulguration. [12] However, due to inability to control bleeding endoscopically, she underwent open partial cystectomy for her bladder mass. Unfortunately, she presented 6 months later with recurrence and progression to adjacent tissues (e.g. muscle, abdominal rectus fascia) and bilateral pelvic lymph nodes that required open radical cystectomy, pelvic lymph node dissection, and ileal conduit creation.

Biopsy prior to Treatment

Singh et al. reported a 30-year-old male who presented with microscopic hematuria and large 6 cm polypoid bladder mass. [9] There was no history of trauma, previous instrumentation, or weight loss. He underwent initial biopsies that revealed

pseudosarcomatous myofibroblastic proliferation of the bladder, and subsequently underwent partial cystectomy as initial intervention. In non-urgent settings, a biopsy may be warranted to preclude aggressive interventions, however one must also consider the risks of additional instrumentation.

Pediatric Management

In the pediatric population, a bleeding bladder mass may be the presentation of several pathologies. It is important to rule out rhabdomyosarcomas, leiomyosarcomas, or sarcomatoid urothelial carcinomas as these pathologies often require more aggressive treatment such as more radical resection or adjuvant chemo-radiation therapies. Interestingly, in a situation where the clinical presentation is non-urgent e.g. controlled or less severe hematuria, there have been reports of first obtaining a confirmatory biopsy diagnosis prior to intervention. Chandramouleswari et al. described a 17-year-old female with a broad-based polypoid bladder mass who presented with suprapubic tenderness, dysuria, and mild hematuria who underwent cystoscopic biopsy prior to undergoing partial cystectomy. [17] While this patient had no reported recurrence or tumor progression, we suggest that initial biopsy may subject the patient to unnecessary instrumentation as resection of the bladder mass may also serve to obtain a pathologic diagnosis. Lakashmanan et al. described a 4-year-old male with a large 6 cm bladder mass for which initial cystoscopic biopsy was inconclusive, however due to persistent symptoms of dysuria & urinary frequency, an attempt at endoscopic resection was performed but the size of the tumor precluded this, and they converted to an open partial cystectomy. [15] While it is logical to biopsy a bleeding bladder mass prior to determining management, in the pediatric population it may also be reasonable to begin with an open approach, particularly if there is profuse bleeding as endoscopic visibility may be severely limited with pediatric instruments. The majority of cases documented in the literature in the pediatric population result in partial cystectomy as the definitive management (Table 2).

Table 2: Literature Review of Studies Describing Pseudosarcomatous fibromyxoid tumors of the urinary tract for pediatrics.

#1	Lakshmanan et al. [15]	1997	1 (4 yo male)	TURBT converted to open partial cystectomy	No recurrence or metastasis
#2	Vasilakaki et al. [16]	2014	1 (15 yo female)	TURBT	No recurrence or metastasis
#3	Chandramouleswari et al. [17]	2012	1 (17 yo female)	Cystoscopic biopsy, subsequent partial cystectomy	No recurrence or metastasis
#4	Lecuona et al. [18]	2012	1 (3 yo male)	Partial cystectomy	No recurrence or metastasis
#5	Suer et al. [19]	2012	1 (10 yo female)	Cystoscopic biopsy/TURBT, subsequent partial cystectomy	No recurrence or metastasis

Conclusions

In situations in which a patient presents with hemodynamic instability, time is vitally important. Initial endoscopic management with TURBT is reasonable, however we suggest a low threshold to convert to an open approach e.g. open partial cystectomy, for better surgical visibility and more definitive control of bleeding. While there is insufficient data to support oncological outcomes comparing open vs. endoscopic approach, one may speculate that an open approach would be preferred as it allows for improved visibility, faster control of bleeding in unstable patients, and more definitive removal of deeply invading tumors (seeding has not been reported to be a problem given the low malignant potential of this tumor). This is especially true in the pediatric population in which a smaller urethra precludes use of adult instruments, further limiting visibility.

Given the rather low malignant potential of this tumor, radical or even simple cystectomy may be premature for initial surgical management given the known complications and morbidity associated with those procedures.

References

1. Spiess PE, Tuziak T, Tibbs RF (2007) Pseudosarcomatous and sarcomatous proliferations of the bladder. *Hum Pathol* 38: 753-761.
2. Roth JA (1980) Reactive pseudosarcomatous response in urinary bladder. *Urology* 16: 635-637.
3. Teoh JYC, Chan NH, Cheung HY, Hou SSM, Ng CF (2014) Inflammatory Myofibroblastic Tumors of the Urinary Bladder: A Systematic Review. *Urology* 84: 503-508.
4. Hojo H, Newton WAJ, Hamoudi AB (1995) Pseudosarcomatous Myofibroblastic Tumor of the Urinary Bladder in Children— A Study of 11 Cases with Review of the Literature. *Am J Surg Pathol* 19: 1224.
5. Lakshmanan Y, Wills ML, Gearhart JP (1997) Inflammatory (pseudosarcomatous) myofibroblastic tumor of the bladder. *Urology* 50: 285-288.
6. Xu H, He B, Tu X (2018) Minimally invasive surgery for inflammatory myofibroblastic tumor of the urinary bladder: Three case reports. *Medicine (Baltimore)* 97: e13474.
7. Harik LR, Merino C, Coindre JM, Amin MB, Pedeutour F, et al. (2006) Pseudosarcomatous myofibroblastic proliferations of the bladder: a clinicopathologic study of 42 cases. *Am J Surg Pathol* 30: 787-794.
8. Hsiao CH, Wen YC, Lee LM (2008) Pseudosarcomatous myofibroblastic proliferation of the urinary bladder. *J Chin Med Assoc* 71: 431-434.
9. Singh A, Lahori M, Khajuria A, Gupta S (2015) Inflammatory myofibroblastic tumor of the urinary bladder: A diagnostic challenge and therapeutic dilemma. *Int J Appl Basic Med Res* 5: 149-150.
10. Son SM, Woo CG, Lee OJ, Kim YJ, Lee HC (2023) Inflammatory myofibroblastic tumor of the urinary bladder with FN1-ALK gene fusion: A case report. *Oncol Lett* 25: 227.
11. Lei JH, Yang L, Liu LR, Wei Q (2015) Successful treatment and follow-up of a case of recurrent pseudosarcomatous myofibroblastic proliferation. *Saudi Med J* 36: 363-365.
12. Ayati M, Nowroozi MR, Momeni SA, Moghadam SO, Saffar H, et al. (2019) Radical cystectomy for management of inflammatory myofibroblastic tumor of the urinary bladder: A rare case report. *Urol Case Rep* 2019.
13. Gass J, Beaghter M, Kwon Meeae (2019) Inflammatory Myofibroblastic Tumor of the Urinary Bladder: A Case Report. *Journal of Endourology Case Reports* 5: 31-33.
14. Salvador Villalba I, Alemany Monraval P, Martínez Leandro E, Martorell Cebollada M (1997) Lesiones pseudosarcomatosas de vejiga urinaria. Presentación de un caso [Pseudosarcomatous lesions of the urinary bladder. Report of a case. *Arch Esp Urol* 50: 77-78.
15. Lakshmanan Y, Wills ML, Gearhart JP (1997) Inflammatory (pseudosarcomatous) myofibroblastic tumor of the bladder. *Urology* 50: 285-288.
16. Vasilakaki T, Koulia K, Tsavari A (2014) Pseudosarcomatous myofibroblastic proliferation of the urinary bladder: a rare entity. *Urology* 83: 1409-1411.
17. Chandramouleeswari K, Anita S, Shivali B (2012) Pseudosarcomatous myofibroblastic tumour of the urinary bladder: a case report. *J Clin Diagn Res* 6: 1422-1424.
18. Lecuona AT, Van Wyk AC, Smit SG, Zarrabi AD, Heyns CF (2012) Inflammatory myofibroblastic tumor of the bladder in a 3-year-old boy. *Urology* 79: 215-218.
19. Sürer E, Gülpınar Ö, Mermerkaya M (2012) Inflammatory myofibroblastic tumor of the bladder in a 10-year-old girl. *Urology* 80: 1138-1140.