



## Research Article

# Reconstruction of the PCL Posterior Cruciate Ligament by Single Posterolateral Access to the Knee Reproduced Surgical Technique

Max Rogério Freitas Ramos<sup>1\*</sup>, Edmilson Barbosa Filho<sup>2</sup>, Marcio Tannure<sup>3</sup>, Joao Gabriel Villardi<sup>4</sup>, Eliane Santos da Luz<sup>3</sup>, Gabriel da Rocha Vieira<sup>3</sup>, Mark de Melo Ramos<sup>4</sup>, Igor de Melo Ramos<sup>4</sup>,

<sup>1</sup>Titular Professor of Orthopedics at the Federal University of the State of Rio de Janeiro UNIRIO, Brazil

<sup>2</sup>Orthopedist Master in Medicine at UNIRIO, Brazil

<sup>3</sup>Resident in Orthopedics at the Gaffre and Guinle University Hospital, Brazil

<sup>4</sup>Medical student, Brazil

**\*Corresponding author:** Freitas Ramos MR, Titular Professor of Orthopedics at the Federal University of the State of Rio de Janeiro UNIRIO, Brazil

**Citation:** Freitas Ramos MR, Barbosa Filho E, Tannure M, Villardi JG, Santos da Luz E, et al. (2022) Wrist Support Does Not Prevent Wrist Injury or Pain but May Be Therapeutic for Existing Wrist Pain in Female Gymnasts. Sports Injr Med 6: 190. DOI: 10.29011/2576-9596.100190

**Received Date:** 25 September, 2022; **Accepted Date:** 07 October, 2022; **Published Date:** 11 October, 2022

### Abstract

**Introduction:** The objective of this study is to present an anatomographic description of a new surgical approach, making possible the combined reconstruction of injuries of the Posterior Cruciate Ligament (PCL) and the Posterolateral Complex (PLC) of the Knee, using the arthroscopic approach, combined with the technique of direct visualization. of the tibial bed (INLAY), performed through a single extended posterolateral access. Methods: ten cadaver knees were studied, simulating a videoarthroscopic stage and the proposed lateral approach. The parameters evaluated: (1) anatomical structures involved in the expansion of access (2) topographic analysis of the relationship between popliteal muscle and popliteal artery; (3) identification of the quadrilateral tibial zone for fixation under direct visualization (INLAY) (4) preservation of the posterior joint capsule (5) identification of lacerations to the vasculonervous bundle of the popliteal fossa. The analyzes were complemented through subsequent dissections, in order to obtain visualization of the results in different perspectives, and thus guarantee a better interpretation of the evaluated parameters. Results: in all dissections we demonstrated the feasibility of expanding the lateral access, using the topography of the popliteus muscle, its repair and posterior retraction allowed the creation of space necessary for the construction of the tibial tunnel in the quadrilateral area, in addition to functioning as an additional protection barrier the neurovascular structures. The preservation of the posterior joint capsule supports this hypothesis. No neurovascular lacerations were observed. Conclusion: the approach described presented reproducibility for reconstructions in combined lesions, allowing the performance of all stages of these procedures using a single access, in addition to combining all the advantages of a classic INLAY technique, obtaining an adequate area for positioning the tibial tunnel and adequate tensioning of the graft, thus minimizing failure and loosening rates. The study also establishes safety guidelines, minimizing the risks of iatrogenic injuries to the neurovascular structures of the popliteal fossa. in addition to combining all the advantages of a classic INLAY technique, obtaining an adequate area for the positioning of the tibial tunnel and adequate tensioning of the graft, thus minimizing the rates of failure and loosening. The study also establishes safety guidelines, minimizing the risks of iatrogenic injuries to the neurovascular structures of the popliteal fossa. in addition to combining all the advantages of a classic INLAY technique, obtaining an adequate area for the positioning of the tibial tunnel and adequate tensioning of the graft, thus minimizing the rates of failure and loosening. The study also establishes safety guidelines, minimizing the risks of iatrogenic injuries to the neurovascular structures of the popliteal fossa.

**Keywords:** Ligament; Arthroscopy; Knee

## Introduction

The Posterior Cruciate Ligament (PCL) acts as a primary restrictor to posteriorization of the tibia in relation to the femur as described by Hughston [1,2] and as a secondary restrictor to varus and rotation external [3]. It emerges from a depression posterior to the intra-articular surface of the tibia and travels anteromedially to the lateral surface of the femoral condyle.medial (CFM) [4].

Traditionally divided into two functional bundles: anterolateral (AL) and posteromedial (PM), which have different behaviors according to the knee flexion-extension movements, having their anterior fibers elongated with flexion and the posterior fibers elongated inextension [5].

The peroneal collateral ligament and posterolateral compartment (PLC) structures act as a primary restrictor to varus and external rotation and play a secondary role in anterior and posterior tibial translation when the cruciate ligaments are in place broken [6,7].

The association of these lesions is relatively common,a series with 222 cases of acute knee injuries showed that only 3 (3.5%) were isolated PCL injuries [8]. Another study claims that 60% of PCL injuries are associated with some PLC injury [9]. Regarding PLC injuries, isolated ruptures correspond to only 25% of cases [10].

Given the above, the association of these lesions is commonly indicated for surgery, thus, several techniques have been described. Recent innovations in surgical PCL reconstruction focus on surgical variables. These include the number of reconstructed bundles (1 vs 2) and fixation of the graft in the tibia (transtibial tunnel vs INLAY) [11].

Among these variations, the greatest controversy remains about the best way to recreate the site for tibial fixation. The advantages cited in the literature in relation to the transtibial technique include: low morbidity; good reproducibility; does not require capsulotomy; easy patient positioning and good clinical results [12,13].

Those who advocate performing the INLAY open technique cite as benefits: Better biomechanical results, lower risks of neurovascular injuries and eliminates the risk of graft bending (killer turn), one of the main causes of failure related to the Transtibial technique [14-17].

Regarding CPL reconstructions, different techniques have already been described, including the techniques described byStannard [18] and LaPrade [19] are the most used nowadays.

The most feared complication of all these approaches already described are iatrogenic injuries to the neurovascular

structures involved, including the tibial nerve, common fibular nerve, popliteal artery and popliteal vein [20].

The popliteal artery and the tibial nerve are the structures at greatest risk during PCL reconstruction. The vascular-nervous bundle is located posterior to the posterior horn of the lateral meniscus, with the joint capsule interposing between the 2 structures [21,22]. The common peroneal nerve is the nerve at greatest risk during reconstruction of the posterolateral knee complex [8].

Although the potential for this complication is widely known, limited objective guidelines exist to help surgeons avoid its occurrence. In addition, the incidence of these complications remains uncertain, with few data demonstrating their occurrence in PCL reconstructions [22].

In this way, the anatomical knowledge of these structures and their relationships with the different techniques are essential for carrying out a safe surgical approach.

We also emphasize that although the literature is extensive for performing different surgical approaches in isolated reconstructions, few data are found for combined reconstructions of these complexes. In addition to being scarce, there are no data in the literature describing the INLAY approach involving lateral access.

In view of these observations, the hypothesis of a topographic analysis of this new surgical approach was proposed, aiming to demonstrate the feasibility ofreconstructioncombination of both ligament complexes using a single lateral approach extended to the posterior region.

## Goals

### Main goal

Topographic analysis of a new surgical approach, making possible the combined reconstruction of injuries to the Posterior Cruciate Ligament (PCL) and the Posterolateral Complex (PLC) of the Knee using videoarthroscopic technique, combined with the technique of direct visualization of the tibial bed (INLAY), performed through single lateral access extended to the posterior region.

### Specific objectives

1. Observe the relationships between the anatomical structures through the lateral access, establishing a safety zone for its posterior extension.
2. Creation of direct visualization area to the tibial quadrilateral zone for INLAY fixation in PCL reconstructions through lateral access;
3. Perform repair, detachment and posterior retraction of the popliteus muscle;

4. Posterior access to the joint and direct observation of the joint capsule, establishing its integrity as a safety criterion for iatrogenic injuries;
5. Identify the presence of visible lacerations to the vasculonervous bundle of the popliteal fossa after dissections.

## Methods

### Material

Descriptive anatomotopographical study, carried out in the anatomical of the Faculty of Medicine of the Federal University of the State of Rio de Janeiro (UNIRIO)

Ten anatomical sets (five cadavers) were studied. Data were obtained through photographic records and analysis by direct observation of the relationships between anatomical structures and the proposed approach. The procedures were performed by orthopedic surgeons members of the Brazilian Society of Knee Surgery (SBCJ). The work was approved by the Research Ethics Committee of the Center for Biological Sciences and Health of the Federal University of the State of Rio de Janeiro (UNIRIO) (CAAE-10427219.7.0000.5258)

### Method

The selection criteria considered: knee not surgically manipulated or by previous dissection; minimum mobility of **120°** of flexion; absence of degenerative intra-articular disease or previous PCL/PLC injury.

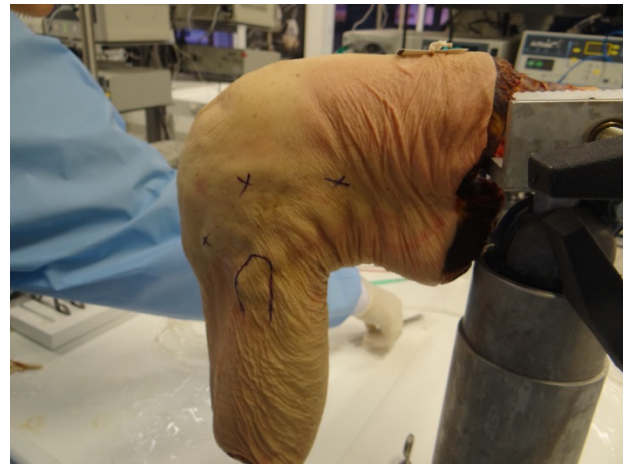### Graft Choice

Bone tendon bone graft taken from the patellar tendon was used, with a length of 6 cm of tendon + 2 cm of bone block at the proximal and distal ends, totaling 10 cm of total graft length, with 10 mm of tendon and bone block width. Two perforations were made with a 2mm drill in one of the bone blocks and a non-absorbable n.5 polyester suture was passed and a 4.0mm central hole was passed through the Adjustable Endobutton Arthrex TightRope and Botton Arthrex Dog Bone plate anchor, at this end, the ventral face of the graft is rounded using a gouge so that it fits into the INLAY tibial hole to be made later.

### Extended side access road

The selected anatomical sets were kept in 90° flexion for lateral access, an incision was created having as anatomical references the lateral epicondyle proximally and the Gerdy tubercle distally (Figure 1), and proceeding proximally along the posterior border of the iliotibial tract with approximately 10 cm in length as

described by several authors, widely used in reconstructions of the posterolateral complex [7,18,19].

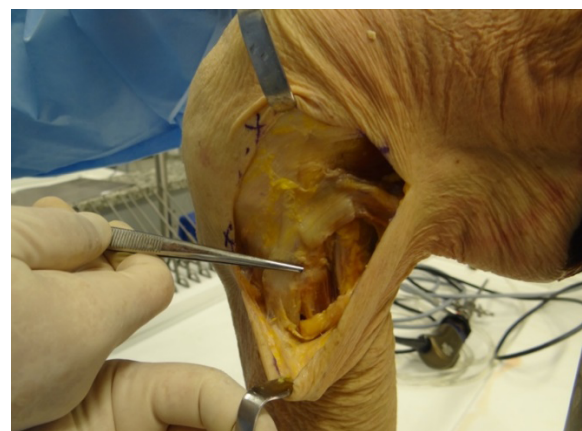

**Figure 1:** Anatomical references for lateral access to the knee. TG, Gerdy's tubercle; EL, lateral femoral epicondyle; TIT, iliotibial tract; CF, head of fibula.

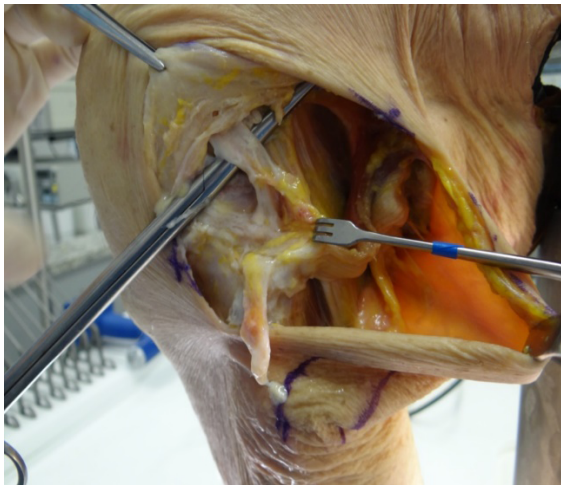
The access was continued through the visualization of the iliotibial tract and the biceps femoris tendon, and then the fibular nerve was identified and isolated.

A double longitudinal access was performed in the iliotibial band for anteroposterior mobilization.

Once identified, the lateral collateral ligament (LCL) and popliteus muscle tendon (TP) were sectioned and repaired, reproducing the essential injuries present in posterolateral knee instability (LCL+TP) (Figures 2 and 3).



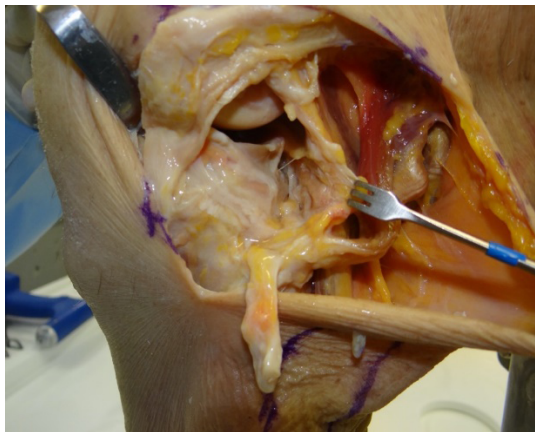
**Figure 2 :** Identification of posterolateral structures. LCL, lateral collateral ligament; CF, fibula head; BCL, long head biceps.



**Figure 3 :** Isolation of the popliteus muscle (PT) tendon.

Then, the popliteal tendon was repaired and its muscles were slightly detached from the posterior wall of the tibia, demonstrating the hypothesis of posterior extension of the access, creating a barrier to protect the neurovascular structures, composed of the popliteal artery and vein and the nerve tibial, minimizing the risk of iatrogenic injury.

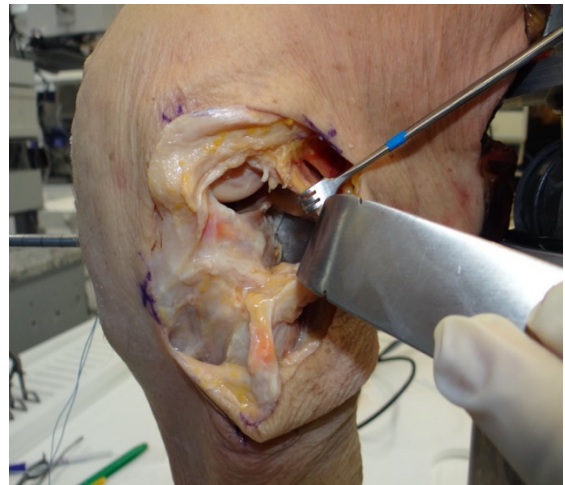
Following the posterior contour of the lateral meniscus, the longitudinal opening of the lateral joint capsule was carried out until the exposure of the quadrilateral tibial zone, keeping the Wrisberg meniscofemoral ligament as a reference, thus observing two anatomical structures to protect the neurovascular bundle (posterior joint capsule and Popliteus muscle) (Figure 4).



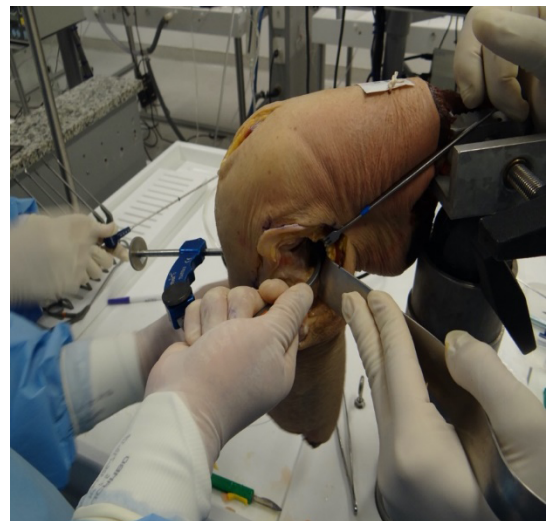
**Figure 4:** Posterior extension of the lateral access. ML, lateral meniscus; CFL, lateral femoral condyle; CP, posterior capsule.

Now with the direct visualization of the quadrilateral zone, the original tibial bed of the PCL, on the posterior surface of the intra-articular surface of the tibia, we proceeded with the exposure of the posterior cortex of the tibia and section of the

PCL in its femoral bed, reproducing your lesion. Then, with direct visualization of the quadrilateral zone, the posterior cortex of the tibia was exposed, thus creating a unicortical window for INLAY fixation of the graft's tibial bone block. An 11mm retrograde drill from Arthrex Flipcutter was used for this purpose. associated with the appropriate guide for LCP, also from Arthrex and we drilled 5 to 10mm deep, just enough to accommodate the graft to this bed. As an additional protection to the neurovascular structures, we used a dynamic retractor during the perforation of the tibial tunnel (Figures 5 and 16).



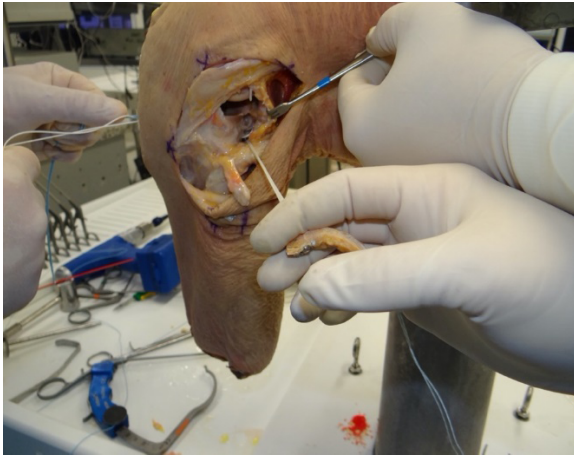
**Figure 5 :** Use of a dynamic retractor to protect neurovascular structures.



**Figure 6 :** Construction of the tibial tunnel under direct visualization of the quadrilateral zone.

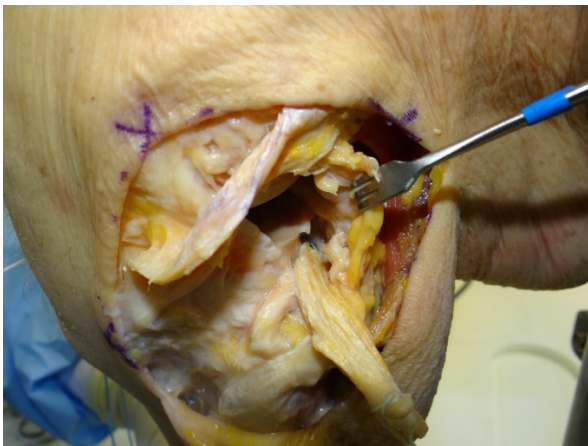
With the graft already prepared and rounded to 11mm in diameter by 5mm in depth, we made a central hole, through which we passed the Endobutton Arthrex TightRope device. placed to a

Button Arthrex Dog Bone® for fixing the tibial bone block (Figure 7).



**Figure 7 :** Fixation of the bone block of the graft with the DogBone® device.

The TightRope is then passed through the posterior tibial tunnel and pulled anteriorly until its exit in the anterior region of the tibia, where it was locked and then the graft was pulled until the bone block was fixed in the quadrilateral area with the aid of the Dog Bone® (Figure 8).

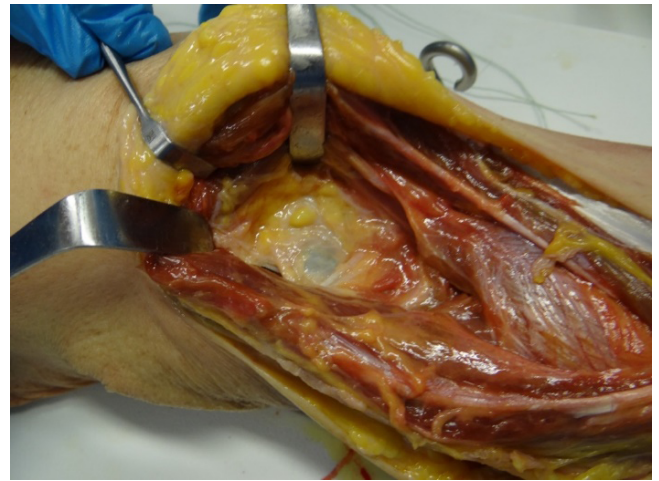


**Figure 8 :** Positioning of the bone block in the quadrilateral zone.

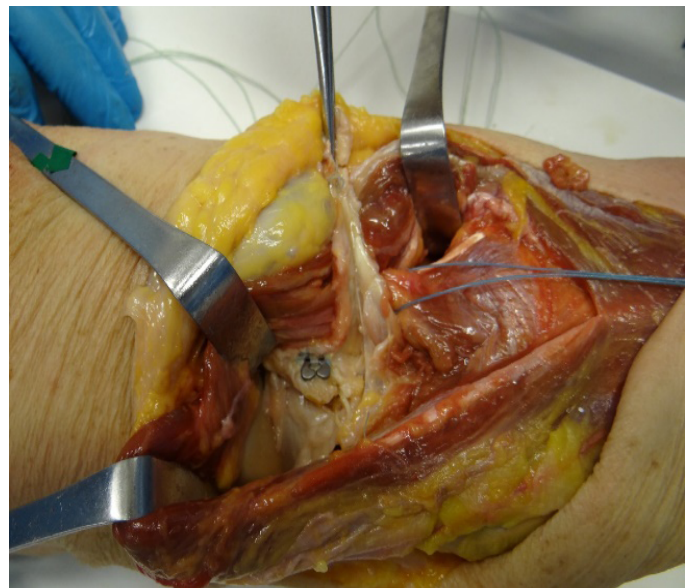
Once this is done, the other end of the graft is passed to the joint region under the Wrisberg ligament and the graft is fixed using a single or double band in femoral tunnels, as already described in traditional techniques, and reconstruction of the Corner is performed. Posterolateral CPL using the technique chosen by the surgeon, without the need to perform 2 different surgical accesses on the patient.

### Posterior dissection to assess capsular violation and risk to vascular structures

At the end of the surgical approach, posterior dissections were performed to visualize the relationship between the neurovascular structures and the necessary access for correct positioning of the graft, observing the preservation of the posterior capsule in all evaluated cadavers (Figure 9), thus demonstrating a safety zone for the reproducibility of the proposed approach (Figures 10 and 11)



**Figure 9 :** Intact posterior joint capsule.



**Figure 11 :** Bone block positioned in the quadrilateral zone.

## Results

Among the selected cadavers, observing the proposed inclusion and exclusion criteria, dissections were performed in ten anatomical sets, performed in the anatomy laboratory of the Federal University of the State of Rio de Janeiro and the Arthroscopy Laboratory. IOT FMUSP.

In all sets, dissections were performed with the lateral access proposed in this study, observing their anatomical relationships, with the objective of evaluating their reproducibility.

In all dissections, we demonstrated the feasibility of expanding the lateral access, using the topography of the popliteus muscle, located anterior to the vascular-nervous bundle, its detachment, repair and posterior retraction allowed the creation of space necessary for the construction of the tibial tunnel in the quadrilateral area under direct visualization, in addition to acting as an additional protective barrier to neurovascular structures.

Topographic analysis also allowed us to demonstrate the relationship between the posterior horn of the lateral meniscus and the joint capsule, with the capsule having a more posterior disposition, interposing between the lateral meniscus and the vascular-nervous bundle.

Thus, the extension of the access route following the posterior horn of the lateral meniscus proved to be effective and safe, observing the integrity of the joint capsule in the evaluated knees, thus establishing a safety criterion for the proposed access route.

Complementary analyzes through dissections posterior to the knee joint allowed the confirmation of the established criteria. In addition, no vascular lacerations were observed in the popliteal fossa.

## Discussion

Over time, several studies have described different approaches for isolated reconstructions of these complexes [1-23,24]. However, there are few data in the literature involving treatment algorithms for combined approaches [9,11]. Regarding injuries to the posterolateral complex, currently the most used techniques involve reconstruction of the lateral collateral ligament (LCL), popliteus muscle tendon and popliteofibular ligament (PPL) [18,19]. Despite the different techniques and their possible indications, we emphasize that the lateral access route is the most commonly used, widely known by orthopedic surgeons [17-19].

This access road offers security and ample area for the various approaches to the side structures. The peroneal nerve is the neurovascular structure related to this approach and its identification and repair are essential to prevent iatrogenic injuries [7]. If, on the one hand, there is a consensus regarding the lateral access route

as the best and safest approach in isolated reconstructions of the posterolateral complex, when we talk about PCL reconstructions, we find divergences in the literature, especially with regard to the best form of tibial fixation of the graft [9,11-14]. Currently, the INLAY fixation techniques through posteromedial access and the arthroscopic transtibial technique are the two most accepted in the literature, with several studies comparing their results [23-27].

Those who advocate performing the INLAY open technique cite as benefits: Better biomechanical results, lower risk of neurovascular injuries and eliminates the risk of graft bending (killer turn), one of the main causes of failure related to the Transtibial technique [14 -17, 23].

The advantages cited in the literature in relation to the arthroscopic transtibial technique include: low morbidity; good reproducibility; does not require capsulotomy; easy patient positioning and good clinical results [12,13].

In view of these observations, and based on the vast evidence that demonstrates PCL/PLC injuries with high frequency, we found that there are few studies involving the treatment of these combined injuries. In patients with low demand, performing an open reconstruction through the lateral access to the PLC structures, associating it with a PCL reconstruction technique that uses the transtibial route for graft fixation, seems to be the most viable option among what we currently have in the market. literature.

On the other hand, with the evident biomechanical advantages and lower rates of failures in the access routes for INLAY reconstructions, in the face of young and high-demand patients, such as athletes, the performance of a combined PLC reconstruction and PCL fixation in the tibial bed by the classical technique would involve making a double access, lateral and posteromedial, respectively. In addition to the fact that we are facing a surgery that is technically difficult to be performed in a single time, the increase in its morbidity ends up making its execution unfeasible.

In this sense, we believe that the approach proposed in this study has several advantages over conventional repairs in the presence of combined injuries. With it, we highlight the possibility of performing a combined reconstruction in a single time, using the lateral approach, widely known by orthopedic surgeons in PLC reconstruction, and extending it later, in order to allow PCL reconstruction, eliminating the need for a posteromedial access, as described in the classic INLAY tibial technique [23].

We also emphasize the possibility of performing all the surgical steps, from graft collection, to the videoarthroscopic and open steps, using a single positioning in dorsal decubitus, which provides better convenience for the anesthetic team, in addition to eliminating the risk of complications contralateral limb that the lateral decubitus used in the classic technique can cause [12].

The most serious complication of all the techniques is damage to neurovascular structures, due to the proximity of the native insertion of the PCL to the popliteal fossa. In the vast majority of the population these structures are located posterolaterally, for this reason lateral reconstructions have never been described [28,29].

The recognition of the anterior topography of the popliteus muscle in relation to the vasculonervous bundle allowed the repair of its tendon and the muscular detachment of the tibial wall, expanding the viewing area to the posterior region, in addition to providing the creation of an additional protection barrier, through its retraction, as demonstrated in later dissections.

We believe that the extension of the access route proved to be safe and reproducible, creating an area of direct visualization of the quadrilateral zone and allowing fixation in the tibial bed (INLAY) of the graft, preserving the integrity of the posterior capsule, which corroborates our hypothesis.

## Conclusion

The approach described showed good reproducibility for reconstructions in combined lesions, allowing the performance of all stages of these procedures using a single access, in addition to combining all the advantages of a classic INLAY technique, obtaining an adequate area for positioning the tunnel tibial.

Access also establishes safety guidelines, minimizing the risk of iatrogenic injury to the neurovascular structures of the popliteal fossa.

## References

1. Fanelli GC, Giannotti BF, Edson CJ (1994) The posterior cruciate ligament arthroscopic evaluation and treatment. *Arthroscopy* 10: 673-688.
2. Hughston JC, Andrews JR, Cross MJ, Moschi A (1976) Classification of knee ligament instabilities. Part I. The medial compartment and cruciate ligaments. *J Bone Joint Surg Am* 58:159-172.
3. Fanelli GC, Larson RV (2002) Practical management of posterolateral instability of the knee. *Arthroscopy* 18: 1-8.
4. Girgis FG, Marshall JL, Monajem A (1975) The cruciate ligaments of the knee joint. Anatomical, functional and experimental analysis. *Clin Orthop Relat Res* 106: 216-231.
5. Van Dommelen BA, Fowler PJ (1989) Anatomy of the posterior cruciate ligament. A review. *Am J Sports Med* 17: 24-29.
6. Domnick C, Frosch KH, Raschke MJ, Vogel N, Schulze M, et al. (2017) Kinematics of Different Components of the Posterolateral Corner of the Knee in the Lateral Collateral Ligament-intact State: A Human Cadaveric Study. *Arthroscopy* 33: 1821-1830.e1.
7. Dickens JF, Kilcoyne K, Kluk M, Rue JP (2011) The posterolateral corner: surgical approach and technique overview. *J Knee Surg* 24: 151-158.
8. Fanelli GC, Monahan TJ (2001) Complications in posterior cruciate ligament and posterolateral corner surgery. *Oper Tech in Sports Med* 9: 96-99.
9. Petrillo S, Volpi P, Papalia R, Maffulli N, Denaro V (2017) Management of combined injuries of the posterior cruciate ligament and posterolateral corner of the knee: a systematic review. *Br Med Bull* 123: 47-57.
10. LaPrade RF, Terry GC (1997) Injuries to the posterolateral aspect of the knee. Association of anatomical injury patterns with clinical instability. *Am J Sports Med* 25: 433-438.
11. McAllister DR, Hussain SM (2010) Tibial inlay posterior cruciate reconstruction: surgical technique and results. *Sports Med Arthrosc* 18: 249-253.
12. Seon JK, Song EK (2006) Reconstruction of isolated posterior cruciate ligament injuries: A clinical comparison of the transtibial and tibial inlay techniques. *Arthroscopy* 22: 27-32.
13. Sekiya JK, West RV, Ong BC, Irrgang JJ, Fu FH, et al. (2005) Clinical outcomes after isolated arthroscopic single-bundle posterior cruciate ligament reconstruction. *Arthroscopy* 21: 1042-1050.
14. Bergfeld JA, McAllister DR, Parker RD, Valdevit ADC, Kambic HE (2001) A biomechanical comparison of posterior cruciate ligament techniques. *Am J Sports Med* 29: 129-136.
15. Markolf KL, Zemenovic JR, McAllister DR (2002) Cyclic loading of posterior cruciate ligament replacements with tibial tunnel and tibial inlay methods. *J Bone Joint Surg Am* 84: 518-524.
16. Miller MD, Kline AJ, Gonzales J, Beach WR (2002) Vascular risk associated with a posterior approach for posterior cruciate ligament reconstruction using the tibial inlay technique. *J Knee Surg* 15: 137-140.
17. Ahn JH, Yang HS, Jeong WK, Koh KH (2006) Arthroscopic transtibial posterior cruciate ligament reconstruction with preservation of posterior cruciate ligament fibers. *Am J Sports Med* 34: 194-204.
18. Stannard JP, Brown SL, Farris RC, McGwin G, Volgas DA (2005) The posterolateral corner of the knee: repair versus reconstruction. *Am J Sports Med* 33: 881-888.
19. LaPrade RF, Johansen S, Wentorf FA, Engebretsen L, Esterberg JL, et al. (2004) An analysis of an anatomical posterolateral knee reconstruction: an in vitro biomechanical study and development of a surgical technique. *Am J Sports Med* 32: 1405-1414.
20. Faucett SC, Gannon J, Chahla J, Ferrari MB, LaPrade RF (2017) Posterior Surgical Approach to the Knee. *Arthrosc Tech* 6: e391-e395.
21. Alentorn-Geli E, Stuart JJ, Choi JH, Toth AP, Moorman CT, et al. (2015) Inside-out Antegrade Tibial tunnel drilling through the posterolateral portal using a flexible reamer in posterior cruciate ligament reconstruction. *Arthrosc Tech* 4: e537-e544.
22. Matava MJ, Sethi NS, Totty WG (2000) Proximity of the posterior cruciate ligament insertion to the popliteal artery as a function of the knee flexion angle: implications for posterior cruciate ligament reconstruction. *Arthroscopy* 16: 796-804.
23. Berg EE (1995) Posterior cruciate tibial ligament inlay reconstruction. *Arthroscopy* 11: 69-76.

24. Wong T, Wang CJ, Weng LH, Hsu SL, Chou WY, et al. (2009) Functional outcomes of arthroscopic posterior cruciate ligament reconstruction: comparison of anteromedial and anterolateral trans-tibia approach. *Arch Orthop Trauma Surg* 129: 315-321.
25. Lu D, Xiao M, Lian Y, Zhou Y, Liu X (2014) Comparison of the operation of arthroscopic tibial inlay and traditional tibial inlay for posterior cruciate ligament reconstruction. *Int J Clin Exp Med* 7: 3193-3201.
26. May JH, Gillette BP, Morgan JA, Krych AJ, Stuart MJ, et al. (2010) Transtibial versus posterior inlay cruciate ligament reconstruction: an evidence-based systematic review. *J Knee Surg* 23: 73-79.
27. Panchal HB, Sekiya JK (2011) Open tibial inlay versus arthroscopic transtibial posterior cruciate ligament reconstructions. *Arthroscopy* 27: 1289-1295.
28. Cosgarea AJ, Kramer DE, Bahk MS, Totty WG, Matava MJ (2006) Proximity of the popliteal artery to the PCL during simulated knee arthroscopy: implications for establishing the posterior trans-septal portal. *J Knee Surg* 19: 181-185.
29. Ahn JH, Wang JH, Lee SH, Yoo JC, Jeon WJ (2007) Increasing the distance between the posterior cruciate ligament and the popliteal neurovascular bundle by a limited posterior capsular release during arthroscopic transtibial posterior cruciate ligament reconstruction: a cadaveric angiographic study. *Am J Sports Med* 35: 787-792.