



Case Report

Ultrasound Guided Pecs II and Serratus Anterior Blocks as a Sole Anesthetic Technique for Reduction Mastopexy under Light Sedation in Elderly Female with Multiple Comorbidities

E. Boree*, S. Kazaz

Department of Anesthesia in affiliation with Department of Plastic Surgery, Novomed Surgical Hospital, Dubai, United Arab Emirates

*Corresponding author: Eman Boree, Department of Anesthesia, Novomed Surgical Hospital, Dubai, United Arab Emirates.

Citation: Boree E, Kazaz S (2022) Ultrasound Guided Pecs II and Serratus Anterior Blocks as a Sole Anesthetic Technique for Reduction Mastopexy under Light Sedation in Elderly Female with Multiple Comorbidities. J Surg 7: 1590. DOI: 10.29011/2575-9760.001590

Received Date: 04 October, 2022; **Accepted Date:** 07 October, 2022; **Published Date:** 11 October, 2022

Summary

The pectoral nerves (pecs 2) block is widely used as adjunct to general anaesthesia for breast surgery as postoperative pain management. There are a few case reports and a single case series that describe regional anaesthesia as a single technique or supplemented by light to moderate sedation. Regional anaesthesia has very few cardiovascular or pulmonary side-effects, as compared with general anaesthesia and Pectoral nerve block is a relatively new technique, with fewer complications than other regional anaesthesia. Here we describe the management of a 78-year-old lady ASA 3 who presented with a bilateral breasts hyperplasia that is causing her sever back & neck pain, discomfort & recurrent skin infections of the inframammary area. She is type 2 DM, hypertensive and considered unfit for general anaesthesia due to significant ischemic heart disease. A bilateral breast reduction mastopexy was successfully performed under bilateral pecs 2 block and serratus anterior block using a combination of Ropivacaine 0.2% and Levobupivacaine 0.5% with dexamethasone& Clonidine as additives, supplemented with light sedation with TCI Propofol. We consider this technique to be a good option for selected patients who are considered unfit for general anaesthesia.

Introduction

The growing increase in the number of therapeutic and cosmetic breast surgeries has resulted in an increased need for anesthetic techniques with improved pain reduction, safety and fewer complications 60% of breast surgeries are complicated by a high incidence of moderate to severe postoperative pain from injured muscles and nerves which is a consistent risk factor for chronic pain that develop in 25%-60% of cases [1]. As acute postoperative pain control is required for better outcome and patients satisfaction, regional anaesthesia is considered as the best choice to reduce acute postoperative pain and incidence of chronic pain after breast surgery [2].

Breast surgery is usually performed under general anaesthesia or, more recently, combined with conventional regional techniques, such as thoracic epidural block, Thoracic Paravertebral Block (TPVB), and intercostal nerve block, have been used in anaesthesia and/or analgesia in breast surgery. However, these invasive regional techniques lead to some complications during the perioperative period; therefore, they are not appropriate on a day-stay basis as they need longer period of recovery and hospital stay. General Anaesthesia (GA) is frequently associated with postoperative vomiting and nausea, which may occur in up to 50% of cases. Regional or local anaesthesia is an alternative to GA and results in fewer postoperative complications, a shorter hospital stay, and better perioperative pain control [3] Pectoral Nerves

(PECs) block and serratus anterior plane block (SAP) appears as an analgesic less invasive alternative in breast procedures with less intraoperative, respiratory, and postoperative complications than GA during and after ambulatory breast surgery, but few studies refer to it as a single anesthetic technique [4].

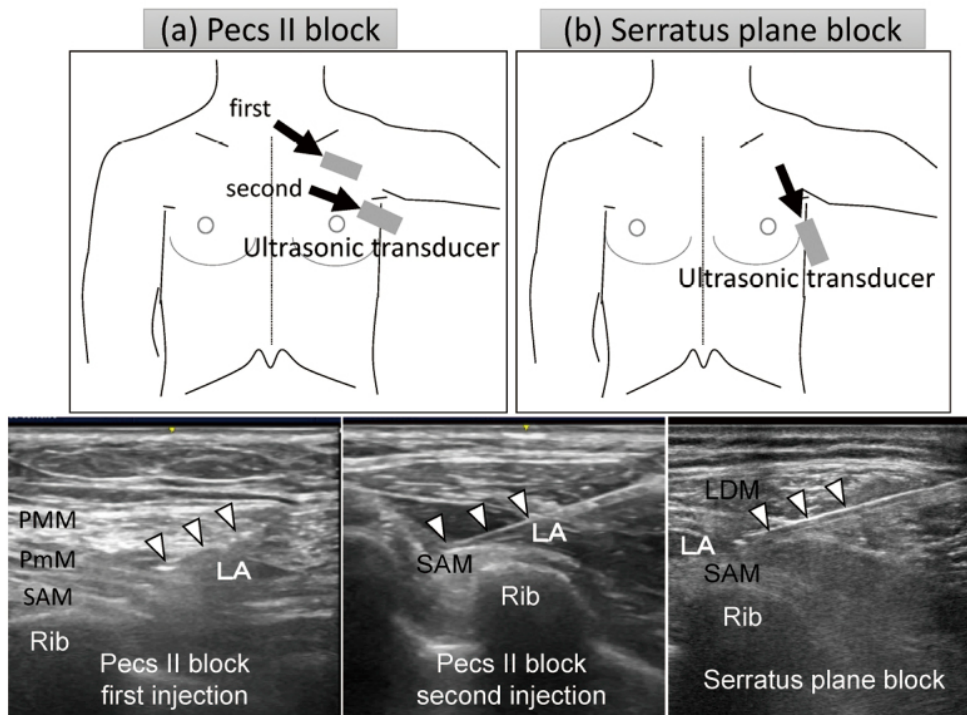
In this case, we introduced a novel technique of Pecs and SAP bilateral blocks in a patient who underwent bilateral breast reduction mastopexy, with better outcomes in terms of reducing postoperative pain and avoiding complications related to GA.

Case Presentation

A 75-year-old female (height 160 cm, weight 102 kg and American Society of Anesthesiologists ASA was III) presented with massive breasts that is causing chronic neck & back pain. She had type II diabetes mellitus, hypertension, coronary artery disease. As she was considered high risk for general anesthesia, ultrasound guided PECs and SAP block with MAC were prepared.

Case Report

Supplemental oxygen was administered by nasal cannula at flow rate 4 l/min following a premedication of 1 mg of intravenous midazolam was given, subsequently for sedation, dexmedetomidine intravenous infusion of 0.2 µg/kg/hour plus propofol target controlled infusion (Schnider's model) with the initial target plasma concentration set at 1.5 µg/ml. Hemodynamics, sedation scores, VAS, BIS, patient's and surgeon's satisfaction, recovery pattern, and side effects were monitored. When a score of 60% BIS was reached, the chest wall and axillary region were cleaned using potadine. A high frequency (4-12 MHz) linear probe (Mindray ultrasound machine) was covered with a sterile camera cover and Initially, the PECs II block was performed bilaterally using a 5 mm 22G regional block (UniPlex, PAJUNK, Germany) needle, which was inserted using the in-plane technique. A total of 15 ml of a local anesthetic agent (equal mixture of ropivacaine 0.2% and levobupivacaine 0.5%) was injected. Then the ultrasound guided SAP block was performed in-plane bilaterally with the same needle and same local anesthetic concentration and volume (Figure 1).



The whole procedure took approximately 15 minutes. Twenty minutes after performing the block, a cold test was used to evaluate the effectiveness of the sensory block. Surgery proceeded after a further 10 minutes. She was draped in the standard sterile manner. We confirmed the anesthetic area over T2-T6 of dermatomes by a pinprick test.

The incision was extended from the border of the pectoralis major muscle to the border of the latissimus dorsi muscle along the naturally occurring skin lines. Dissection along the anterior serratus muscle was carefully conducted, taking care to preserve the integrity of the long thoracic nerve. The neuromuscular bundle, comprising the subscapular vessels, the thoracodorsal vessels and nerves, was identified and dissected from the axillary contents, while being preserved intact, adjacent to the latissimus dorsi muscle. Closed suction drain was inserted at the axillary site and the operation was completed. The total operating time was approximately 3 hours 30 minutes. In the Post Anesthesia Care Unit (PACU), vital signs were stable, and Visual Analogue Scale (VAS) score for pain was 1. Also, Postoperative Nausea and Vomiting (PONV) were absent. The analgesic effect lasted about 12 hours; and analgesics were not required for 1 day then the patient was discharged home on the next day.

Outcome and Follow-Up

Patient was followed up for 24 hours post-operative and 2 months later, All patient's data was acquired via the anesthesia charts, medical records, and questionnaire. During the postoperative period, the vital signs were stable; there was no Postoperative Nausea and Vomiting (PONV) with no additional need for analgesics. The visual analogue score (VAS) was 1-2. Analgesia was required for the first time 24 hours postoperatively, 1gm of paracetamol had a satisfactory pain relief. She was discharged with 1gm paracetamol tablets 6 hourly as needed after one night postoperative hospital admission without complications. Then 2 months later, patient was contacted and confirmed to be pain free without any pain medications and satisfied with the surgical experience

Discussion

The thoracic paravertebral block is still recognized as the gold standard analgesic procedure for breast surgery as it is an accurate, simple and safe method that has more significant advantages over intercostal or epidural block, including less incidence of pneumothorax, total spinal anesthesia and inadvertent intravascular injection. However, it is still an invasive technique and some complications are reported such as inadvertent vascular puncture (6.8%), hypotension (4%), epidural or intrathecal spread (1%), pleural puncture (0.8%), and pneumothorax (0.5%) [5]. Therefore, this technique may not be suitable for many breast surgeries under day care surgery. Pectoral nerve blocks were first described by R Blanco 2011 as a technique, that can be comparable to thoracic paravertebral and thoracic epidural blocks, in providing analgesia with decreasing opiate dosage and avoiding side effects of thoracic paravertebral & thoracic epidural for patients undergoing breast surgery [6]. PECs II block anesthetizes the thoracodorsal and long

thoracic nerve, as well as the lateral branches of the intercostal nerves from T2-T6 [7]. In addition to the region under the pectoralis minor muscle, PECs II also provides analgesia to mammary glands and the skin from the T2-T6 dermatomes extending into the mid-axillary line by blocking the lateral intercostal nerves [8]. Equally, Serratus anterior plane SAP block was published by Blanco 2013 to cover the lateral cutaneous branches of the thoracic intercostal nerves (T2-T12) that provide analgesia to the anterolateral chest wall [9,10]

Pecs and SAP blocks has many advantages over other regional techniques, including no risk of sympathectomy that is usually associated with TPVB and epidural blockade. Additionally, it has less restrictions on the use of anticoagulants, as compared to TPVB or neuraxial blocks. TPVB is unable to block medial and lateral pectoral nerves as well as long thoracic and thoracodorsal nerves. Therefore, in performing breast surgeries involving axillary dissection, there is potential for lack of adequate analgesia. A recent study showed reduced postoperative morphine consumption in the first 24 hours and lower pain scores in the first 12 hours in the Pecs block group, as compared to TPVB group for postoperative analgesia in modified radical mastectomy [11].

Combining Pecs/SAP blocks as the primary anesthesia with MAC, showed better anesthesia coverage, patient satisfaction, reduced PONV, and avoidance of GA-associated complications. In breast surgeries under GA, patients showed 48%-72% incidence of PONV with inhalational anesthetics; and utilization of total intravenous anesthesia caused a further decrease to only 43.8% [12]. Only few cases of Pecs blocks have been reported as the primary anesthesia for breast surgery. Fujiwara et al. [13] reported successful placement of an implantable cardiac resynchronization device under Pecs I block (10 mL, 0.375% ropivacaine) combined with first and second intercostal nerve blocks (4 ml, 0.375% ropivacaine) and light intravenous sedation in a high risk patient who was intolerable to GA and neuraxial blockade. Moon et al, reported on a successful breast surgery performed under PECs I and II blocks when a patient refused GA. Hong et al. [14], reported on a pregnant women who refused GA for breast surgery. Campos et al. [15] reported that a patient with several comorbidities and a high surgical risk, underwent a PECs II block as the exclusive anesthetic technique

MAC with dexmedetomidine was beneficial to the patient and surgeon, due to its analgesic, sedative, anxiolytic and sympatholytic properties. Interestingly, intravenous dexmedetomidine may prolong the duration of sensory block on spinal and peripheral nerve blocks [9]. Hence, intravenous dexmedetomidine with regional anesthesia is expected to have a supporting role. Thus, the combination of Pecs/ SAP blocks with MAC is helpful in patients undergoing simple breast surgeries.

Conclusion

In conclusion, the use of a PECs block as the sole anesthetic in patients with multiple comorbidities is a simple technique with no contraindications and may provide better analgesia, lesser side effects, reduced hemodynamic instability, and would be a safer alternative to GA in breast surgeries and has a major role in shortening hospital stay and improving bed rotation rate.

References

1. Alessandro De Cassai , Claudio Bonanno, Ludovica Sandei, Francesco Finozzi, Michele Carron (2019) PECS II block is associated with lower incidence of chronic pain after breast surgery, *Korean J Pain* 32: 286-291.
2. Gartner R, Jensen MB, Nielsen J, Ewertz M, Kroman N, et al. (2009) Prevalence of and factors associated with persistent pain following breast cancer surgery. *JAMA* 302: 1985-1992.
3. Cali CL, Biffoli F, Francesconi D, Petrella G, Buonomo O (2017) Anesthesia and analgesia in breast surgery: the benefits of peripheral nerve block. *Eur Rev Med Pharmacol Sci* 21: 1341-1345.
4. Saied NN, Helwani MA, Weavind LM, Shi Y, Shotwell MS, et al. (2017) Effect of anaesthesia type on postoperative mortality and morbidities: a matched analysis of the NSQIP database. *Br J Anaesth* 118: 105-111.
5. Batra RK, Krishnan K, Agarwal A (2011) Paravertebral block. *J Anaesthesiol Clin Pharmacol* 27: 5-11.
6. R Blanco (2011) The 'pecs block': a novel technique for providing analgesia after breast surgery, *R Blanco, Anaesthesia* 66: 847-848.
7. Versyck B, Van Houwe P, Van Geffen GJ, Van de Velde M, Slappendel R (2017) A qualitative systematic review of the pectoral nerves block type I and II. *Acta Anaesth Belg* 68: 49-62.
8. Moon EJ, Kim SB, Chung JY, Song JY, Yi JW (2017) Pectoral nerve block (Pecs block) with sedation for breast conserving surgery without general anesthesia. *Ann Surg Treat Res* 9: 166-169.
9. Davies F, Gladstone RJ, Stibbe EP (1932) The anatomy of the intercostal nerves. *Journal of Anatomy* 66: 323-323.
10. R. Blanco, T. Parras, J. G. McDonnell, A. Prats-Galino (2013) Serratus plane block: a novel ultrasound-guided thoracic wall nerve block 2013.
11. Kairaluoma PM, Bachmann MS, Rosenberg PH, Pere PJ (2006) Preincisional paravertebral block reduces the prevalence of chronic pain after breast surgery. *Anesth Analg* 103: 703-708.
12. Manahan MA, Basdag B, Kalmar CL, Shridharani SM, Magarakis M, et al. (2014) Risk of severe and refractory postoperative nausea and vomiting in patients undergoing diep flap breast reconstruction. *Microsurgery* 34: 112-121.
13. Fujiwara A, Komazawa N, Minami T (2014) Pectoral nerves (PECS) and intercostal nerve block for cardiac resynchronization therapy device implantation. *Springerplus* 3: 409.
14. Hong B, Yoon SH, Youn AM, Kim BJ, Song S, et al. (2017) Thoracic interfascial nerve block for breast surgery in a pregnant woman: a case report. *Korean J Anesthesiol* 70: 209-212.
15. Campos M, Azevedo J, Mendes L, Rebelo H (2018) Pectoral nerve block as a single anesthetic technique for breast surgery and sentinel lymph node investigation. *Rev Esp Anesthesiol Reanim* 65: 534-536.