



Case Report

Utero-Cutaneous Fistula: A Case Report

Paraskevas Anagnostopoulos^{1*}, Maria Papastamatiou¹, Konstantina Kalligianni-Sofikiti¹, Elisavet Anagnostopoulou², Antonis Makrigrigianakis¹, Thomas Vrekoussis¹

¹Obstetrics & Gynecology Department, University General Hospital of Heraklion, Medical School of the University of Crete, Greece

² Department of Surgical Oncology, Medical School of Crete University Hospital, Heraklion, Greece

***Corresponding author:** Paraskevas Anagnostopoulos, Obstetrics & Gynecology Department, University General Hospital of Heraklion, Medical School of the University of Crete, Greece

Citation: Anagnostopoulos P, Papastamatiou M, Kalligiani-Sofikiti K, Anagnostopoulou E, Makrigrigianakis A, et al (2024) Utero-Cutaneous Fistula: A Case Report. Ann Case Report. 9: 1818. DOI:10.29011/2574-7754.101818

Received: 18 May 2024, **Accepted:** 22 May 2024, **Published:** 24 May 2024

Abstract

Utero-cutaneous fistula is an extremely rare condition characterized by an abnormal communication between the anterior wall of the uterus and the abdominal wall. The causes include multiple caesarean sections, miscarriages, uterine cavity revision, and retention of placental material after delivery, use of drains, post-operative infections, or injuries. Herein, we report a case of a 39-year-old female, who underwent caesarean section 8 months earlier and presented to the emergency room complaining of abdominal pain, and purulent discharge from the abdominal wall. Magnetic resonance imaging demonstrated the presence of a probable hyper intense fistula, extended from the subcutaneous area and in connection with the uterus. A laparotomic surgical procedure was successfully performed.

Keywords: Utero-cutaneous fistula; Caesarean section Imaging.

Introduction

Utero-cutaneous fistula is an extremely rare condition, and its pathophysiology is not fully understood. It mostly occurs consecutively to surgical intervention such as Caesarean section. Bloody discharge from the cutaneous fistulous opening during the menstrual bleeding is almost pathognomonic.

We report the case of a 39-year-old woman, with personal history of Hashimoto's thyroiditis. The diagnosis of the utero-cutaneous fistula was confirmed by imaging. The surgical management was successful and consisted of the total excision of the fistulous tract together with hysterectomy.

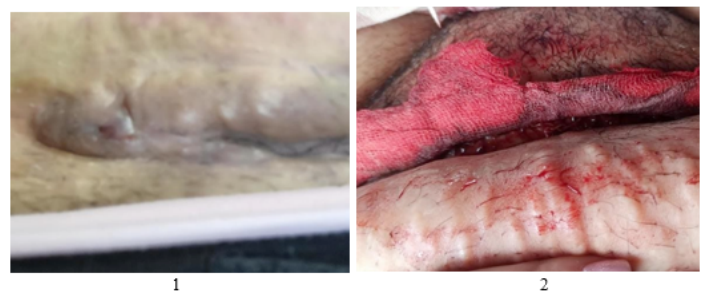


Figure 1,2: Clinical images of the caesarean section scar with skin retraction and fistulous opening at it right.

Case Presentation

A 39-year-old woman presented due to pain and cyclic bloody discharge for 4 months from her third Cesarean section that was performed 8 months ago.

Examination of the abdominal wall revealed a cutaneous retraction and a fistulous opening at the right end of the scar, without a palpable nodule (Figure 1,2).

A pelvic transabdominal ultrasound was performed, showing a fistulous tract extending from the anterior body of the uterus, that shows a focal myometrial thinning related to the caesarean section scar, to the right end of the cutaneous scar (Figure 3). A pelvic MRI was performed with injection of diluted iodinated contrast medium through the cutaneous fistulous opening, showing the opacification of the fistulous tract described on ultrasound, as well as the uterine cavity, confirming the surgical management was successful. It consisted of complete excision of the tract with removal of the previous sutures and the necrotic tissue. Hysterectomy was performed with both ovaries remaining intact.

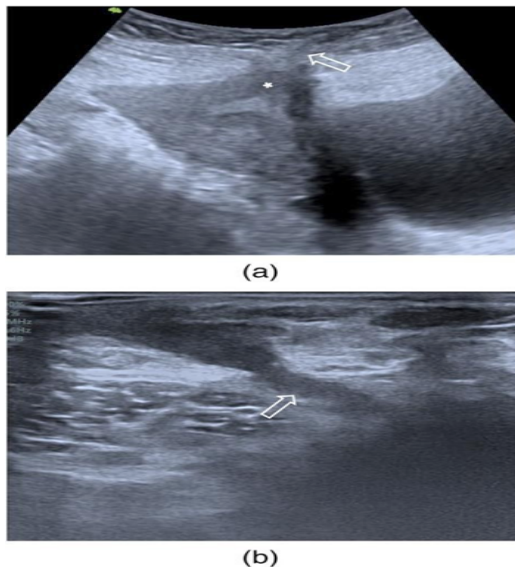


Figure 3: Transabdominal ultrasound in the sagittal plane (a) axial plane (b) showing a fistulous tract extending from the anterior body of the uterus.

Discussion

Utero-cutaneous fistula is an extremely rare condition, with few cases being reported in the literature (less than 20 case reports during last decade). It is an abnormal communication between the cutaneous surface and the uterine cavity. The main manifestation is bloody discharge from the cutaneous fistulous opening during the menstrual period, which is almost pathognomonic. The pathophysiology is not well understood. Several possible causes

may predispose to this condition. Most of the reported cases were consecutive to Cesarean sections. Other predisposing factors are multiple surgeries in the abdomen, incomplete closure of incisions, septic abortion, pelvic abscess, incomplete placenta removal, uterovaginal malformation, use of forceps. Multiple imaging techniques confirming the diagnosis had been reported. Fistulography with the injection of the contrast material through the cutaneous fistulous opening confirms the connection to the uterus. CT scan with intravenous injection of contrast medium and MRI can also identify the fistula. Hysteroscopy allows direct visualization of the internal fistulous opening. The primary treatment of utero-cutaneous fistula is surgical excision of the fistulous tract without or with a subtotal or total hysterectomy. For conservative treatment, gonadotropin-releasing hormone agonists would induce amenorrhoea secondary to endometrial atrophy, resulting in contracture and healing of the fistulous tract. It can be used either on its own for a fistulous tract of small size or in combination with surgical treatment for better results [1-4] (Figure 4).

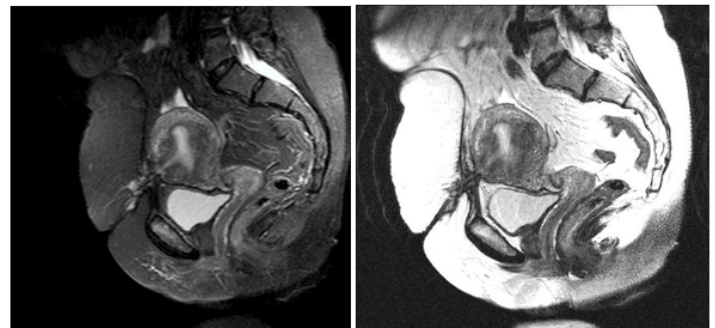


Figure 4: Pelvic MRI scan showing the communication between anterior abdominal wall and the uterine cavity.

In our case, the diagnosis was confirmed by MRI scan with an injection of contrast medium through the cutaneous fistulous opening.

References

1. Jadib A, Tabakh H, Chahidi El Ouazzani L, Kardi O, Siwane A, et al (2021) Utero-cutaneous fistula following cesarean section: A case report. *Radiol Case Rep.* 17:77-79.
2. Maddah G, Fattahi AS, Rahnama A, Jamshidi ST. (2016) Uterocutaneous Fistula Following Cesarean Section: Successful Management of a Case. *Iran J Med Sci.* 41:157-60.
3. Hasan JN, Musa DH, Mohammed AA. (2021) Uterocutaneous fistula after cesarean section; Case report. *Int J Surg Case Rep.* 89:106621.
4. Cicinelli R, Cicinelli E, Crupano F, Vinciguerra M, Lamanna B, et al (2022) "A rare but troublesome complication of cesarean section: the uterocutaneous fistula. Report of two cases and review of literature" *Case Reports in Perinatal Medicine*, 11:20210057.